Case Report

MUSCULAR HYDATIDOSIS: A report of 3 cases

Sarmast Shoushtari MH[1], Talaizadeh AH[2], Fazeli T[3], Rafiei A[4], Maraghi S[5] & Jelowdar M[6]

ABSTRACT

Hydatidosis or cystic echinococcosis is an important zoonotic parasitic disease caused by a small taenid-tape worm (*Echinococcus granulosus*)with worldwide distribution, particularly in developing countries where many rural inhabitants live under poor sanitary conditions. The majority of hydatid cysts are located in liver and lungs and muscular hydatid cysts are rare. This is a report of three muscular hydatid cysts from Ahvaz, southwestern part of Iran. The first patient was a 64-year-old man with liver and left thigh cysts. The muscular cyst was measured 3 × 3 cm in diameter. The second case was a 32 year male with left gluteal muscle mass of firm consistency measured 3 × 3 × 2 cm. The third case was an eighty-year old male with a soft mass tissue and painless in the left thigh measured 5 × 5 × 8 cm. Complete excision of muscle cysts was done and histopathological examination of specimens confirmed the hydatid cyst. Cysts of cases 1 and 2 were fertile with laminated and germinal layers and protoscolices and case 3 was unfertile. In the third case laminated and germinal layers were observed without any protoscolices.

KEY WORDS: Hydatid cyst, Muscle, Ahvaz, Iran

Pak J Med Sci April-June 2005 Vol. 21 No. 2 220-2

1-2. Department of Surgery,
Imam Khomeini Hospital,
Jundi-Shapour University of Medical Sciences,
Ahvaz, Iran

3. Pathology Department,
NIOC, Grand Hospital,
Ahvaz, Iran

4-5. Department of Mycoparasitology,
School of Medicine,
Jundi-Shapour University of Medical Sciences,
Ahvaz, Iran

6. Department of Surgery,
Amirolmoemenin Hospital,
Ahvaz, Iran

Correspondence:

Prof. S. Maraghi
Department of Mycoparasitology, School of Medicine,
Jundi-Shapour University of Medical Sciences, Ahvaz, Iran
E. mail : maraghi_s@yahoo.com

* Received for publication: October 5, 2004

Accepted: November 28, 2004

INTRODUCTION

Hydatidosis is a zoonotic infection caused by *Echinococcus granulosus*. Human Cystic Echinococcosis (CE) is still endemic in some areas of the world including Mediterranean countries and CE is still a healthcare problem in Iran. Man is infected by ingestion ova and cysts are most commonly found in the liver and lungs[1-4]. If the embryos pass liver and lungs filtration, they can reach to every organ in the body via the arterial circulation. Muscular localization of the hydatid cyst is uncommon and very rare and is usually secondary to hepatic or pulmonary disease and can cause a variety of diagnostic problems. The incidence in many reports is between 0.5-5.4% of all cases of CE[5-7]. The reports of muscular hydatid cysts are in the neck[8,9] thoracic[10] erector spinae[11],

psoas[12,13], proximal thigh[14], quadriceps[15], adductor[6] intermedius and vastus medialis[7] and sartorius[16] muscles. In one of our cases, the cyst was in gluteal muscle and in two cases the cysts were in proximal thigh.

PATIENTS

Case 1:

A 64 year old male with right liver lobe hydatid cyst. He was complaining from painless suspected tumor measured 3× 3 cm in his left thigh since three years. Serological test with ELISA technique for IgG antibody against hydatid cyst was positive. Sonography reported unilocular echofree cyst. Abdominal operation for hepatic cyst and complete excision of muscle cyst were done at the same time after 3 weeks albendazol therapy, which followed for 3 months after operation.

Case 2:

A 32-year male with asymptomatic left gluteal muscle tumor which evaluated with sonography and correct diagnosis was done at operation.

Case 3:

An eighty year old male with painless soft tissue mass in the medial aspect of left thigh measured 5× 5 ×8 cm. Ultrasonography and CT Scan revealed cystic structure with multiple septation. ELISA test for hydatid cyst IgG antibody was positive. At operation complete excision was done. In all cases correct diagnosis was done for echinococcosis by histopathological examination (Fig. 1,2).

DISCUSSION

Although clinically muscle cyst mimics a soft tissue tumor which is asymptomatic and slow growing, but the patients can present with painful and erythematous mass[5]. Pre-operative imaging diagnosis can be made by ultrasonography, CT Scan, and MRI that may show a typical hydatid cyst[6,15,16], although the correct diagnosis may not be possible by these images[9], especially in the absence of typical radiologic finding[15]. In this report all patients presented with longstanding asymptomatic and painless subcutaneous mass and were evaluated with ultrasongraphy which reported echofree cyst. In such cases with suspicion of hydatid cyst clinically or radiologically, preoperative manipulation (puncture or incision) of mass should not be avoided, since they may be followed by an infection of the cystic cavity with fistulization. Complete surgical excision is treatment of choice[5,6] which cures the patients. Difficulties could arise from the operative management, during the radical procedures, to preserve some anatomic important structures[1]. In our patients histopathological examinations of

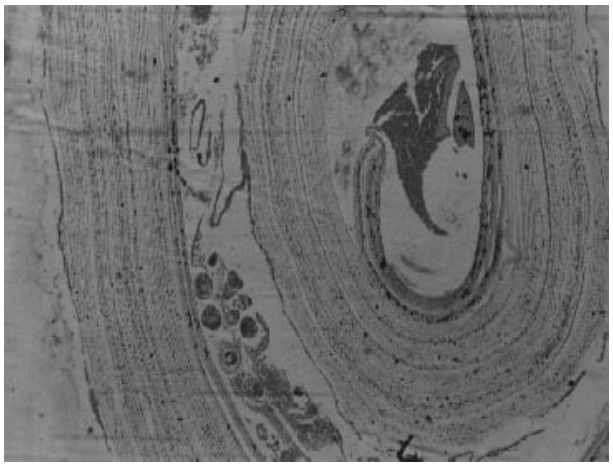

Fig 1 : Cross section of muscular hydatid cyst (Note the hyaline layer and germinal layer. Scolices are seen) H & E staining (20õ)

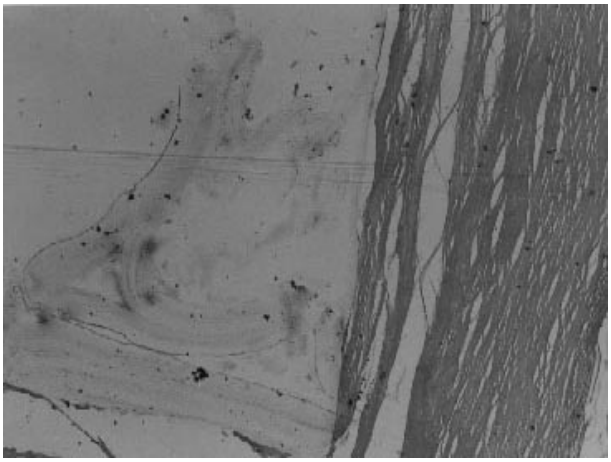

Fig 2 : Cross section of muscular hydatid cyst (Note the hyaline layer and germinal layer. No scolices are seen) H & E staining (20õ)

specimen confirmed correct diagnosis. All patients were treated with complete excision and administration of high dose of albendazole for 3 months post operatively although some authors reports recommended albendazol therapy for 4 and 5 months[12] and one year follow up showed no recurrence. We recommend that hydatid cyst should be considered as differential diagnosis for all cystic muscular mass, in endemic area particularly if it is of longstanding duration. Serological evaluation could be useful in all suspected hydatid cases and evaluation in all patients with muscular echinococosis for liver and lungs hydatid cysts is necessary.

ACKNOWLEDGEMENT

We would like to thank Mr. A. Jelowdar for his critical help and the staff of Surgical Department at Imam Khomeini and Amirolmoemenin Hospitals, Ahvaz, Iran.

REFERENCES

1. Saidi F. Surgery of hydatid disease. WB Saunders 1976; 31-32.
2. Schwartz S, Shires G, Spencer F, Daly J, Fisher J, Galloway A. Principle of Surgery. McGraw Hill, 7th edition 1999; 1403.
3. Mehrabani D, Oryan A, Sadjadi SM. Prevalence of *Echinococcus granulosus* infection in dogs and herbivores in Shiraz, Iran. Vet Parasitol 1999; 86(3): 217-20.
4. Lupascu C, Prescornita L, Cucu G, Lupascu C. Rare sites of hydatic cyst. Rev Med Chir Soc Med Nat Iasi. 2002;106(4):841-4.
5. Garcia – Alvarez F, Torcal J, Salinas JC, Navarro A, Garcia-Alvarez I, Navarro-Zorraquino M, et al. Musculoskeletal hydatid disease: a report of 13 cases. Acta Orthop Scand 2002; 73(2):227-31.
6. Meddeb N, Bachrouch N, Elleuch M, Sahli H, Cheour E, Labib S, et al. [Hydatid cyst of the adductor musles. MRI aspect, Apropos of 1 case] [Article in French] Bull Soc Pathol Exot 2001;94(2);106-8.
7. Alexiadis G, Lambropoulou M, Deftereos S, Papadopoulos N, Manavis J. Primary muscular hydatidosis. US,CT and MR findings. Acta Radiol 2002; 43(4):428-30.
8. Nath K, Prabhakar G, Nagar RC. Primary hydatid cyst of neck muscles. Indian J Pediatr 2002;69(11):99-8.
9. Gluncic I, Roje Z, Bradaric N, petricevic A, pisac VP, Gluncic V. Primary echinococcosis of the sternocledomastoid muscle. Croat Med J 2001; 42(2):196-8.
10. Anton Aranda E. [Thoracic muscle hydatidosis] [Article in Spanish] Enferm Infec Microbiol Clin. 1997; 15(5):278-9.
11. Atalay F, Orug T, Arda K, Tosun O, Atalay F. An unusual case of hydatid disease located in the erector spain muscle. J Belge De Radiologie-Biological Turkish Research (JBR-BTR) 2003;86(6):329-31.
12. Melis M Marongiu L, Scintu F, pisano M, Capra F, Zorcolo L, Casula G. Primary hydatid cysts of psoas muscle. ANZ J Surg 2002; 772(6):443-5.
13. Benchekroun A, Jira H, Cheikhani EH, Zannoud M, Faik M. [Hydatid cyst of the psoas. Report of a case] [Article in French] Ann Urol (Paris) 2001;35(2);108-10
14. Orhan Z, Kara H, Tuzuner T, Sencan L, Alper M: Primary subcutaneous cyst hydatic disease in proximal thigh: an unusual localization:a case report. BMC Musculoskelet Disord 2003;4(1): 25.
15. Ozkoc G, Akpinar S, Hersekli MA, Ozalay M, Tandogan R. Primary hydatid disease of the quadriceps muscle: a rare localization. Arch Orthop Trauma Surg. 2003;123(6):314-6, Epub 2003 May 14.
16. Comert RB, Aydingoz U, Ucaner A, ArikanM. Waterlily sign on MR imaging of primary intramuscular hydatidosis of sartoriusmuscle. Skeletal Radiol 2003;32(7):420-3. Epub 2003 Jun 11.