

## ADENOID CYSTIC CARCINOMA OF THE SUBGLOTTIC

Ashwaq Al-Absi<sup>1</sup>, Muhammad Hazim<sup>2</sup>, Abdullah Sani<sup>3</sup>

### ABSTRACT

Adenoid cystic carcinoma (ACC) is one of the most common malignancies of the minor salivary glands in the head and neck. We report a case of adenoid cystic carcinoma of the subglottic region presenting with hoarseness and decrease effort tolerance. Smooth, solid and lobulated mass arising from the anterior part of the subglottic region was seen on direct laryngoscopy. Computed tomography (CT) scan and histopathological examination were confirmatory. Laser excision followed by radiation resulted in apparently normal subglottic mucosa.

**KEY WORDS:** Adenoid cystic carcinoma, Head and neck Malignancies.

Pak J Med Sci April 2007 Vol. 23 No. 2 270-274

### INTRODUCTION

Malignant salivary gland tumors account for less than 1% of all malignancies. Adenoid cystic carcinoma of the larynx is very rare with less than 75 cases reported in the literature.<sup>1</sup> Adenoid cystic carcinoma represents less than 10% of all salivary gland neoplasms, including benign and malignant lesions,<sup>2</sup> but is about 40% of all malignancies of major and minor salivary glands. It is seen in both the minor and major salivary glands but is more common in the minor salivary glands,<sup>3</sup> and accounts for 22% of minor salivary gland malignancies. It

is the most common malignancy in the submandibular gland and the minor salivary glands. It can be seen in the lacrimal glands, the ceruminous glands of the external auditory canal, the oesophagus and the breast.

In the larynx, these tumors arise almost exclusively in the subglottic and supraglottic regions, having large numbers of seromucinous glands of the minor salivary gland type.<sup>3</sup> These malignant tumors, whether occurring in the larynx or elsewhere, tend to grow quite slowly with prolonged non-specific symptomatology and protracted clinical course. Despite their slow growth, in a majority of cases, they eventually result in the death of the patient. Symptoms of long duration, slow progressive growth with tendency for local recurrence, and eventual development of pulmonary metastasis is common.

### CASE REPORT

A 30-year old Malay lady presented with a persistence hoarseness of eight months duration. It was precipitated by episoid of upper respiratory tract infection. She did not complaint of dyspnea, chronic cough, dysphagia, fever, aspiration symptoms, heartburn, throat clearing, chest pain, and loss of appetite, loss of weight or hemoptysis. She had no history of smoking. There was no family history of pulmonary tuberculosis or malignancy. On

1. Dr. Ashwaq Al-Absi

2. Dr. Muhammad Hazim

3. Prof. Dr. Abdullah Sani

1-3: Department of Otorhinolaryngology,  
Head & Neck Surgery  
Faculty of Medicine  
Universiti Kebangsaan Malaysia Hospital,  
Kuala Lumpur - Malaysia.

#### Correspondence

Dr. Ashwaq Al-Absi,  
Department of Otorhinolaryngology,  
Head & Neck Surgery,  
Faculty of Medicine,  
UKM Hospital,  
Jalan Yaacob Latif,  
56000 Bandar Tun Razak,  
Cheras, Kuala Lumpur,  
Malaysia.  
E-mail: alabsi321@yahoo.com

\* Received for Publication: August 31, 2006

\* Accepted: October 22, 2006

physical examination, she looked well and not in respiratory distress. Her voice was hoarse and breathy. There was no cervical lymphadenopathy. Fiber-optic laryngoscopy revealed a smooth mass in the anterior part of subglottic area. However, both vocal cords look normal and mobile. Her head and neck examination were unremarkable. Her chest examination revealed good air entry bilaterally with no adventitious sounds. Results of abdominal examination were unremarkable.

Computed tomography (CT) scan of neck revealed enhancing lesion at the right subglottic region measuring 1.1cm x 1.3cm. The lesion extends to inferior level of right thyroid cartilage. It was in contact with the cricoid cartilage. There was no evidence of destruction to these laryngeal cartilages (Figure-1, Figure-2). There were multiple tiny subcentimeter level IA and bilateral level II. Chest X-Ray and ultrasonography of the liver revealed no

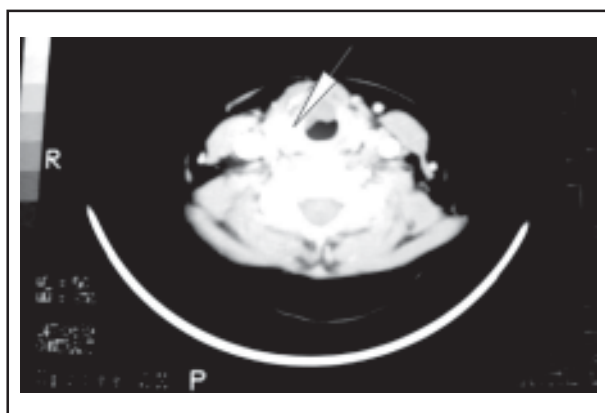
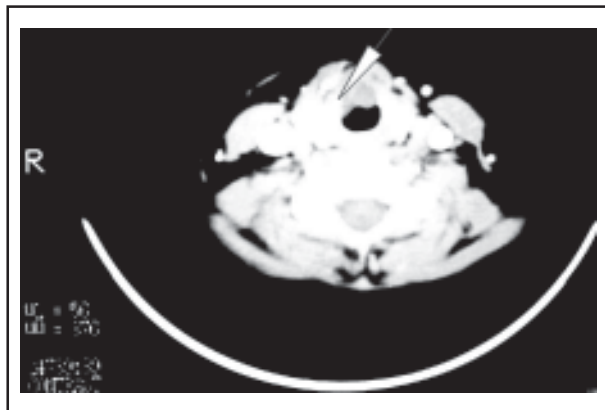


Fig-1 & Fig-2: Computed tomography (CT) scan of thorax revealed enhancing lesion at the right subglottic region measuring 1.1cm x 1.3cm

evidence of distant metastases. Direct laryngoscopic examination revealed a smooth, solid and lobulated tumor arising from the anterior part of the subglottic region, cotton grade II according to cotton classification<sup>4</sup> (Figure-3, Figure-4). Both vocal cords were normal and mobile. Excisional biopsy was performed using CO<sub>2</sub> laser. The final pathological diagnosis was cribriform pattern of adenoid cystic carcinoma. She underwent radiotherapy and completed 66GY (33 fractions) over the period of six weeks. She was under follow up and she was seen at five months post radiotherapy and presently her voice is less hoarse and more powerful. However, there was no evidence of recurrence at primary site on direct laryngoscope.

## DISCUSSION

The laryngeal subglottis as a distinct anatomical region is somewhat ill defined and has been the subject of controversy.<sup>3,4</sup> The inferior border is universally accepted as the plane through the lower border of the cricoid cartilage. The upper border, however, has been the topic of debate. In 1975, Bryce summarized the anatomy of the subglottic larynx. The superior portion of the subglottis is contained by the conus elasticus, which originates from the upper margin of the cricoid and extends to the vocal ligaments of the true vocal cords.<sup>5</sup>

Tumors involving this region are classified as either primary or secondary. Primary malignant lesions of the subglottis are rare, accounting for 1-3.6% of laryngeal cancers. The most common malignant neoplasm arising in the subglottis is epidermoid carcinoma, which comprised 55% of tumors. Adenoid cystic carcinoma (ACC) is the second most common, followed by chondrosarcoma.<sup>3</sup>

Laryngeal localization of adenoid cystic carcinoma is quite rare (0.6% of all malignant laryngeal tumors). Two-thirds of these tumors are subglottic,<sup>3</sup> possibly because the distribution density of subepithelial glands is higher in the subglottic than in the supraglottic and glottic areas. ACC arising from subepithelial glands<sup>6</sup> begin as submucosal lesions, and are

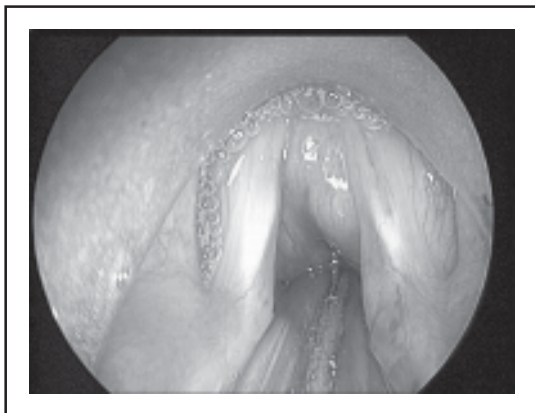


Fig-3: Direct laryngoscopy reveals. A smooth, solid and lobulated tumor arising from the anterior part of the subglottic region with Cotton grade II stenosis

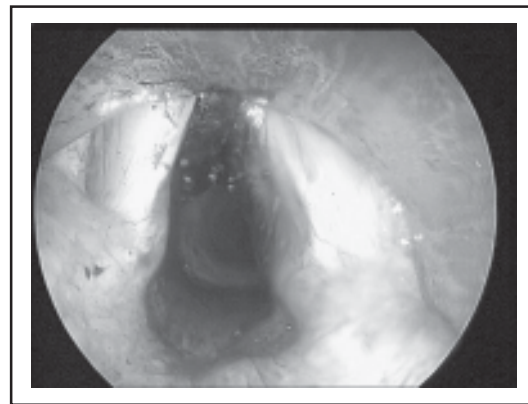


Fig-4: Subglottic mucosa apparently normal post CO2 Laser excision

difficult to detect earlier. This explains why most patients were diagnosed late at the advanced stage.

Adenoid cystic carcinoma occurs most frequently in the fifth decade of life and rarely before the second decade.<sup>7</sup> There is no sex predilection. Subglottic tumors typically present with shortness of breath, dyspnea on exertion, and may be accompanied by hoarseness. Patients may present with a neck mass. In majority of patients symptoms were present for more than six months. On endoscopy, patients typically have a submucosal mass with normal overlying respiratory epithelium. Similarly, our patient presented with persistence hoarseness and decrease effort tolerance. Her laryngeal examination revealed a smooth, solid and lobulated tumor in subglottic area.

ACC has three main histological patterns tubular, cribriform and solid. Pathologic grading system has been revised somewhat to three pathologic grades. This was first done by Szanto et al in 1984.<sup>8</sup> Grade I would be tubular and cribriform only without any solid component. Grade II would be mostly cribriform but less than 30% solid component. Grade III would be predominantly solid. All three types are characterized by fairly uniform-sized cells with small hyperchromatic nuclei, scant cytoplasm, and indistinct cell borders. In the salivary glands, the prognosis of ACC correlates with the predominant histological pattern. Tubular ACC has the best prognosis, whereas solid

ACC has the worst prognosis.<sup>9</sup> However, in our patient the histological type was cribriform pattern grade II with moderate prognosis.

The Clinical staging of the ACC was another critical factor determining outcome. Staging of the tumor in our patient was determined according to TNM classification of the American Joint Committee on Cancer (AJCC). Based on TNM staging, our patient had stage T1 tumor. Spiro et al has identified clinical staging as the most important factor in determining outcome and argued that, because of the mixed cellularity of the tumor, histological typing is a subjective process and consequently cannot be used to determining outcome.<sup>10</sup> Early stage disease did very well with 75% ten-year survival, decreasing to 42% for stage II disease, and 15% ten-year survival for stage III and IV disease.

Another very important factor with adenoid cystic carcinoma is the tendency for perineural invasion. This tumor has a marked tendency to invade nerves. Perineural invasion is seen in about 80% of all specimens. Haddad et al<sup>11</sup> reported that ACC with perineural invasion is associated with reduce survival rate and increased incidence of distant metastasis. ACC also has the propensity for intravascular and perivascular growth, which presumably leads to hematogenous spread.

Distant metastases can develop despite local regional control and can occur more than ten years after the initial therapy. It is more common with solid tumors. Distant metastases

from laryngeal ACC are most commonly seen from the supraglottic and glottic sites than the subglottic region. Van et al<sup>2</sup> concluded that distant metastases of ACC occur most often in the lungs. Although these lung metastases are the first to occur, these patients pass away later than patients with distant metastases in other organs. Chummun et al<sup>7</sup> concluded that the occurrence of distant metastasis did not correlate with tumor site or local recurrence and the distant metastases can develop in up to 50% of patients. Lymph node metastasis is not very common with this disease, and are only seen in about 15% of case. It is more common with solid tumors, and the site and stage are not very often reliable predictors of regional metastasis.<sup>7</sup>

Microscopic positive margins was also an adverse prognostic factor, but even when present, local control was achieved in over 80% of our patients.<sup>12</sup> Chummun et al reported that tumor with positive margins has a significant worse prognosis than those with negative margins.<sup>7</sup> Haddad et al suggested that positive surgical margins might represent resistant and aggressive disease rather than an inadequate surgical resection of the specimen.<sup>11</sup>

Treatment of this tumor is frustrating due to its deceptive biologic behavior, characterized by multiple and late recurrences. However, there is a long survival with recurrent and metastatic disease. Surgical resection is the mainstay of therapy. Obviously, the surgical goals include obtaining disease-free margins, and at the same time preserving maximal physiological function. Even despite radical surgery, there is a frustratingly high recurrence rate. Clearly, surgery alone is not curative in advanced disease. Garden et al<sup>12</sup> concluded that excellent local control rates were obtained using surgery and postoperative radiotherapy. However, Five-year survival statistics do not appear as relevant as 10- and 20-year survival rates in this entity because of the often slow but pernicious nature of adenoid cystic carcinoma of the subglottic area. Despite aggressive therapy, the disease often leads to the eventual death of the patient.<sup>1</sup> In our patient, the

tumor was excised using CO<sub>2</sub> laser and post-operative radiotherapy resulted in apparently normal subglottic area.

Primary radiotherapy for salivary gland tumors is generally offered to unresectable cases or to patients with distant metastases at presentation. ACC is radiosensitive but not radiocurable.<sup>9</sup> These observations have led to the formulation of a combined therapy policy for most ACC. Garden et al concluded that radiation therapy is efficacious in reducing local failures and it was less effective with positive margins or perineural involvement. They also found a significant problem with distant metastases.<sup>12</sup> The curative potential of radiation therapy is most likely related to tumor burden. Radiation is probably most beneficial when there is minimal microscopic disease. Vikram et al looked at patients treated with radiation therapy. 96% of them had tumor regression but 93% relapsed, and the majority of these or half of them relapsed in 18 months.<sup>13</sup> Chris et al. reported that postoperative radiotherapy significantly improved locoregional control and determined survival for patient with Stages III and IV, incomplete or close resection margins or bone invasion and for patients with positive node metastases. Local control was 91% after 10 years.<sup>14</sup> For patients with neither of these unfavorable prognostic factors, surgery alone resulted in a 95% 5-years and 90% 10-year local control. Local control depended on perineural invasion, and improved significantly for patients treated with postoperative radiotherapy (from 60% to 88% after 10 years). However, in another study, perineural invasion was no independent factor for local control.<sup>16</sup> Many authors have recommended postoperative radiotherapy for aggressive histology and for high-grade lesions.<sup>8,16</sup>

However, in other studies histology was not an independent prognostic factor for disease-free survival.<sup>15</sup> In our patient, with Stage I disease and no positive margin or perineural invasion, local control was significantly achieved with laser excision of the tumor and postoperative radiotherapy.

## REFERENCES

1. Donovan DT, Conley J. Adenoid cystic carcinoma of the subglottic region. *Ann Otol Rhinol Laryngol* 1983;92(5):491-5
2. Van W, Snow GB, Van I. Intraoral adenoid cystic carcinoma. The presence of perineural spread in relation to site, size, local extension, and metastatic spread in 22 cases. *Cancer* 1990;66:2031-3.
3. Olofsson J, Van Norstrand AWP. Adenoid cystic carcinoma of the larynx: A report of four cases and a review of the literature. *Cancer* 1977;40:1307-13.
4. Cotton RT, Seid AB. Management of extubation problem in the premature child: anterior cricoid split as an alternative to tracheotomy. *Ann Otol Rhinol Laryngol* 1989;89:508.
5. Bryce DP. The laryngeal subglottis. *J Laryngol Otol* 1975;89(7):667-85.
6. Batsakis JG, Luna MA, El-Naggar A.K. Non squamous carcinomas of the larynx. *Ann Otol Rhinol Laryngol* 1992;101:1024-6.
7. Chummun S, McLean NR, Kelly CG, Dawes PJ, Meikle D, Fellows S, et al. Adenoid cystic carcinoma of the head and neck. *Br J Plast Surg* 2001;54(6):476-80.
8. Szanto PA, Luna MA, Tortoledo ME, White RA. Histologic grading of adenoid cystic carcinoma of the salivary glands. *Cancer* 1984;54:1062-9.
9. Aikawa H, Tomonari K, Okino Y. Adenoid cystic carcinoma of the external auditory canal: correlation between histological features and MRI appearances. *Brit J Radiol* 1997;70:530-2.
10. Spiro RH, Huvos AG. Stage means more than grade in adenoid cystic carcinoma. *Am J Surg* 1992;164:623-8.
11. Haddad A, Enepeklides DJ, Manolidis S, Black M. Adenoid cystic carcinoma of head and neck: a clinicopathologic study of 37 cases. *J Otolaryngol* 1995;24:201-5.
12. Garden AS, Weber RS, Morrison WH, Ang KK, Peters LJ. The influence of positive margins and nerve invasion in adenoid cystic carcinoma of the head and neck treated with surgery and radiation. *Int J Radiation Oncology Biol Phys* 1995;32:619-26.
13. Vikram B, Strong EW, Shah JP, Spiro RH. Radiation therapy in adenoid-cystic carcinoma. *Int J Radiation Oncology Biol Phys* 1984;10:221-3.
14. Chris H, Terhaard MD, Herman MD, Coen RN, Rasch MD, Peter C, et al. The role of radiptherapy in the treatment of malignant salivary gland tumors *Int J Radiation Oncology Biol Phys* 2005;61(1):103-11.
15. Re'gis de Brito Santos I, Kowalski LP, Cavalcante de Araujo V. Multivariate analysis of risk factors for neck metastases in surgically treated parotid carcinomas. *Arch Otolaryngol Head Neck Surg* 2001;127:56-60.
16. Kirkbride P, Liu FF, O'Sullivan B. Outcome of curative management of malignant tumours of the parotid gland. *J Otolaryngol* 2001;30:271-9.