Case Report

BEHCET'S DISEASE ASSOCIATED WITH HYPERTHYROIDISM: Case Report and review of literature

Ali Hassan Abro[1], Ahmed M Saleh Abdou[2], Jamal Al Saleh[3], Abdulla M Ustadi[4], Nadeem J Younis[5], Wafa F Doleh[6]

ABSTRACT

Behcet's Disease is a multi-system, chronic inflammatory disorder characterized by chronic relapsing course. Its principal manifestations are oral and genital ulcers as well as inflammation of the eyes, skin and joints, while vascular and neurological complications may results in death. The etiology and pathogenesis of the disease are still obscure and specific treatment is not available. We report the case history of a patient with Behcet's Disease. He presented with fever, arthritis and weight loss of 3-week duration. He was also found to have hyperthyroidism, extra-pulmonary tuberculosis, and strongyloidiasis. Although, the association between thyroid diseases and auto-immune connective tissue disorders as well as tuberculosis is well recognized, there had been, to the best of our knowledge, no reports of Behcet's Disease associated with thyroid dysfunction. However, further studies are required to investigate any association between Behcet's Disease and thyroid dysfunction.

KEY WORDS: Behcet's Disease, Thyrotoxicosis.

Pak J Med Sci April - June 2010 Vol. 26 No. 2 464-469

How to cite this article:

Abro AH, Abdou AMS, Saleh JA, Ustadi AM, Younis NJ, Doleh NF. Behcet's disease associated with hyperthyroidism: A case report and literature review of Behcet's Disease. Pak J Med Sci 2010;26(2):464-469.

1. Ali Hassan Abro, FCPS, MRCP,
2. Ahmed M Saleh Abdou, FRCP,
3. Dr. Jamal Al Saleh, MRCP, Rheumatology Unit.
4. Abdulla M Ustadi, M Sc,
5. Nadeem J Younis, FCPS,

1-2, 4-6: Infectious Diseases Department, Rashid Hospital Dubai, United Arab Emirates.

5: Dubai Hospital, Dubai, United Arab Emirates.

Correspondence:

Dr. Ali Hassan Abro
Infectious Diseases Unit,
Rashid Hospital Dubai,
UAE.
Email: ahabro@dohms.gov.ae
momal65@hotmail.com

* Received for Publication: March 16, 2009

* Accepted: February 2, 2010

INTRODUCTION

Behcet's Disease is a chronic multi-systemic inflammatory disorder dominated clinically by recurrent oral and genital ulceration, uveitis and skin lesions. It runs a chronic relapsing course, with unpredictable exacerbations which decrease in frequency and severity overtime.[1] Behcet's Disease is classified among the vasculitides affecting vessels of different types, sizes and locations.[2] It typically arises in young adults, although childhood-onset disease has also been reported, it affects both genders and has a world wide distribution.[1]. Here we report a case history of a patient who was admitted in the Infectious Diseases Unit of Rashid Hospital Dubai as a case of febrile illness for investigations. Initially, he was diagnosed to have extra-pulmonary tuberculosis, Thyroxicosis and

Strongyloidiasis. While in the hospital, the patient developed further symptoms which were highly suggestive of Behcet's Disease. In this article we will discuss the case history of the patient and literature review of Behcet's Disease.

CASE REPORT

A 25 year old Nepali, pipe fitter, who is not known to have a previous medical illness and has no history of recent travel, sexual exposure or contact with sick persons was admitted in the Infectious diseases Unit, Rashid Hospital Dubai through accident and emergency with complaints of fever, pain in ankle joints right more than left, decreased appetite and weight loss of three weeks duration. On clinical examination he appeared sick, toxic and mildly pale, Temp 38.9C, tachycardia, BP 120/70 mmHg and ankle joints were tender and warm but not swollen. He was admitted as a case of febrile illness for investigations.

Initial investigations: WBC 12.6x103 cell/ul, Hb 12.5gm/dl, Platelets 120x103 cells/ul, ESR 49 mm/h and CRP 78mg/dl. Blood urea, electrolytes, blood sugar, LFTs (ALT 48 IU/dl), coagulation profile and urine analysis were normal. Blood smear for malarial parasite and blood culture were negative. X-ray chest and ultrasound abdomen were also normal.

He received symptomatic treatment in the form of simple analgesics, anti-pyretic and NSAIDS, but as fever continued, he was started on empirical antimicrobial therapy (Meropenem 2gms IV TDS) on 3rd day of the admission. However, patient did not improved subjectively as well objectively and antibiotic was stopped after five days.

Further investigations: Repeat FBC, ESR and CRP showed significant raised values (WBC 15.6x103 cells/ul, Hb12.6gm/dl, Plat. 142x103 cells/ul, ESR 120 mm/h, CRP>150 mg/dl). Repeat septic screening including fungal culture was negative. Brucella, Chlamydia, Mycoplasma, Legionella and Hepatitis C antibodies were negative. Hepatitis B surface antigen, HIV screening, Syphilis serology (VDRL and TPHA) and Widal test were also negative. Free T3 (FT3) 6.0pmol/l, Free T4 (FT4) 36.7pmol/l (increased) and TSH<0.004 uIU/ml but anti thyroid antibodies were negative. On stool analysis several Strongyloides Stercoralis Larvae were seen. Tuberculin skin test was reported as strongly positive, measuring 20x20 mm with ulceration, as well as T-Spot *TB* test was positive. Rheumatoid arthritis factor, ANA, P-ANCA and C-ANCA were negative. Repeat ultrasound abdomen was normal, whereas, contrast CT scan abdomen and pelvis findings were suggestive of partial thrombosis of the left main branch of portal vein (Fig-1) with a few insignificant retroperitoneal lymph nodes. Thrombophilia screening was negative.

Anti-tuberculosis regimen, the anti thyroid drug (Carbimazole) and albendazole were started on the 8th day of the admission. However, patient did not experienced appreciable improvement, remained febrile and sick, and rather developed bilateral acute anterior uveitis with painful red eyes with photophobia as well as a few small aphthous ulceration on buccal mucosa and angle of the mouth. Repeat physical examination of external genitalia revealed two tender ulcers on the scrotum and one on the tip of penis. By direct questioning the patient disclosed that he used to get painful

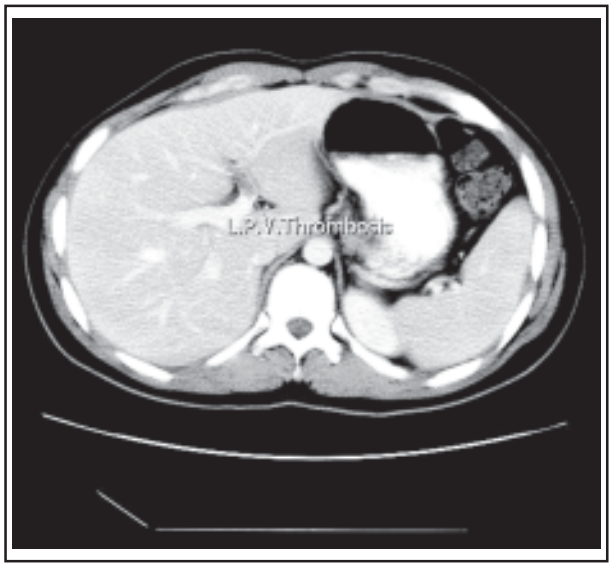

Fig-1: Contrast CT scan of the abdomen shows (arrow) filling defect of left branch of portal vein suggestive of Thrombosis.

mouth ulcers, but never scrotal or penile lesions in the past. The diagnosis of Behcet's disease was highly suspected and a rheumatology consultation was sought. Pathery test found to be positive. Pednisolone (1mg/Kg body) also started on 15th day of the admission. The new regimen resulted in a significant improvement in all clinical aspects as well as laboratory parameters. Patient was discharged after 21 days in the hospital apyrexial and in a good general condition.

DISCUSSION

Behcet's Disease (Behcet's Syndrome) is named after Hulusi Behcet (1889-1948), the Turkish dermatologist and scientist who first recognized the syndrome in one of his patients in 1924 and reported his research on the disease in Journal of Skin and Venereal Diseases in 1936.[3] Some also use the term Adamantiades Syndrome or Amantiades-Behcet syndrome, for the work done by Benediktos Amantiades.[4] Behcet's Disease has world wide distribution but it is considered more prevalent in the areas surrounding the old silk trading routes in the Middle East and in Central Asia. Thus, it is sometimes known as Silk Road Disease. The mean age at the onset of Behcet's Disease is most commonly in the third decade, although the age at the time of final diagnosis usually is in the 4th decade.[5] Both sexes are affected, however, geographical variations affecting predominantly males or females have been reported. Females are affected more in Korea, Israeli Jews and Camas village of Turky.[5-7] Whereas, high prevalence of Behcet's Disease in males is found in West Indies, Spain and Turkey.[8-10] Geographically variable prevalence of Behcet's Disease also has been observed, with highest incidence in Turkey (370/100000/year) and least in America (1/300000/year).[11,12]

Behcet's Disease can give rise a wide range of clinical manifestations which can lead to referral to one of a number of different specialties including dermatology, rheumatology, genitourinary medicine, gynecology, internal medicine, neurology, ophthalmology, oral medicine, etc.[13] Painful aphthous ulceration in the mouth is considered as a hallmark of the disease.[14] It is present in 98%, whereas, genital ulceration in 80% of the patients. Other skin lesions include acneiform folliculitis, papulo-pustular lesion, erythma nodosum and pathergy reaction.[15] The frequency of cutenous lesions in Behcet's Disease is similar in adults and children. There is no correlation between the number of papulo-pustular lesions and patient age, gender, duration of disease and age of onset of the disease. However, these lesions may be significantly more in patients with positive pathergy test.[16] Ocular manifestations include panuveitis, anterior uveitis, posterior uveitis, bilateral swelling of the optic nerve head, retinal vasculitis and bilateral lamellar macular hole. Ocular involvement occurs in 50%[13] of the patients and it is usually bilateral, although severity of the disease may differ between eyes. Ocular symptoms vary from gritty sensation and blurring of vision to severe pain and blindness.[17]

The neurological involvement occurs in 5%[18] and it includes pseudotumor cerebri, brain-stem involvement, neuropsychiatric symptoms and meningo-encephalitis. The clinical presentations consist of bilateral pyramidal signs, headache, mental disorders (memory defects, disinhibition and apathy), hemi paresis, sphincter disturbances, brain-stem findings, and pyramido-crerbellar syndrome.[19] The vascular manifestation of Behcet's Disease included thrombophlebitis, deep vein thrombosis, arterial obstruction and aneurysms; particularly of the pulmonary arties are common vascular complications of Behcet's Disease secondary to vasculitis involving arteries and veins.[20] Behcet's Disease also involves kidneys (glomerulonepheritis, amylodosis, renovascular involvement, interstitial nephritis) and the most commonly reported renal presentations are asymptomatic hematuria and proteinuria.[21] Gastrointestinal manifestations includes dysphagia, abdominal pain, diarrhea (occasionally bloody), intestinal perforation and peri-anal fistula secondary to ulceration. Children have a tendency toward more non-specific GI symptoms than adults.[22]

Other manifestations include cardiac (myocardial infarction, aneurysms, intracardiac thrombus, mitral valve prolapse, dilatation of the proximal aorta),[23] arthritis (variable incidence from 15 to 88% and mono arthritis is most common and it involves the knee, ankle, elbow joints),[10] amylodosis (associated with mortality up to 50% after 3.4 years)[24] and recurrent epididymo-orchitis(usually accompanied by multi-organ involvement).[25] Our patient had associated thyrotoxicosis; high prevalence of thyroid dysfunctions have been reported with connective tissue disorders[26] as well as tuberculosis,[27] however, to the best of our knowledge, we could not find any reported case of thyroid disease associated with Behcet's Disease. So it requires further research to prove whether Behcet's Disease has any association with thyroid disorder or if it was merely a coincidental finding. For the diagnosis of Behcet's Disease many criteria have been suggested but now there are internationally agreed criteria to diagnose Behcet's Disease (International Study Group for Behcet's Disease, 1990).[1,18,28] (Table-I).

The etiology and pathogenesis of this syndrome remain obscure. Autoimmune reaction triggered by an infectious or environmental agent in a genetically predisposed individual seems most likely.[1] A relationship between HLA-B5 has been confirmed in several studies of patients with Behcet's Disease from Middle East and Mediterranean countries.[29,30] HLA-B51 has also been found to have increased in frequency in Behcet's Disease and its frequency varies geographically; Kaya et al. has reported 51.1% patients were positive for HLA-B51 in Turkey,[10] whereas, 76.2% patients were positive in Israel Arab, as reported by Krause et al.[7] It has been suggested that the association of HLA-B51 may be more relevant to affected male than females.[31] Vasculitis is the main pathologic lesion and tendency to venous thrombus formation and circulating auto antibodies to human oral mucous membranes are found in approximately 50% of the patients.[28]

Laboratory findings are mainly nonspecific indices of inflammation, such as leukocytosis and elevated erythrocyte sedimentation rate, C-reactive protein levels; antibodies to the human oral mucosa are also found.[28] Pathergy test is non specific hyperactivity reaction observed in response to minor cutaneous trauma. Pathergy test is usually positive during active phases of the disease and becomes negative or weekly positive when disease remits and frequency of positive test is more in males than females.[32]

Treatment of Behcet's Disease is usually multidisciplinary, requiring close collaboration among specialists in rheumatology, ophthalmology and dermatology. Several effective anti-inflammatory and immunosuppressive regimens for Behcet's Disease currently exist, but none result in disease cure. All the available treatments are aimed at easing the symptoms, reducing the inflammation and controlling the immune activity. The long term use of this

Table-I: International Study Group Criteria for Diagnosis of Behcet's Disease.

Criteria	*Description*
Recurrent oral ulceration.	Minor/Major aphthous or herpetiform ulceration observed by Physician/patient, at least 3 times in a year.
Plus 2 of following:	
Recurrent genital ulceration.	Painful ulceration, observed by physician/patient.
Eye lesions.	Anterior uveitis, posterior uveitis, or cells in vitreous on slit lamp examination; or retinal vasculitis observed by ophthalmologist.
Skin lesions	Erythema nodosum, pseudofolliculititis or papulo-pustular lesions; or acneiform nodules observed by physician/patient not on steroids
Pathergy test +ve	Read by physician at 24-48 hrs, performed with oblique insertion of a 20-gauge or smaller needle under sterile conditions.

* Other causes of symptoms must have been excluded.

regimen can be associated with significant adverse effects, especially when it is started at a young age.[33] In Behcet's Disease, symptoms vary both in their recurrence rate and healing time so the therapeutic approach should be strictly individualized and goal of the management should be the initiation of an effective treatment to avoid recurrences and irreversible damage to vital organs. Male patients and those with early-onset disease usually require more aggressive treatment than do other affected individuals.[34] The therapeutic approach is also influenced by disease activity; however, there are no established criteria to define the severity of the disease. Most physicians consider that patients with vital organs at threat, mainly with ocular, parenchymaal, neurological and major vascular involvement have severe disease. In addition, some patients with chronic articular and mucocuteneous manifestations, which significantly impair quality of life, can also be classified as having severe disease.[35] Table-II Summarize the therapeutic approach for the management of Behcet's Disease.[13]

The course of Behcet's Disease is unpredictable, spontaneous remission often occurs and the disease may burn out in some patients with time. Males and early age at onset are associated with the more severe presentations of the disease, which include vascular thrombotic, ocular, gastrointestinal or central nervous system manifestations. It can lead to mortality up to 9.8% mainly due to severe disease and vascular involvement may be the major cause of death, particularly in young males. However, the mortality rate decreases significantly with the passage of time.[36] The disease generally runs improving or stable course and after 4th decade, the clinical severity reduces, with clinical complications generally recurring at longer intervals.[37] Therefore, the prognosis of Behcet's Disease is favorable, once the initial attack abates and patient does not develop severe disease.[27,38] In conclusion, Behcet's Disease is known to human beings since long but without much understanding of its etiology and pathogenesis, as well as effective or cure able treatment. Furthermore, we are still ignorant of why the disease is more prevalent in certain population with worse prognosis in males as well as geographical gender difference and decreased severity of the disease in later life.

Table-II: Outline of the drug treatment of Behcet's Disease[13]

Manifestation	*Treatment*	
	Mild disease	Severe disease[36]
Mucocutaneous:		
Mouth ulceration	Mouth wash Topical steroids	Thalidomide Azathioprine. Infleximab/ Etanercept.
Genital Ulceration	Topical steroids	Colchicine. Aazthioprine Infliximib.
Erythmanodosum		Colchicine. Corticosteroids.
Acneiform lesions		Local steroids/ Antibiotics (together)
Arthritis/ Arthralgia	NSAID	Colchicine Corticosteroids. Azathioprine. Interferon.
Ocular:		
Anterior Uveitis	Topical steroids.	
Pan and/or Posterior Uveitis.		Aazthioprine. Cyclosporine A. Corticosteroids. Interferon Infliximib.
Retinal Vasculitis.		Azathioprine. Cyclosporine A. Pulsed iv/oral steroids. Interferon Infliximib.
Vascular:		
Thrombophlebitis	Symptomatic treatment	Azathioprine Low dose Aspirin.
Arteritis		Pulsed iv/oral steroids. Pulsed iv/oral Cyclophosphamide. Azathioprine.
Neurological:		
Dura Sinus thrombosis		Corticosteroids + Anticoagulation
Parenchymal disease.		Pulsed iv/oral Cyclophosphamide Aazathioprine Pulsed iv/oral steroids. Infiliximab.
Gastrointestinal:		
Small/ large bowel ulceration		Sulphasalzine. Azathioprine/ Infliximib

REFERENCES

1. Al-Otaibi LM, Porter SR, Poate TWJ. Behcet's Disease: A review. J Dent Res 2005;84(3):209-22.
2. Kaklamani VG, Vaiopoulos G, Kaklamanis PG. Behcet's Disease. Semin Arthritis Rheum 1998;27:197-217.
3. Behcet H. Uber rezidivierende, Aphtose, Durch ein Virus Verursachete Geschwure am Mund, am Auge und an dan Gentitalien. Dermatologische Wouchenschrift, Hamburg 1937;105(36):1152-63.
4. Johns Hopkins Vasculitis Center. Johns Hopkins Vasculitis Center Discusses Behcet's Disease 2004. Retrieved September 9, 2005.
5. Bang D, Yoon KH, Chung HG, Lee RS Lee S. Epidemiological and clinical features of Behcet's Disease in Korea. Yonsei Med J 1997;38:428-36.
6. Bang D, Lee JH, Lee ES, Lee S, Choi JS, Kim YK, et al. Epidemiological and clinical survey of Behcet's Disease in Korea: the first multi-center study. J Korean Med Sci 2001;16:615-18.
7. Krause I, Mader R, Sulkes J, Paul M, Uzeil Y, Adawi M, et al. Behcet's Disease in Israel: the influence of ethnic origin on disease expression and severity. J Rheumatol 2001;28:1033-6.
8. Lannuzel A, Lamaury I, Charoentier D, Caprarros-Lefebvre D. Neurological manifestations of Behcet's Disease in a Caribbean population: clinical and imaging findings. J Neurol 2002;249:410-18.
9. Baixauli A, Calvo J, Tamarit JJ, Campos C, Garcia S, Herrera A. Behcet's Disease: retrospective study. Ann Med Interna 2001;18:405-10.
10. Kaya TI, Dur H, Tursen U, Gurler A. Association of class I HLA antigens with the clinical manifestations of Turkish patients with Behcet's Disease. Clin Exp Dermatol 2002;27:498-501.
11. Tuzun Y, Yurdakul S, Cem MM, Ozyazgan Y, Hamurydan V, Tuzun B, et al. Epidemiology of Behcet's Disease in Turkey. Int J Dermatol 1996;35:618-20.
12. O, Duffy. Behcet's Disease. Curr Opin Rheumatol 1994;6:39-43.
13. Barnes CG. Treatment of Behcet's syndrome. Rheumatology 2006;45(3):245-7.
14. Hellmann DB, Imboden Jr JB. Behcet's Disease. In: Current Medical Diagnosis and Treatment, 47th ed. McPhee SJ, Papdaskis MA, Tierney Jr LM Ed. New York McGraw-Hill 2008;744-5.
15. Alposy E. Behcet's Disease: treatment of mucocutaneous lesions. Clin Exp Rheumatol 2005;23:523-9.
16. Alopsy E, Aktekin M, Durusoy C, Yilmaz E. A randomized, controlled and blinded study of papulo-pustlar lesions in Turkish Behcet's patients. Int J Dermatol 1998;37:839-42.
17. Al Aboosi MM, Al Salem M, Saadeh A, Al Jamal M, Hijawi M, Khamash M, et al. Behcet's Disease: clinical study of Jordanian patients. In J Dermatol 1996;35:623-5.
18. Doherty M, Lanyon P, Raiston SH. Behcet's Disease. In: Davidsons Principles and Practice of Medicine 20th ed. Boon NA, College NR, Walker RB, Hunter JAA Ed. Churchill Livingstone 2006;1142.
19. Akapolat T, Akkayunlu M, Akapolat I, Dilek M, Odabas AR, Ozen. Renal Behcet's Disease: a cumulative analysis. Semin Arthritis Rheum 2002;31:317-37.
20. Akman- Demir G, Baykan-Kurt B, Serdarogula P, Gurvit H, Yurdakul S, Yazici H, et al. Seven year follow-up of neurological involvement in Behcet's Syndrome. Arch Neurol 1996;53:691-4.
21. Yazici H, Yurdakul S, Hamuryudan V. Behcet's Syndrome. In: Rheumatogy Klippel JH, Diepe PA, editors 1998. London; Mosby, 1-6.
22. Kone- Paut I, Gorchakoff-Molins A, Weschler B, Touitou I. Pediatric Behcet's in France. Ann Rheuma Dis 2002;61:655-6.
23. Mogulkoc N, Burgess MI, Bishop PW. Intracardiac thrombus in Behcet's Disease a systemic review. Chest 2000;118:479-87.
24. Melikoglu M, Altiparmak MR, Fresko I, Tunck R, Yurdakul S, Hamrudan V, et al. A reappraisal of Amyloidosis in Behcet's Syndrome. Rheumatology 2001;40:212-15.
25. Cho YH, Jung J, Lee KH, Lee ES, Lee S. Clinical features of Behcet's Disease and epididymitis. J Urol 2003;170:1231-3.
26. Arnaout MA, Nasrallah NS, Ei-Khateeb MS. Prevalence of abnormal Thyroid function tests in connective tissue diseases. Scand J Rheumatol 1994;23(3):128-132.
27. Vivek A. Endocrine dysfunction in tuberculosis. Int J Diab Dev Count 1999;19:71-7.
28. Moutsopoulos HM. Behcet's Disease. In: Harrison's Principles of Internal Medicine 16th edi. Kasper DL, Fauci AS, Longo DL, et al, ed. McGraw-Hill New York 2005;2014-15.
29. Al Fahad SA, Al Araji AH. Neuro- Behcet's Disease in Iraq: a study of 40 patients. J Neurol Sci 1999;170:105-111.
30. Krause I, Uzeil Y, Guedej D, MukamelM, Molad Y, Amit M, et al. Mode of presentation and multisystem involvement in Behcet's Disease: the influence of sex and age of disease onset. J Rheumatol 1998;25:1566-9.
31. Choukri F, Chakib A, Himmich H, Hue S, Caillat-Zucman S. HLA-B51 and B51 alleles confer predisposition to Behcet's Disease in Moroccan patients. Hum Immunol 2001;61:180-5.
32. Fresko I, Yazici H, Bayrmicili M, Yurdakul S, Mat C. Effect of surgical cleaning of the skin on the pathergy phenomenon in Behcet's syndrome. Ann Rheum Dis 1993;52:619-20.
33. Kaklaman VG, Kaklamanis PG. Treatment of Behcet's Disease: an update. Semin Arthritis Rheum 2001;30:299-312.
34. Yazici H, Ozyazgan Y. Medical Management of Behcet's syndrome. Dev Opthalmol 1999;31:118-131.
35. Sfikakis PP, Markomichelakis N, Alopsy E, Assad-Khalil S, Bodaaghi B, Gul A, et al. Ant-TNF therapy in the management of Behcet's Disease: review & basis for recommendation. Rheumatology 2007;46:736-41.
36. Kaural-Seyahi E, Fresco I, Seyahi N. The long term morbidity and mortality of Behcet's syndrome: A 2-decade outcome survey of 387 patients at a dedicated center. Medicine 2003;82:60-76.
37. Bardak Y. Effects of age and sex on Behcet's Disease. J Rheumatol 1999;26:1008-09.
38. Yazici H. Behcet's syndrome: where do we stand? Am J Med 2002;112: 75-6.