

## FOLEY'S CATHETER IN MANAGEMENT OF SUBGLOTTIC AND TRACHEAL INJURIES

Imtiaz A. Siddiqui<sup>1</sup>, Mohammed Umer Farooq<sup>2</sup>, Mohammad Usman<sup>3</sup>

### ABSTRACT

**Objective:** In patients of Sub glottis and tracheal stenosis adequate lumen is achieved by endoscopic diathermization or open surgical techniques. However it is difficult to maintain patency of the created lumen due to formation of granulation and fibrous tissues. Many prosthetic devices like Laryngeal stents, Montgomery T tubes are available which are inserted and fixed after attaining an adequate lumen during a surgical procedure. Purpose of this study was to design a cheap and easily available prosthetic device for such patients.

**Patients and Method:** It is a descriptive case series study of ten cases. A specially tailored stent of silicone lined Foley's catheter, which is freely available and economically priced was used for Subglottic and Tracheal stenosis.

**Results:** Good air way was achieved after one year with no decanulation difficulty in 9 cases (90%) with an unsatisfactory result (10%). After removing the foley's catheter Tracheostomy tube was corked for one month to observe the patency of newly formed airway in the Subglottic and upper tracheal region. When no difficulty in air way was observed it was finally taken out and the Tracheostomy was allowed to close by itself.

**Conclusion:** Silicone lined specially tailored stent of Foley's catheter is a good cheap alternate addition in prosthetic devices for restoration lumen in Subglottic and Tracheal stenosis.

**KEY WORDS:** Laryngo Tracheal injuries, Subglottic stenosis, Tracheal Stenosis, Trauma, Foley' cathter stent, Foley's catheter, Tracheal stenosis.

Pak J Med Sci May - June 2007 Vol. 23 No. 3 410-414

### INTRODUCTION

Trauma has always been a challenge to the surgeon. Laryngo Tracheal injuries are

constantly on the rise. One of the commonest presentations of a case of Laryngo-Tracheal stenosis is the history of trauma. In Pakistan a common cause of external Laryngo Tracheal injury is the homicidal assault usually as a result of violence. Another important cause in the rural settings of Pakistan is those caused by a mechanical saw or a device where some kind of strap breaks lose from the ensnaring the neck of worker often cutting through the Laryngo Tracheal skeleton. The incidence of Laryngo Tracheal strictures in survivors of inhalation injuries was found high.<sup>1</sup> Prolonged intubation was the cause of chronic Subglottic Stenosis.<sup>2</sup>

In cases of Sub glottis and tracheal stenosis adequate lumen is achieved by endoscopic diathermization or open surgical techniques. But it is most difficult to maintain patency of the created lumen due to the formation of

- 
1. Dr. Imtiaz A. Siddiqui  
Senior Registrar
  2. Dr. Mohammed Umer Farooq  
Assistant Professor of ENT,
  3. Dr. Mohammed Usman  
Assistant Professor
- 1-3: Jinnah Postgraduate Medical Centre,  
Karachi - Pakistan.

#### Correspondence

Dr. Imtiaz Ather Siddiqui,  
Senior Registrar, ENT,  
Jinnah Postgraduate Medical Centre,  
Karachi - Pakistan.  
E-mail: siddykee@yahoo.com

- \* Received for Publication: October 18, 2005
- \* Revision Received: January 24, 2006
- \* 2nd Revision Received: October 22, 2006
- \* Accepted: December 25, 2006

granulation and fibrous tissues. Many prosthetic devices like Laryngeal stents, Montgomery T tubes are available which are inserted and fixed after attaining the adequate lumen during a surgical procedure. The availability is difficult and cost of this prosthetics is high in a developing country like Pakistan where majority of such patients belong to non-affording class.

### PATIENTS AND METHODS

It is a descriptive study of ten cases. A specially tailored silicone lined Foley's catheter, which is freely available and economically priced was used in this study. These cases were referred to Jinnah Post Medical Centre Karachi (JPMC) during January 1997 to December 1999. Patients who sustained Laryngo tracheal injuries and developed subglottic stenosis were enrolled in the study from both sexes and all age groups.

Details of these patients are mentioned in Table-I. All patients had already tracheostomy done at referral hospitals as a life saving measure. Plain X-Ray neck antero-posterior (AP) and Lateral views and then MRI, CT Scans were carried out. Routine hematological assessments for General Anesthesia (GA) done.

Flexible Laryngoscopy from nasal rout and then retrograde through the tracheostome, rigid Direct Laryngoscopy (DL) under GA were done. Information gathered through all these were assessed for the residual Sub glottic lumen and graded according to Cotton's classification.<sup>3</sup>

Endoscopic diathermisation was planned. The lumen was widened by working in the entire periphery till an adequate lumen was achieved, through which trachea was visualized clearly without obstruction.

A silicone lined Foley's catheter was tailored by carefull measurements. A bevel was made at one end while other end had a horizontal cut. This tailored Foley's catheter (Picture-1) was introduced and positioned in such a fashion that the upper end lay just below the level of the vocal cords and the lowered beveled end

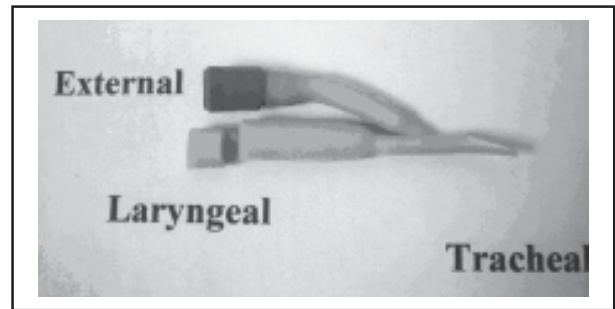


Figure-1

just above the tracheostomy (Picture-2 & 3). A post operative plain X-Ray neck AP & Lateral views were ordered to check the position of introduced tailored Foley's catheter.

### RESULTS

Nine patients were male and one female. Minimum age was fourteen years while maximum sixty. Mean age was 27.09 years. As these patients were followed up on monthly basis on each visit, patients were advised to observe personal hygiene and keep the wound area clean, position of the folly's catheter was checked by external examination, and Fiber optic examination. The catheter was changed after 6 week as an outpatient procedure carried out in theatre without any anesthesia. Throughout this time the patient was advised to plug his tracheostomy tube for varied intervals. Before extubation, the stent (Foley's catheter stent) was removed when a sufficient lumen was established. When the patient could tolerate a completely plugged tracheostomy

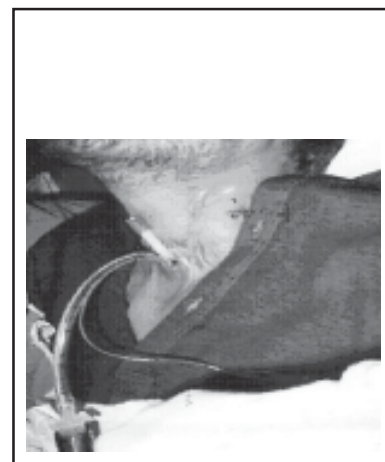

Figure-2

Table-I: Brief Descriptions of patients

Sex	Symptoms	Cause	DL Findings	CT/MRI	Cotton's grading of residual Lumen
M	Dyspnea on decanulation	RTA, neck injury leading to Tracheostomy	Subglottic granulation, no lumen	Horizontal split of trachea and cricoid	IV
M	Dyspnea on decanulation	Prolonged intubation Tracheostomy	Subglottic granulation, no lumen	Stenosis Cricoid to 3 <sup>rd</sup> Tracheal ring	IV
M	Dyspnea on decanulation	Accidental strangulation by muffler working on an agricultural machine leading to Tracheostomy	Subglottic granulation, no lumen	Stenosis Cricoid to 3 <sup>rd</sup> Tracheal ring	IV
M	Stridor Dyspnea on decanulation	Prolonged intubation	Subglottic granulation,	Stenosis Cricoid to 3 <sup>rd</sup> Tracheal ring	III
M	Dyspnea on decanulation	Prolonged intubation	Subglottic granulation, no lumen	Stenosis Cricoid to 2 <sup>nd</sup> Tracheal ring	IV
M	Dyspnea on decanulation	Accidental strangulation with muffler on agricultural machine leading to Tracheostomy	Subglottic granulation, no lumen	Stenosis Cricoid to 3 <sup>rd</sup> Tracheal ring	IV
M	Dyspnea on decanulation	RTA, neck injury leading to Tracheostomy	Subglottic granulation, no lumen	Stenosis Cricoid to 3 <sup>rd</sup> Tracheal ring	IV
M	Change of voice Dyspnea on decanulation	Accidental Tracheal cut by a wire leading to Tracheostomy	Subglottic granulation, no lumen	Stenosis Cricoid to 4 <sup>th</sup> Tracheal ring	IV
F	Hoarseness Dyspnea on decanulation	Prolonged intubation	Subglottic granulation, no lumen	Stenosis Cricoid to 3 <sup>rd</sup> Tracheal ring	IV
M	Hoarseness Dyspnea on decanulation	Gradual progressive respiratory distress leading to Tracheostomy	Granulation at ant. Commissure & Subglottic region, slit like lumen	Stenosis Cricoid to 4 <sup>th</sup> Tracheal ring	IV




Figure-3

tube for at least 2-3 weeks, Tracheostomy tube was removed and lumen allowed to close at its own. This period of completely removing the Foley's catheter stent varied from 4-12 month depending on the patency of the

tracheal lumen. Good air way was achieved after one year with no decanulation difficulty in 9 cases (90%) with an unsatisfactory result in one case (10%). (Picture 4,5 & 6)




Figure-4

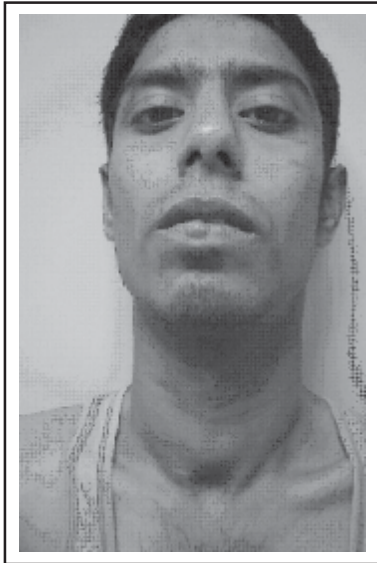


Figure-5

## DISCUSSION

Laryngo tracheal stenosis is a common complication, which results due to non-recognition or failed treatment of acute Laryngo Tracheal trauma. A high tracheostomy by an inexperienced surgeon often leads to subglottic stenosis. Many a time it is feasible to consider a tracheostomy to save life. It is a measure, which can save life, but it is also a form of surgical intervention, which may end up in a crippling state of chronic respiratory obstruction. Cotton R<sup>3</sup> has graded the Laryngo tracheal stenosis in four grades. The grading system is based on the presence of residual lumen after the injury.

The grading is as follow.

Grade I < 70% Lumen is present.

Grade II 70 to < 90% Lumen is present.

Grade III > 90% Lumen is present.

Grade IV No lumen at all.

One must carry out scientific grading of the lesion. Cotton's classification is universally accepted as standard, which we have also followed in our cases at JPMC. Radiology has a significant role to play. Being non invasive in nature. MRI scans has a significant advantage over the CT scan.

As regards management of the lesion, this study, which comprised of ten cases, is a

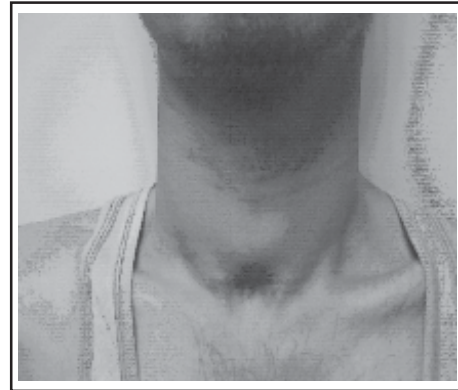

Figure-6

reasonable example of various modalities available in Pakistan. However 40% had Laryngo tracheal stenosis due to prolonged intubation, 20% had strangulation by muffler while working on agricultural machinery, 20% had it due to Road Traffic Accident (RTA). In contrast to another local study<sup>4</sup> satisfactory result as far as airway is concerned were achieved in this study. Overall prognosis in laryngotracheal stenosis in terms of good airway and voice is usually unsatisfactory. Literature does not give a good guide for a clear-cut management strategy for this problem. As such conservative means, open repair and endoscopic remedies are employed. Results are universally diversal dissatisfaction. Chronic laryngeal stenosis is a challenging problem, which necessitates surgical treatment to achieve a satisfactory respiratory condition.

A good number of patients in this series came due to intubation trauma. Constant laryngeal movements during respiration and swallowing cause abrasions and subsequent bacterial chondritis, attributes hyperemia, and prior radiation therapy as addition factors, which encourage secondary infection if intubation is prolonged.<sup>5</sup> A hasty emergency tracheostomy if it includes 1<sup>st</sup> tracheal ring may lead to subglottic stenosis.<sup>6</sup>

Endoscopic diathermization remedy is a modality, which is suitable like other endoscopic techniques if the cartilage is spared in the laryngo tracheal injury and the stenosis involves intra luminal soft tissue only. Our experience with endoscopic diathermization has

given satisfactory result in nine out of ten patients.

A newly designed thin walled silicone self-expanding Polyflex stent offers many advantages but it has a disadvantage of availability and being costly as well. This silicone stent has been used by Wassermann and colleagues in 19 patients with Subglottic and Tracheal stenosis. This thin walled stent improved the patient's clinical condition substantially. The mechanical properties of this prosthesis were excellent. Stent associated side effects were early mucous retention, in folding of inner silicone layer, stent and dislodgement. This novel self-expandable silicone airway stent may be a promising addition to commonly used stents.<sup>8</sup> Modified Foley's catheter which we used in our cases has much identical properties. It is a good alternate where Montgomery "T" tube or other stents are not available. However it requires a judicious and careful positioning. Small amount of granulation tissue was noted on endoscopy at the time of stent removal. We had no difficulty in effectively rediathermization these patients without any re-stenting except for one case where quantities of granulation were gross. A good index of the size of lumen is the ability to pass an appropriate sized bronchoscope. Final removal of tracheostomy is recommended when epithelialization is usually complete and patient can breathe easily with closed tracheotomy tube

This procedure offers an advantage of minimal hospitalization of the patient which is 24 hours after which they are discharged the next

day. It is cost effective because of short hospital stay and the material used. It has led to satisfactory results in which the patient is extubated after persistent plugging of the tracheostomy tube for 2-3 weeks. There have been no complications so far to the esophagus, or recurrent laryngeal nerves, which are alongside. In experienced hands it is a safe effective method of establishing the lumen, even in patients, after open surgery.

## REFERENCES

1. Gaissert HA, Lofgren RH, Grillo HC. Upper airway compromise after inhalation injury. Complex strictures of the larynx and trachea and their management. *Ann Surg* 1993;218(5):672-8.
2. Whitehead-E, Salam MA. Use of the dioxide laser with the Montgomery T-tube in the management of extensive subglottic stenosis. *J Laryngol Otol* 1992;106(9):829-31.
3. Cotton R. Proceedings World IFO'S Congress Sydney 1997;231.
4. Jalisi M, Udiapurwala IH. Laryngo tracheal stenosis diagnosis and management at Civil Hospital Karachi, Pak *J Otolaryngol* 1996;4:230-32.
5. Cherian JA, Raman RV. External laryngeal trauma: Analysis of thirty cases. *Laryngol Otol* 1993;107:920-23.
6. Strome M. Laryngeal stenosis. In: *The Larynx. A multidisciplinary approach.* Fried, M.P. (ed) Little Brown and Company, Boston 1988;155-9.
7. Strome M., Donhaue P. Advance in management of laryngeal and subglottic stenosis. *J Pead Surgery*, 1982;17:591-6.
8. Wassermann K, Koa A, Muller -Ehmsen J, Reuter M, Michel O, Eckel HE. Clinical and laboratory evaluation of a new thin-walled self-expanding tracheo bronchial silicone stent: Progress and pitfalls. *J Thorac Cardiovasc Surg* 1997;114:527-34.