Original Article

PREDICTORS OF SIDE BRANCH OCCLUSION AND ITS EARLY COMPLICATIONS AFTER ANGIOPLASTY IN BIFURCATION LESIONS

Ali Ghayemian[1], Y. Nozari[2], M. Safir[3], Reza A. Mohammadpour[4]

ABSTRACT

Objective: Coronary angioplasty in bifurcation lesions has lower success rate and more complications than other lesions. We performed this study to define early complications of angioplasty in these lesions and to find the predictive factors of major side branch (more than 1mm) occlusion.

Methodology: In this study, 104 consecutive patients with bifurcation lesion in a single center were evaluated. The side branches were classified based on diameter and morphology of the lesions.

Results: In 41 (39.4%) patients side branch compromise (SBC) occurred. In patients with SBC 34.1% had chest pain and in 3 (2.9%) patients non–Q wave myocardial infarction (MI) occurred, all after SBC. The incidence of non-Q wave MI after SBC was 7.3%. The probability of SBC in patients with ostial lesion of more than 50% was significantly higher (p=0.021) than patients without such a lesion. Also, if the main branch lesion was more than 80%; SBC was significantly higher (p=0.011) than patients without such lesions. Using multiple logistic regression analysis, only more than 80% stenosis in the main branch had significant relation with SBC [OR: 5.91; 95% CI (1.28-27.3); p=0.023]. SBC had no statistically significant relation with age, sex, length of the lesion and ejection fraction.

Conclusion: In angioplasty of bifurcation lesions, the presence of more than 80% stenosis of main branch increases the probability of SBC and more classifications may be unnecessary.

KEY WORDS: Coronary angioplasty, Bifurcation lesions, Side branch occlusion.

Pak J Med Sci April - June 2008 (Part-II) Vol. 24 No. 3 430-435

How to cite this article:

Ghayemian A, Nozari Y, Safir M, Mohammadpour RA. Predictors of side branch occlusion and its early complications after angioplasty in bifurcation lesions. Pak J Med Sci 2008;24(3):430-5.

INTRODUCTION

Bifurcation coronary lesions are prone to development of atherosclerosis because of turbulent flow. These lesions comprise about 15% of coronary interventions.[1-3] The risk of side branch occlusion is a well known complication of coronary intervention and has been reported to be about 12-41 percent.[4,5] Although occlusion of small side branches is well tolerated,[1,6-8] occlusion of larger side branches may cause more serious complications,[6,7] therefore different approaches are used for treating these lesions.[2,9] Drug eluting stents (DES) have

Correspondence

Dr. Reza Ali Mohammadpour,
Assistant Prof. of Biostatistics,
Department of Biostatistics,
Mazandaran University of Medical Sciences,
18th km Khazarabad Street,
Health Faculty,
PO Box: 48175-1553,
Sari, Iran.

E-mail: mohammadpour2002@yahoo.com

* Received for Publication: January 5, 2008

* Accepted: May 1, 2008

better long-term results for treatment of these lesions, but even with these stents the most effective technique for treating these lesions is unknown.[10-12] There are no clinical factors associated with increased risk of side branch occlusion (SBO) during percutaneous coronary intervention (PCI).[6] Based on anatomy and morphology of the vessel and the atheromatous plaque, many classifications have been developed.[7] Some believe that a large plaque at the bifurcation site, even without significant stenosis at the ostium of the side branch, can cause a snow plough effect and occlusion of the side branch.[5] However it seems that the main determinant of the fate of the side branch is the plaque volume in the main vessel and side branch.

The aim of this study was to evaluate the predictive factors of SBO in the setting of PCI of bifurcation lesions.

METHODOLOGY

Patient population: Between May 2003 and June 2004, 104 lesions in 104 consecutive patients with bifurcation lesion in whom PCI had been done were evaluated. Written consent was obtained from all patients. With the use of SIEMENS software, quantitative coronary angiography (QCA) diameter of main vessel, percent diameter stenosis of main vessel and side branch were measured. Side branches smaller than 1mm, thrombotic lesions, and acute myocardial infarction were excluded.

Procedures: All patients were treated before PCI with 325mg aspirin, loading dose and 75mg clopidogrel daily. During the procedure 80 units/kg heparin was used and for maintaining activated clotting time if needed to 300 seconds, we used 2500-5000 units additional heparin. We did not use IIb &IIIa inhibitor (reopro) in any patient.

Classification of bifurcation: Lesions were angiographically classified based on the Duke classification (Fig-1). The technique of treatment was similar in all patients. If the diameter of side branch was $\geq$2mm, both the main and side branch were wired, the main vessel

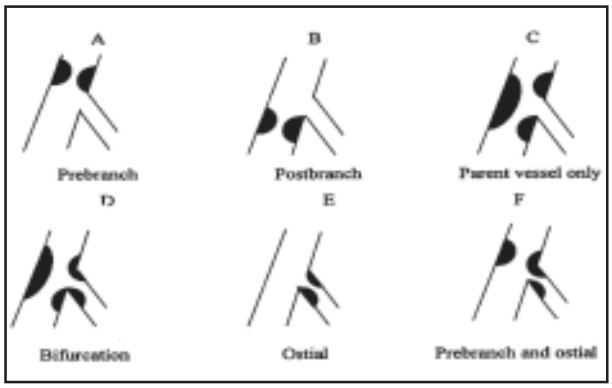

Fig-1: Duke classification of Bifurcation Lesions (19)

was then stented with the side branch wire jailed and then if needed guide wire exchange, kissing balloon dilation and provisional stenting of the side branch were performed. 12-lead electrocardiogram (ECG) before, one hour and 24 hours after the procedure was taken. Creatine kinase, MB isoenzyme every 8 hours was measured in all patients for 24 houres.

Definitions:

Side branch compromise (SBC): Occlusion of the side branch with $TIMI_2$ flow or less in the side branch.

Ostial Lesion: Diameter stenosis of 50 percent or more in the first 3mm of the proximal part of the side branch.

Q-wave myocardial infarction: Formation of the new Q-wave with a width of at least 0.040 seconds with increasing CK-MB isoenzyme of at least twice normal.

Non Q-wave myocardial infarction: It was defined as increasing serum CK MB isoenzyme to twice normal without new Q-waves on ECG.

Baseline characteristics of patients including age, sex, coronary artery disease risk factors, presence of unstable angina, left ventricular ejection fraction (EF) and other angiographic findings such as diameter of the main vessel and also the side branch were recorded.

Statistics: Continuous variables are presented as mean standard deviation and categorical variables with frequency percentage. Continuous variables were compared with student's t-test and frequencies with chi-squares or Fisher's exact test. All variables entered the

Table-I: Basic characteristics of patients

Age (years)	56.1±11.3
Male (%)	74
Risk Factor (%)	
Diabetese	20.2
Hypertension	37.5
Smoking	42.3
Hyperlipidemia	27.9
Unstable Angina (%)	44.2
Ejection Fraction (%)	56.3±12.4

multivariable stage irrespective of the results of univariable results. P-value less than 0.05 were considered statistically significant. We report crude and multivariable results with the corresponding 95% confidence interval (CI).

RESULTS

Patients' characteristics: The mean age of the patients was 56.1±11.3 (range 32-94). Seventy-four percent of patients were male, 20.2 had diabetes mellitus & 44.2% presented with unstable angina. The details are given in Table-I.

Angiographic analysis: The most frequent lesion was Type D (36.5%) and the most frequent vessel involved was left anterior descending/ diagonal (62.5%) (Table-II).

Lesion length was more than 15mm in 60.6% and diameter stenosis based on QCA was more than 80% in 81.7%. Diameter of the side branch was greater than 3 mm in 60.6% and less than 2 mm in 39.4%. Direct stenting was performed in 65.4% and side-branch stenting in 15 patients (14.4%).

Fate of the side branch: SBC occurred in 41 patients (34.4%), of whom 30 patients were male (Table-III). There was no statistically significant correlation between SBC and age, sex, and clinical characteristics. Ejection Fraction and SBC had no significant statistical correlation. After direct stenting the probability of SBC was higher than doing predilation and then implanting the stent in the main branch (p=0.047). When the ostial stenosis was more than 50%, the probability of SBC was higher than patients without such a lesion (p=0.021)

Table-II: Lesion Characteristics

Lesion Type	*Number*	*Percent*
A	12	11.5
B	16	15.4
C	26	25
D	38	36.5
E	0	0
F	12	11.5
Location of Lesion		
LAD/DIAG	65	62.5
LCX/OM	21	20.2
PDA/PLB	14	13.5
Others	4	3.8
Lesion Length		
Lesion Length >15mm	63	60.6
Lesion Length >20mm	24	23.1
Main Vessel Stenosis		
More than 80%	85	81.7

LAD= Left anterior descending; DIAG= Diagonal; LCX= Left Circumflex; OM=Obtus Marginal; PDA= Posterior Descending Artery; PLB= Posterior Lateral Branch

and when the diameter stenosis of the main vessel was more than 80%, the probability of SBC was significantly high (p=0.011). Using multiple logistic regression, only main branch stenosis more than 80% had significant association with SBC [OD: 5.91; 95% CI (1.28-27.3); p=0.023]. Lesion length had no effect on SBC.

Clinical Results: Chest pain during or after finishing PCI occurred in 18 patients (34%), of whom 14 cases were when SBC occurred; only 6.3% of patients without SBC had chest pain and this difference was significant (p<0.001) (Table-IV). Three non Q-wave MI (2.9%) occurred, all following SBC (p=0.029). The rate of non Q-wave MI after SBC was 7.3%. In all of these three cases wiring of the side branch after stenting the main branch was not successful. We had one death as a result of fatal arrhythmia.

DISCUSSION

Side branches originating from the stenotic portion of a coronary artery are associated with

Table-III: Predictors of SBC

Factor	*With SBC*	*Without SBC*	*p value*
Age (years)	57.3±12.8	55.4±11.2	NS
Male (Number, %)	30(73.2)	47(74.6)	NS
Risk Factors (Number, %)			
Diabetes	11(26.8)	10(15.9)	NS
Hyperlipidemia	10(24.4)	19(30.2)	NS
Smoking	14(34.1)	25(39.7)	NS
Unstable Angina	19(46.3)	27(42.9)	NS
Ejection Fraction (%)	54.7±10.8	51±11.7	NS
Direct Stenting (Number, %)	31(75.6)	37(58.7)	0.047
Ostial Stenosis>50% (Number, %)	26(63.4)	24(38.1)	0.021
Main Branch Stenosis>80% (Number, %)	38(92.7)	47(74.6)	0.011
Lesion Length>20mm (Number, %)	9(22)	15(23.8)	NS
Lesion Length>15mm (Number, %)	23(56.1)	40(63.5)	NS

NS= Non Significant

a higher risk of complications following PCI.[13] In fact, in the early years of coronary angioplasty, angioplasty of the bifurcation lesions was considered a contraindication for coronary angioplasty. In current practice, angioplasty of coronary arteries at the site of bifurcation comprises about 15% of coronary angioplasties.[3]

Occlusion of the side branch is a frequent complication after coronary angioplasty[1,6,14] with a reported incidence of SBO of approximately 35%,[15,16] which is in keeping with our study, where we found the incidence of SBC to be 39.4%.

In recent years stenting became the main treatment of coronary lesions and one of its potential complications is SBO which will occur as a result of thrombosis or mechanical occlusion.[17] In the study of Aliabadi et al, side branches with ostial stenosis more than 50% had a high incidence of SBO. Interestingly, the site of the lesion, characteristics of the lesion, stent type and clinical characteristic of the patients had no correlation with SBO after stenting the main vessel.[6] Design and type of stent has been shown to have no effect on early and late occlusion of the side branch.[7] As pointed out in many studies a significant lesion of the ostium of the side branch seems to be the main predictor of SBC during angioplasty.[6,8,15]

Table-IV: Clinical Complications

	With SBC	*Without SBC*	*p value*
Chest Pain (No, %)	14(34.1)	4(6.3)	0.000
MI (No, %)	3(7.3)	0	0.029
Death (No, %)	0	1(1.6)	NS

MI= Myocardial Infarction;
No= Number; NS= Non Significant

Many mechanisms have been suggested to explain the cause of occlusion of the side branches including plaque shift or snow plow effect, thrombus formation, spasm, ostial recoil, emboli of the plaque, dissection, covering of the side branch ostium by stent materials and finally endothelial dysfunction which will particularly occur at the bifurcation site.[1,4,6,11,17,18] By univariable analysis our findings showed that side branches with ostial stenosis are at high risk during PCI, however using multivariable analysis ostial stenosis more than 50% did not have a significant correlation with SBO. This may be because ostial lesions of moderate narrowing will not have the same outcome as more severe lesions, and volume of plaque will determine the occurrence of SBC. In our study we did not separate ostial lesions more than 50% on the basis of their severity, which may in part explain our findings.

The finding of a higher frequency of SBC in lesions with main branch diameter stenosis more than 80% supports the mechanism of

snow plow as the cause of SBC. In some studies using intravascular ultrasound (IVUS) negative remodeling in bifurcation lesions was seen to be more frequent than non bifurcation lesions and its cause is unknown.[19] In our study, as in other studies, the incidence of myocardial infarction (MI) and other clinical complications were low. Chest pain in one study has been reported to be 15% after occlusion of the side branch[20] and in our study it was about 34.1% of patients after occlusion of the side branch. Although the risk of MI in vessels smaller than 2mm is very low, the risk of MI is higher in vessels larger than 2mm with a definite stenosis at the ostium of the side branch, prompting different approaches to be considered for treating these lesions.[5] In our study all of three MI's were after compromising the side branches larger than 2mm.

Although many different techniques have been proposed for treating bifurcation lesions, there is no single intervention with predictable success rate for saving both the main and side branches.[21] As it has been pointed out in many previous studies, stenting the main vessel is generally considered to be an acceptable treatment for many coronary lesions, but in bifurcation lesions superiority of stenting the side branch to balloon angioplasty has not been established.[22,23] Newer techniques including specific bifurcation stents, high pressure stent implantation and pharmacologic antiplatelet agents are associated with acceptable clinical results.[24] In our study direct stenting was a univariate but not multivariate predictor of more frequent occurrence of SBO. We believe more evidence is required before recommending predilation in bifurcation lesions.

Although treatment of bifurcation lesions with drug eluting stents in historical comparison with bare metal stents (BMS) has lower cardiac complications, the most effective technique for stenting bifurcation lesions with DES is unknown.[10,12] On the other hand BMS can be used in bifurcation lesions with acceptable major adverse cardiac events (MACE).[25] The important point is choosing the suitable strategy for treating these lesions with consideration of potential PCI complications and this was the aim of our study to define the predictive factors of SBC to choose the best approach for treatment of these lesions.

CONCLUSION

This study showed the high incidence of procedural and clinical complications in patients with side branches with more than 50% ostial lesions and more than 80% diameter stenosis in the main branch. The incidence of complications in patients with side branches smaller than 2mm is small. Compromising side branches larger than 2mm can be accompanied by clinical outcomes as non Q-wave MI. Therefore, in patients with side branches larger than 2mm which have ostial lesions and or significant diameter stenosis in the main branch, particular care should be taken to preserve side-branch flow. On the other hand, lack of evidence showing serious complications in patients with side branches smaller than 2mm will make the protection of this vessels unnecessary and will not affect the strategy of treatment of the main vessel.

Limitations of the study: This study was a single center study and was non – randomized. In our center the preferred approach in most cases of bifurcation lesions is stenting the main branch, kissing balloon inflation and if necessary, provisional stenting of the side branch, so we didn't compare different approaches of bifurcation lesion treatments. Finally, we did not have systematic angiographic follow up for our patients.

REFERENCES

1. Koller P, Safian RD. Bifuraction stenosis. In Freed E, Safian RD, Grines C, eds. Manual of Interventional Cardiology. Birmingham, MI: Physician press, 1997;229-41.
2. Takebayashi H, Haruta S, Kohno H, Ichinose H, Taniguchi M, Shimakura T, et al. Immediate and 3-month follow up outcome after cutting balloon angioplasty for bifurcation lesions. J Interven Cardiol 2004;17:1-7.
3. Melikian N, Mario CD. Treatment of bifurcation coronary lesions. J Interven Cardiol 2003;16:507-13.

4. Timurkayank T, Ciftci H, Ozdemir M, Cergel A, Tauil Y, Kaya M, et al. Sidebranch occlusion after coronary stenting with or without ballon predilation: Direct versus conventional stenting. J Invasive Cardiol 2002;14(9):497-501.
5. Cervinka P, Foley DP, Sabate M, Coste MA, Serrano P, Ligthart JMR, et al. Coronary bifurcation stenting using dedicated bifurcated stents. Cathet Cardivasc Intervent 2000;49:105-11.
6. Aliabadi D, Tilli FV, Bowers TR, Benzuly KH, Safian RD, Goldstein JA, et al. Incidence and angiographic predictors of side branch occlusion following high pressure intracoronary stenting. Am J Cardio 1997;80:994-7.
7. Cho GY, Lee CW, Hong M-K, Kim J-J, Park SJ. Effect of stent design on side branch occlusion after coronary stent plancement. Cathet Cardiovasc Intervent 2001;52:18-23.
8. Vetrovec GW, Cowely MJ, Wolfgang TC, Ducey KC. Effect of percutaneous transluminal coronary angioplasty on lesion associated branches. Am Heart J 1985;109:921-5.
9. Jorgensen E, Helqvist S. Stent treatment of coronary artery bifurcation lesions. Eur Heart J 2007;28(4):383-5.
10. Steigen TK, Maeng M, Wiseth R, Erglis A, Kumsars I, Narbute I, et al. Randomized Study on Simple Versus Complex Stenting of Coronary Artery Bifurcation Lesions: The Nordic Bifurcation Study. Circulation 2006;114(18):1955-61.
11. Karvouni E, Di Mario C, Nishida T, Tzifos V, Reimers B, Albiero R, et al. Directional atherectomy prior to stenting in bifurcation lesions. A matched comparison study with stenting alone. Cathet Cardiovase Intervent 2001;53:12-20.
12. Hoye A, Van Mieghem C, Ong ATL, Aoki J, Rodriguez-Granillo GA, Valgimigli M, et al. Treatment of de novo bifurcation lesions: Comparison of, sirolimus – and paclitaxel – eluting stents. Euro Intervention 2005;1:24-30.
13. Meier B, Gruentzig AR, King SB, Douglus JS, Hollman J, Ischinger T, et al. Risk of side branch occlusion during coronary angioplasty. Am J Cardiol 1984;53:10-4.
14. Kobayashi Y, Colombo A, Adamina M, Nishida T, Moussa I, Moses JW. The skirt technique; A stenting technique to treat a lesion immediately proximal to the bifurcation (pseudobifurcation). Cathet Cardiovase Intervent 2000;51:347-51.
15. Satler F, Mintz GS, Pichard AD, Kont KM. Bifurcation disease: To treat or not to treat. Cathet Cardiovase Intervent 2000;50:411-12.
16. Alfonso F, Hernadez C, Perez–Vizcayno MJ, Hernandez R, Fernandez-Ortz A, Escaned J, et al. Fate of stent – related side branches after coronary intervention in patients with in – stent restenosis. J Am Coll Cardiol 2000;36:1549-56.
17. Mathias DW, Mooney JF, Lange HW, Golenberg IF, Gobel FL, Mooney MR. Frequency of success and complication of coronary angioplasty of stenosis at the ostium of a branch vessel. Am J Cardiol 1991;67:491-5.
18. Toutouzas K, Stankovic G, Takagi T, Albiero R, Corvaja N, Milici C, et al. A new dedicated stent and delivery system for the treatment of bifurcation lesions: Preliminary experience. Cathet Cardiovasc Intervent 2003;58:34-42.
19. Fujii K, Kobayashi Y, Mintz GS, Hirse M, Moussa I, Mehran R, et al. Dominant contribution of negative remodeling to development of significant coronary bifurcation narrowing. Am J Cardiol 2001;92:59-60.
20. Prasad N, Ali H, Schwartz L. Short and long term outcome of balloon angioplasty for compromised side branches after intracoronary stent deployment. Cathet Cardiovase Inervent 1999;46:421-4.
21. Marco J, Serruys P, Biamino, Fajadet J, Feyter P, Morice MC. Current approach for stenting bifurcation lesions. In: Lefevre T, Louvard Y, Morice MC. The Paris Course on Revascularization 2004;129-54.
22. Pan M, Lezo JS, Medina A, Romero M, Segura J, Ramirez A, et al. Stepwise strategy for the stent treatment of bifurcated coronary lesions. Cathet Cardiovasc Intervnt 2002;55:50-7.
23. Yamashita T, Nishida T, Adamina MG, Briguori C, Vaghetti M, Corvaja N, et al. Bifurcation lesions: two stents Vs one stent: immediate and follow–up results. J Am Coll Cardiol 2000;35:1145-51.
24. Heuser RR. Coronary lesion: The Good, The Bad and the Ugly. Cathet Cardiovase Intervent 2000;49:112.
25. Lefever T, Morice MC, Sengottuvel G, Kokis A, Dumas P, Garot P, et al. Influence of technical strategies on the outcome of coronary bifurcation stenting. Euro Intervention 2005;1:31-5.

Authors:

1. Ali Ghayemian, MD,
Associate Professor of Cardiology,
Department of Cardiology,
Mazandaran University of Medical Sciences,
Sari, Iran.
2. Y. Nozari, MD,
Assistant Professor of Cardiology,
Department of Cardiology,
Imam Khomeini Hospital,
Tehran University of Medical Sciences,
Tehran, Iran.
3. M. Safir MD,
Assistant Professor of Cardiology,
Department of Cardiology,
Ilam University of Medical Sciences,
Ilam, Iran.
4. Reza A. Mohammadpour, PhD,
Assistant Professor of Biostatistics,
Department of Biostatistics,
Mazandaran University of Medical Sciences,
Sari, Iran.