

EXTRA MAMMARY TUMORS METASTASIS TO THE BREAST

Alireza Mozaffari¹, Iran Rashidi², Faramarz Paziar³

ABSTRACT

In patients with known extramammary malignancies, Metastatic disease should be considered in the differential diagnosis of a palpable breast mass, particularly if there is a history of extramammary malignancy. Breast metastasis is usually indicative of diffuse metastatic disease and a poor prognosis. Biopsy and careful review of previous pathologic material assures prompt treatment and avoids an unnecessary radical operation. Breast metastases from extramammary tumors are rare with few cases reported. Four cases of metastasis to the breast are presented and the diagnostic problems of this condition are reviewed. Correlation between the histology of primary tumor and the cytology of breast metastatic tumors can avoid the surgical breast biopsy and unnecessary mastectomy. In conclusion, Metastasis to the breast has poor prognosis. We report a case of metastasis leukemia to breast presenting as a breast lump.

KEY WORDS: Breast, Leukemia, Metastasis.

Pak J Med Sci April - June 2008 (Part-II) Vol. 24 No. 3 468-470

How to cite this article:

Mozaffari A, Rashidi I, Paziar F. Extra mammary tumors metastasis to the breast. Pak J Med Sci 2008;24(3):468-70.

INTRODUCTION

Breast metastases from extramammary malignancies are uncommon, constituting about two per cent of all breast tumors. Breast metastasis may be confused with primary benign or malignant neoplasm of the breast.¹ An accurate diagnosis of breast metastasis is impor-

tant because the treatment and outcome of primary and secondary malignancies of the breast are completely different. The clinical features of 15 patients with breast metastases from extramammary malignancies, excluding lymphoma, between 1982 and 2001 were retrospectively reviewed.² There were two male and 13 female patients, with ages ranging from 16 to 73 years (median, 48 years). Primary tumors in the 15 cases were three hepatocellular carcinomas, two gastric carcinomas, two malignant melanomas, one colon carcinoma, one lung adenocarcinoma, one ovarian carcinoma, one uterine leiomyosarcoma, one nasopharyngeal carcinoma, one esophageal squamous cell carcinoma, one embryonal rhabdomyosarcoma, and one cervical carcinoma. Bilateral breast involvement was observed in two patients. A solitary lesion was evident in 13 patients, with six in the right breast and seven in the left. The interval between diagnosis of primary cancer and the

1. Alireza Mozaffari, MD, Dept of Internal Medicine,
 2. Iran Rashidi, MD, Dept of Pathology,
 3. Faramarz Paziar, MD, Surgery Ward,
- 1-3: School of Medicine, Ahwaz Jondishapour University of Medical Sciences, Ahwaz - Iran.

Correspondence:

Dr. Iran Rashidi,
Dept. of Pathology, School of Medicine,
Ahwaz Jondishapour University of Medical Sciences,
Ahwaz, Iran.
E-mail: i_rashidi@yahoo.com

* Received for Publication: January 24, 2008

* Accepted: March 18, 2008

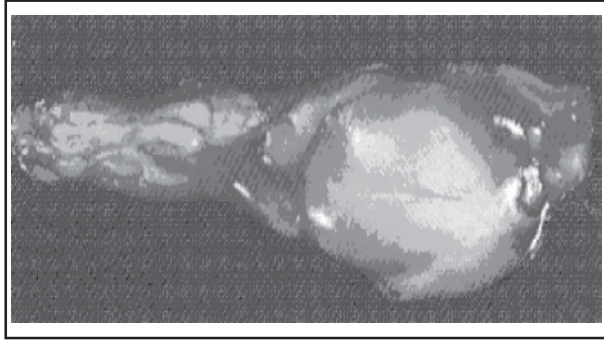


Figure-1: Gross of breast mass

discovery of breast metastasis ranged from 0 to 144 months (median, 12 months). The follow-up period of the primary tumor ranged from 7 months to 156 months (median, 17 months). Breast metastases were associated with disseminated metastatic disease in 14 of the 15 patients. Fourteen of the patients died within a year of breast metastasis diagnosis; median survival was 4 months.³ Breast metastases from extramammary malignancy are infrequent. Virtually any malignancy can metastasize to the breast. Breast metastasis usually indicates disseminated metastatic disease and a poor prognosis.⁴

CASE REPORT

A 47-year-old Arab woman presented with an 8-mm lobular density in the lower inner aspect of her left breast on her first screening mammography. A breast tissue specimen measuring 4 x 2.5 x 1 cm (Figure-1) was surgically removed. Microscopic sections revealed a 7-mm

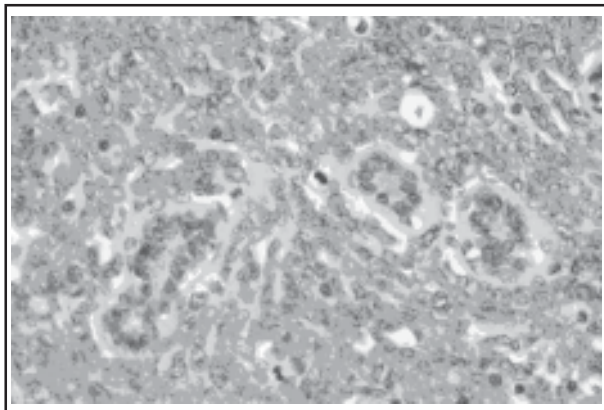


Figure-2: Microscopic changes of breast mass (H & E X 400)

nodule containing malignant round cells & hyperchromatic nucleus, numerous mitosis, consistent with metastatic leukemic cell to the breast (Figures-2&3), the patient was treated for two years for myeloid leukemia. The patient had no other evidence of metastatic disease. Metastasis to the breast from an extramammary malignancy is a rare finding. Its clinical incidence varies from 0.5 to 2%.¹⁻³

DISCUSSION

Metastases to the breast are very rare. The most common primary tumor is a contralateral breast carcinoma, followed by leukemia, melanoma, lymphoma, and ovary, lung and stomach cancer.⁵ In children, rhabdomyosarcoma is the tumor most commonly associated with breast metastasis.

Most metastases present as palpable breast masses that are usually mobile, but occasionally adherent to the skin.⁶ Rapid growth is characteristic. There is slight left breast predominance, and the most common site is the upper outer quadrant. Only rarely are they multiple or bilateral lesions. Mammographic evaluation can be useful in the differential diagnosis of primary *versus* secondary breast malignancy.⁷

The classic mammographic finding is a rounded, well-circumscribed mass. Typically there is no spiculation, microcalcification, or thickening of the skin. Mammographic evaluation of size correlates well with clinical measurements because the metastatic mass does

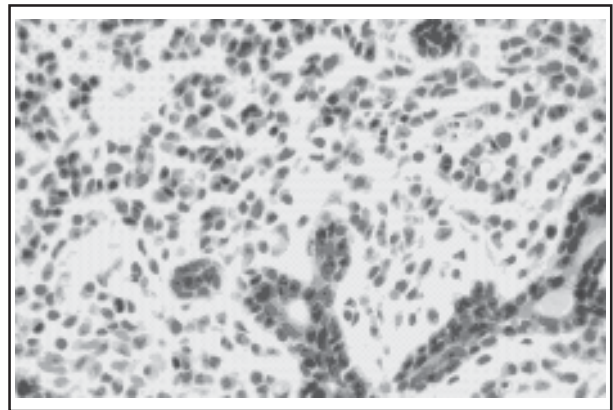


Figure-3: Microscopic changes of breast mass (H & E X 400)

not cause surrounding desmoplastic reaction in adjacent normal breast.^{1,2,3,8} Virtually any malignancy may metastasize to the breast. Metastases to the breast by extramammary malignant neoplasms are unusual. Sarcoma is an extremely rare cause of breast metastases and one case of breast metastases from Ewing sarcoma is the first report of breast metastases from sarcoma by Astudillo, Leonardo in 2005.⁸

In male patients, prostate is the commonest primary site of metastases to breast and nipple. This is somewhat more frequent in men on estrogen therapy for advanced malignancy. Most breast metastases in males are subareolar (corresponding to the distribution of glandular breast tissue in the male).⁹

In the patient with known extramammary cancer, the differential diagnosis of a breast mass should be expanded to include metastasis of that primary tumor to the breast. In the female patient, the most common primary site is contralateral breast, and in this case it may be difficult to differentiate this from a second primary lesion.¹⁰ Other common sites include melanoma, lymphoma (and leukemia), lung, and ovary.

REFERENCES

1. Steeg P. Molecular biology of breast metastasis: 'Has it spread?' Disarming one of the most terrifying questions. *Breast Cancer Res* 2000;2:396-9.
2. Carr JA. Treating Occult Breast Malignancy Presenting as Axillary Node Metastases. *J Am Col Surg* 2007;204(3):517-8.
3. David O, Gattuso P, Razan W, Moroz K, Dhurandhar N. Unusual Cases of Metastases to the Breast: A Report of 17 Cases Diagnosed by Fine Needle Aspiration. *Acta Cytol* 2002;46(2):377-85.
4. Alva S, Shetty-Alva N. An update of tumor metastasis to the breast data. *Arch Surg* 1999;134(4):450.
5. Topalovski M, Crisan D, Mattson JC. Lymphoma of the breast. A clinicopathologic study of primary and secondary cases. *Arch Pathol Lab Med* 1999;123(12):1208-18.
6. Kleer CG, Van Golen KL, Sofia D, Merajver SD. Molecular biology of breast metastasis: Inflammatory breast cancer - clinical syndrome and molecular determinants. *Breast Cancer Res* 2000;2:423-9.
7. Likaki-Karatza E, Mpadra FA, Karamouzis MV, Ravazoula P, Koukouras D, Margariti S, et al. Acute lymphoblastic leukemia relapse in the breast diagnosed with gray-scale and color Doppler sonography. *J Clin Ultrasound* 2002;30(9):552-6.
8. Leonardo A, Magali TL, Gwanael F, Frederic R, Veronique M, Christine C. Bilateral Breast Metastases From Ewing Sarcoma of the Femur. *Am J Clin Oncol* 2005;28(1):102-3.
9. Abel Gómez-Caro A, Piñero A, Roca MJ. Surgical Treatment of Solitary Metastasis in the Male Breast. *The Breast J* 2006;12(4):366-7.
10. Ramar K, Pervez H, Potti A, Mehdi S. Breast metastasis from non small cell lung carcinoma. *Medical Oncology* 2003;20(2):181-4.