

ADENOMYOSIS UTERI IN INFERTILE WOMEN: EXPERIENCE IN A TROPICAL COMMUNITY TEACHING HOSPITAL

Adebiji Gbadebo Adesiyun¹, Modupeola Omotara Samaila², Abimbola Kolawole³

ABSTARCT

Objectives: To determine the demographic pattern and clinical presentation of 23 infertile women with intraoperative diagnosis of adenomyosis followed by histopathologic confirmation.

Methodology: A review of 23 consecutive infertile women that underwent surgery due to preoperative misdiagnosis for uterine fibroids over a period of 5 years.

Results: The patients mean age was 37.3 years with age range of 26 to 47 years. Only five patients (21.7%) had delivered before. Eighteen patients (78.3%) had had abortion(s) in the past. Secondary infertility accounted for 78.3% and 21.7% had primary infertility. Past gynaecological procedures included dilatation and curettage or manual vacuum aspiration in 17 (73.9%) patients, previous adhesiolysis for uterine synechiae in 3 (13.1%) patients and past history of myomectomy in 5 (21.7%) patients. Preoperative hysterosalpingogram showed only 2 patients (8.7%) with bilateral tubal patency and 17 patients (73.9%) had bilateral tubal blockage. Unilateral patency of the fallopian tube was observed in 4 (17.4%) patients. Amongst patients with bilateral tubal blockage, cornual blockages were mostly encountered in 15 (88.2%) of the 17 patients. The modes of clinical presentation were abdominopelvic mass 100%, dymenorrhoea 82.6%, menorrhagia 60.9%, dyspareunia 47.8% and metrorrhagia in 34.8% of cases. Intraoperatively adenomyosis encountered were diffuse adenomyosis in 13 (56.5%) patients, multiple focal adenomyosis in 7 (30.4%) patients and unifocal adenomyosis in 3 (13.1%) patients. Co-existing uterine fibroid were found in 17 (73.9%) of the 23 patients. Two patients (8.7%) had coexisting endometriosis. At surgery, significant pelvic adhesion was encountered in 7 (30.4%) patients.

Conclusion: In infertile women, adenomyosis is significantly associated with proximal tubal occlusion and tends to co-exist with insignificant uterine fibroids.

KEYWORDS: Adenomyosis, Diagnosis, Infertility.

Pak J Med Sci January - March 2008 Vol. 24 No. 1 38-43

1. Dr. Adebiji Gbadebo Adesiyun (FWACS),
Department of Obstetrics & Gynaecology,
 2. Dr. Modupeola Omotara Samaila (FMCPATH),
Department of Pathology,
 3. Dr. Abimbola Kolawole (FWACS),
Department of Obstetrics & Gynaecology,
- 1-3: Ahmadu Bello University Teaching Hospital,
Shika - Zaria, Kaduna State, Nigeria.

Correspondence

Dr. Adebiji G. Adesiyun,
P.O.Box: 204,
Kaduna - Kaduna State,
Nigeria.
Email: biyi.adesiyun@yahoo.com

* Received for Publication: August 29, 2007

* Accepted: November 3, 2007

INTRODUCTION

Adenomyosis is a benign gynaecological condition characterised by extension of endometrial gland and stroma into the uterine musculature. Though the aetiopathogenesis of adenomyosis is not fully understood, nonetheless, hypothesis ranging from lack of basement membrane to defective membrane at endometrial myometrial interface (EMI) have been postulated.¹ Other proposed pathophysiological mechanism is hormonal derangement in neonates resulting in defective differentiation of stromal and myometrial cells with subsequent

predisposition to adenomyosis in adulthood.² Lately, immunologic³ and biochemical factors⁴⁻⁷ have been linked to adenomyosis. Based on the hypothesis that mechanical damage or disruption of the EMI interface can lead to adenomyosis, risk factors are trauma to the uterus from childbirth and abortion. Other risk factors are chronic endometritis, hereditary factors and hyperoestrogenemia.^{1,8}

Infertility is hardly associated with adenomyosis because it is a condition that is usually diagnosed from the fourth decade of life. Nevertheless, due to increased desire towards career attainment and fulfilment amongst our women, with resultant postponement of first pregnancy and childbirth, there may be increase in cases of adenomyosis being diagnosed in the infertility clinic.

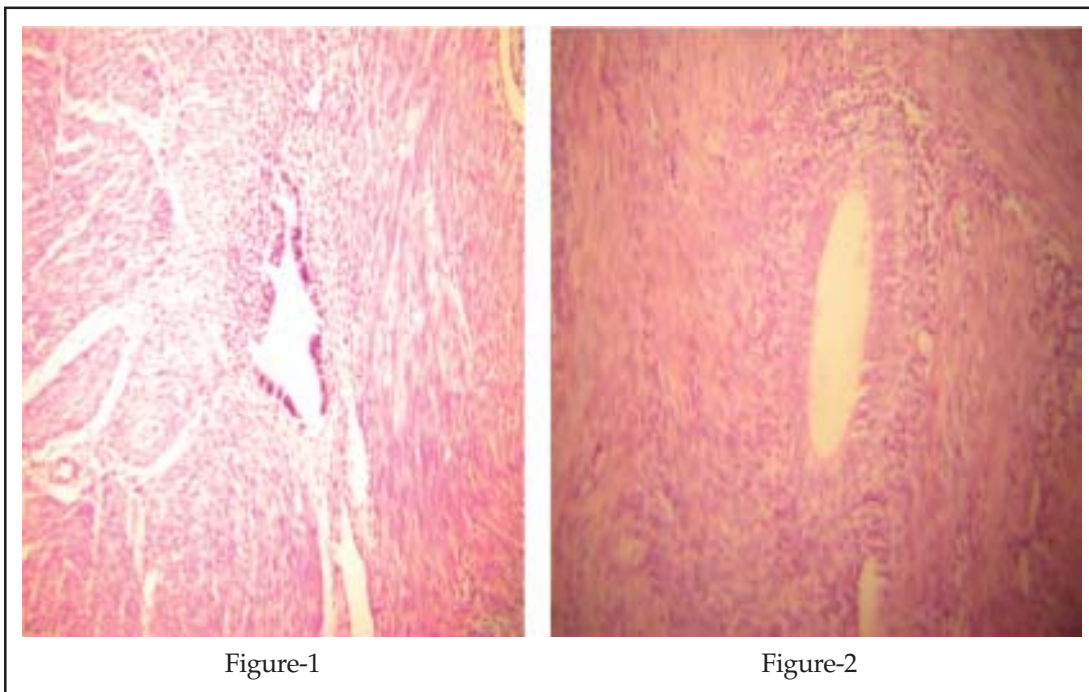
Accuracy in diagnosing adenomyosis is usually deficient and fraught with errors. This has led to delay in diagnosis and institution of treatment. Management of adenomyosis is difficult and cumbersome. A common differential diagnosis of adenomyosis is leiomyoma. In some instances, like in the case series presented, misdiagnosis has erroneously led to surgical

intervention.⁹ Against this background, we evaluated the demographic variables, clinical presentation and intraoperative findings of twenty three consecutive infertile women with intraoperative diagnosis of adenomyosis, having been misdiagnosed as leiomyomata during infertility workup and assessment.

METHODOLOGY

A prospective review of 23 consecutive infertile women that had surgery due to preoperative misdiagnosis of uterine fibroid and intraoperative diagnosis of adenomyosis uteri. The study was conducted in a community teaching hospital over a period of 5 years from June 2000 through July 2005.

The twenty three patients were being evaluated for infertility. They had abdominal sonography and hysterosalpingography preoperatively. Intraoperative, biopsy was done with or without debulking. The tissues were subjected to histopathologic examination (Figures-1&2). They were adequately counselled post-operatively.



Figures: 1 & 2: Microscopic factors of adenomyosis following haematoxylin and eosin stain.

RESULTS

The patients mean age was 37.3 years with age range of 26 to 47 years. Of the 23 patients, 19 (82.6%) were age 35 years and above. Secondary infertility accounted for 78.3% (18 patients) and 21.7% (5 patients) had primary infertility. Nineteen patients (82.6%) have been infertile for more than 10 years. Seventeen patients (73.9%) had previous history of dilatation and curettage or manual vacuum aspiration, three patients (13.0%) had previous history of adhesiolysis for uterine synechiae. Five patients (21.7%) out of the 23 patients had past history of myomectomy. Past obstetric history showed that only 5 (21.7%) patients had delivered in the past and 18 (78.3%) patients had history of previous abortions (Table-I).

Table-I: Profile of patients

Variables	N = 23	Percentage
Age		
< 30 years	2	8.7
30 – 40 years	14	60.9
41 – 50 years	7	30.4
Type of infertility		
Primary	5	21.7
Secondary	18	78.3
Duration of infertility		
1 – 10 years	4	17.4
11 – 20 years	12	52.2
21 – 30 years	7	30.4
Previous childbirth		
0	18	78.3
1	3	13.1
2	1	4.3
3	1	4.3
Previous abortions		
None	5	21.7
Spontaneous	5	21.7
Induced	13	56.5
Previous uterine / Intrauterine procedure		
Dilatation and curettage/ MVA	17	73.9
Adhesiolysis	3	13.1
Myomectomy	3	13.1

MVA – Manual Vacuum Aspiration

The clinical presentations were mainly abdominopelvic mass 100%, dysmenorrhoea 82.6%, menorrhagia 60.9%, dyspareunia 47.8% and metrorrhagia in 34.8%. Preoperative hysterosalpingogram revealed 17 (73.9%) patients had bilateral tubal blockage, 4 (17.4%) patients had unilateral tubal blockage and 2 (8.7%) patients had bilateral tubal patency. Site of tubal blockage was cornual in 15 of the 17 patients with bilateral tubal blockage and in all the 4 patients with unilateral tubal blockage (Table-II). Post-operative re-evaluation of all HSG done before surgery showed that one patient's HSG has the characteristic adenomyotic findings of small multiple spicules extending from the endometrium into the myometrium (Figure-3).

Intraoperatively, 13 (56.5%) patients had diffuse adenomyosis and 10 (43.5%) patients had focal adenomyosis. Coexisting uterine fibroid was found in 17 (73.9%) patients, most of which were insignificant fibroid seedlings in 13 (76.5%) of the 17 patients. Only two (8.7%) patients had co-existing endometriosis. Pelvic adhesion was encountered in seven (30.4%) patients, of which four of them had had previous myomectomy (Table-III). All the 23 patients had biopsy from the affected myometria and only 6 had partial local excision. Of the 23 patients, only one patient could be placed on gonadotrophin releasing hormone analogue.

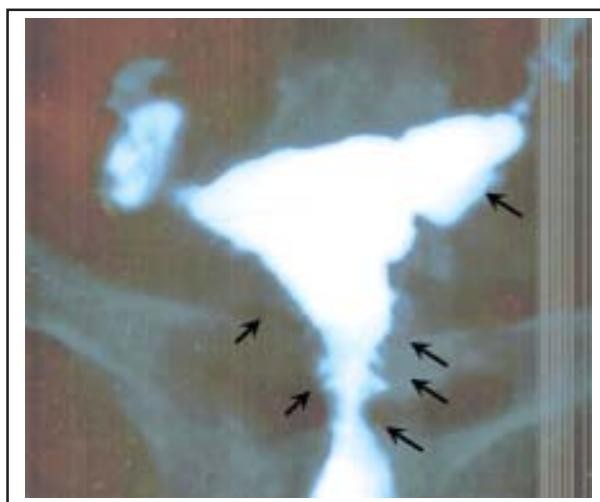

Figure-3: Hysterosalpingographic finding of multiple spicules extending from the endometrium into the myometrium in a patient with adenomyosis uteri

Table-II: Clinical Presentation

Variable	N = 23	Percentage
- Symptoms and signs		
Abdominopelvic mass	23	100
Dysmenorrhoea	19	82.6
Menorrhagia	14	60.9
Dyspareunia	11	47.8
- Tubal finding on HSG		
Bilateral tubal patency	2	8.7
Bilateral tubal blockage	17	73.9
*Cornual (15) *Distal (2)		
Unilateral tubal blockage		
*Cornual (4)	4	17.4

HSG - Hysterosalpingogram

* Site of blockage

() Number

DISCUSSION

The diagnosis of adenomyosis uteri remains a difficult diagnosis that is fraught with errors. This is because the clinical presentation is similar to other common benign gynaecological conditions like leiomyoma and endometriosis. Furthermore, the imaging diagnostic features of adenomyosis are variable and non-standardized on sonography and magnetic resonance imaging (MRI).¹⁰ A high index of suspicion is therefore needed to make a diagnosis of adenomyosis. Whereas, adenomyosis was usually diagnosed on pathologic examination of hysterectomy specimen, the introduction of transvaginal sonography (TVS) and MRI into clinical practice have revolutionized and increased the detection rate of adenomyosis. Though the sensitivity and specificity of TVS and MRI are both good in diagnosing adenomyosis, MRI is slightly superior and preferred because the imaging features are better recognisable and distinct.¹¹ In our series, none of the patients had TVS or MRI in their preoperative evaluation. They all had transabdominal sonography (TAS) which have been associated with poor resolution and sensitivity.^{12,13} It was however not surprising that all the cases were misdiagnosed as leiomyoma in our study.

Adenomyosis is a disease of premenopausal and multiparous women.^{8,9} On the contrary, only 8.6 percent of patients in our series were

multiparous, although all were premenopausal. More pertinent, is the finding that majority of patients (78.2%) had had abortion previously. This may corroborate the hypothesis of trauma (mechanical damage) to EMI in the aetiopathogenesis of adenomyosis.^{14,15} To further substantiate this hypothesis, is the significant percentage of our patients that had undergone intrauterine procedure in the past. The reason why adenomyosis may be associated with infertility has not been fully explained. Nevertheless, the explanation is centred around the EMI as a functional unit that is made up of basal endometrium and subendometrial myometrium. This functional

Table-III: Intraoperative Findings

Variable	N = 23	Percentage
Uterine size		
12 – 20 weeks size	14	60.9
> 20 weeks size	9	39.1
Type of adenomyosis		
Diffuse	13	56.5
Focal	10	43.5
Coexisting fibroid	17	73.9
*Insignificant seedling (13)		
*Significant fibroid (4)		
Coexisting endometriosis	2	8.7
Presence of pelvic adhesion	7	30.4

* type of fibroid

() Number

unit is important in sperm transportation, conservation of pre-implantation blastocyst, embryo implantation and placental development.¹⁶ These functions are mainly achieved through retrograde contraction of subendometrial myometrium during the non-menstrual phase of a woman.^{17,18} Of significance in our series is the high percentage of tubal occlusion at the cornua. Could the occlusion be due to obstruction of the fallopian tube at the cornua by infiltrating adenomyotic tissue or may it be due to mechanical compression of the fallopian tube at the cornua by adenomyosis, more importantly the focal type? Intraoperatively, biopsy of the myometrium with adenomyotic tissue was done for all patients, and this confirmed our diagnosis after histopathologic examination. The suspicion of adenomyosis arose when there was absence of pseudocapsule in what seemingly looked like myoma. Blind random needle biopsy has been associated with low sensitivity in the diagnosis of adenomyosis; because the outcome of the result is dependent on the depth/extent of mucosal infiltration by adenomyotic tissue and the number of biopsies.¹⁹

The only form of treatment we offered was partial excision of the affected myometrium in six of the twenty three patients. Other forms of conservative management are endomyometrial ablation, laparoscopic myometrial electrocoagulation and vessel embolization.²⁰ Hysterectomy was not an option in our study, because the patients were desirous of fertility. Same can be said for endomyometrial ablation as a form of treatment in infertile women with adenomyosis.

Hormonal treatment using gonadotrophin releasing hormone (GnRH) analogue; Zoladex was employed postoperatively in one patient and this resulted in symptomatic improvement and reduction in uterine size, although conception was not achieved. Other studies have recorded pregnancies and live births following treatment with GnRH analogue.^{21,22} Other forms of hormonal treatment include oral contraceptive, progestogen, anti-oestrogen, and intrauterine devices loaded with either

levonorgestrel or danazol. Authors have used combination of surgery (microsurgical complete resection) and hormonal (GnRH analogue) treatment with success in conception and live births.^{23,24} A promising conservative form of treatment is the use of high-intensity focused ultrasound (HIFU) in the management of adenomyosis uteri.¹⁰

In conclusion, we found a strong association between previous abortion and intrauterine procedures with adenomyosis. Furthermore, the high rate of cornual tubal occlusion we recorded, calls for more study in this direction.

REFERENCES

1. Kuligowska E, Deeds L III, Lu K III. Pelvic pain: overlooked and underdiagnosed gynaecological conditions. *Radiographics* 2005;25:3-20.
2. Parrott E, Butterworth M, Green A, White INH, Greaves P. Adenomyosis – a result of disordered stromal differentiation. *Am J Pathol* 2001;159:623-30.
3. Ota H, Igarashi S, Hatazawa J, Tanaka T. Is adenomyosis an immune disease? *Hum Reprod Update* 1998;4:360-7.
4. Ota H, Igarashi S, Hatazawa J, Tanaka T. Immunohistochemical assessment of superoxide dismutase expression in endometriosis and adenomyosis. *Fertil Steril* 1999;72:129-34.
5. Ota H, Igarashi S, Kato N, Tanaka T. Aberrant expression of glutathione peroxidase in eutopic and ectopic endometrium in endometriosis and adenomyosis. *Fertil Steril* 2000;74:313-8.
6. Ota H, Igarashi S, Sasaki M, Tanaka T. Distribution of cyclo-oxygenase-2 in eutopic and ectopic endometrium in endometriosis and adenomyosis. *Hum Reprod* 2001a;16:561-6.
7. Ota H, Igarashi S, Tanaka T. Xanthine oxidase in eutopic and ectopic endometrium in endometriosis and adenomyosis. *Fertil Steril* 2001b;75:785-90.
8. Byun JY, Kim SE, Choi BG, Ko GY, Jung SE, Choi KH. Diffuse and focal adenomyosis : MR imaging findings. *Radiographics* 1999;19:161-70.
9. Tamai K, Togashi K, Ito T, Morisawa N, Fujiwara T, Koyama T. MR imaging findings of adenomyosis : correlation with histopathologic features and diagnostic pitfalls. *Radiographics* 2005;25:21-30.
10. Devlieger R, D'Hooghe T, Timmerman D. Uterine adenomyosis in the infertility clinic. *Hum Reprod* 2003;9(2):139-47.
11. Chopra S, Lev-Toaff AS, Ors F, Bergin D. Adenomyosis: common and uncommon manifestation on sonography and magnetic resonance imaging. *J Ultrasound Med* 2006;25:617-27.
12. Siedler D, Laing FC, Jeffrey RB, JR Wing VW. Uterine adenomyosis. A difficult sonographic diagnosis. *J Ultrasound Med* 1987;6:345-9.

13. Bohlman ME, Ensor RE, Sanders RC. Sonographic findings in adenomyosis of the uterus. *Am J Roentgenol* 1987;148:765-6.
14. Azziz R. Adenomyosis: current perspectives *Obstet Gynecol Clin North Am* 1989;16:221-35.
15. Mori T, Ohta Y, Nagasawa H. Ultrastructural changes in uterine myometrium of mice with experimentally induced adenomyosis. *Experientia* 1984;40:1385-7.
16. Udewela AS, Perera MAD, Aiqing L, Fraser IS. Endometrial – myometrial interface: relationship to adenomyosis and changes in pregnancy. *Obstet Gynecol Survey* 2000;55:390-400.
17. Lyons EA, Taylor PJ, Zheng XH, Ballard G, Levi CS, Kredentser JV. Characterization of subendometrial myometrial contractions throughout the menstrual cycle in normal fertile women. *Fertil Steril* 1991;55:771-4.
18. DeVries K, Lyons EA, Ballard G, Levi CS, Lindsay DJ. *Am J Obstet Gynecol* 1990;162:679-82.
19. Popp LW, Schwiedessen JP, Gaetje R. Myometrial biopsy in the diagnosis of adenomyosis uteri. *Am J Obstet Gynecol* 1993;169:546-9.
20. Wood C. Surgical and medical treatment of adenomyosis. *Hum Reprod Update* 1998;4:323-36.
21. Huang FJ, Kung FT, Chang SY, Hsu TY. Effects of short-course buserelin therapy on adenomyosis. *J Reprod Med* 1999;44:741-4.
22. Silva PD, Perkins HE, Schauburger CW. Life birth after treatment of severe adenomyosis with a gonadotropin – releasing hormone agonist. *Fertil Steril* 1994;61:171-2.
23. Lin J, Sun C, Zheng H. Gonadotropin – releasing hormone agonists and laparoscopy in the treatment of adenomyosis with infertility. *Chin Med J* 2000;113:442-5.
24. Wang PH, Yang TS, Lee Wl, Chao HT, Chang SP, Yuan CC. Treatment of infertile women with adenomyosis with a conservative microsurgical technique and a gonadotropin – releasing hormone agonist. *Fertil Steril* 2000;73:1061-2.

Send your comments on the published manuscripts

Readers are most welcome to comment on the manuscripts published in this issue. Their communications will be published in the Correspondence Section of the Journal and they won't be sent for peer review. While sending your comments, do remember to mention the title of the original manuscript and your contact details including e-mail.

Send your communications by e-mail on pjms@pjms.com.pk or pulse@pulsepakistan.com