Review Article

UNICOMPARTMENTAL KNEE ARTHROPLASTY AND ITS MINIMALLY INVASIVE VERSION

Riaz S[1] & Maistrelli GL[2]

ABSTRACT

Unicompartmental Knee Arthroplasty (UKA) is still considered to be a controversial issue even after three decades of its presence on the Orthopaedic horizon. The initial dismal results of Unicompartmental Knee Arthroplasty and the concurrent excellent results reported by the Total Knee Arthroplasty series are the responsible factors. Currently there has been a renewed interest in UKA because of excellent results reported in the last decade. The recent results of UKA are comparable to Total Knee Arthroplasty (TKA) and are better than High Tibial Osteotomy (HTO). Meticulous patient selection, better implant designs and refined surgical techniques are responsible for the improved results. The procedure is primarily performed for single compartment arthritis which most frequently is medial compartment. Indications and contraindications of the procedure are still evolving. Both fixed and mobile bearing UKA have shown good results. Revision of UKA has not been found as complicated as quoted by the initial reports. Among few questions which still remain unanswered by the current literature are its role in younger patients, optimal implant designs, correct indications /contraindications and the proper surgical technique. Minimally invasive techniques in UKA have shown encouraging early results. Its minimally invasive version is a technically demanding procedure and surgeons not familiar with this technique will benefit from appropriate preoperative instruction. Abstracts of all articles appearing under the heading of Unicompartmental arthroplasty or Unicondylar arthroplasty in Medline were retrieved and reviewed by the primary author; in addition references from major orthopedic and arthroplasty textbooks were obtained. Only relevant papers were included after discussion among the authors.

KEY WORDS: Unicompartmental Knee Arthroplasty , Osteoarthritis, Medial compartment, High Tibial Osteotomy, Total Knee Arthroplasty, Minimally Invasive Surgery

Abbreviations:

UKA:	Unicompartmental Knee Arthroplasty	SKAR:	Swedish Knee Arthroplasty Registry
TKR:	Total Knee Arthroplasty	MIS:	Minimally Invasive Surgery
HTO:	High Tibial Osteotomy	ROM:	Range Of Motion
APT:	All Polyethylene Tibia	PCA:	Porous Coated Anatomic
MBT:	Metal Backed Tibia	DVT:	Deep Vein Thrombosis
OA:	Osteoarthritis	KSS:	Knee Society Score
RA:	Rheumatoid Arthritis	HSS:	Hospital for Special Surgery Score
CRR:	Cumulative Revision Rate	ACL:	Anterior Cruciate Ligament

Pak J Med Sci July-September 2005 Vol. 21 No. 3 361-374

1. Dr. Salman Riaz FCPS
Fellow Spinal Surgery,
University of Alberta, Edmonton, Alberta, Canada
Email: sriaz@ualberta.ca
2. Dr. Gianni L. Maistrelli MD, FRCS(C)
Associate Professor & Chief of Orthopaedics,
Toronto East General Hospital,
University of Toronto, Ontario, Canada
Email: gmais@tegh.on.ca

Correspondence:
Dr. Salman Riaz,
Suite No. 308, 11012, 82-Avenue,
Edmonton, Alberta T6G 2P6, Canada
Email: salmanezad2004@yahoo.ca

* Received for publication: February 23, 2005
Revision received: March 3, 2005
Revision accepted: May 5, 2005

Total Knee Arthroplasty (TKA) is one of the most successful procedures in Orthopaedic surgery today with well defined Indications and excellent results. The acceptance of TKA can be judged by the fact that during 1996 and 1997 about 250,000 TKA were performed in United States. In contrast to that even after three decades of experience of Unicompartmental Knee arthroplasty (UKA), it remains a controversial issue in orthopaedics, with conflicting results of success and failures. In the nineties, UKA was only sparingly used in most of the academic institutions of United States. In 1996 and 1997 surgeons in United

States performed only 2500 unicompartmental knee arthroplasties[1]. The reason for the unpopularity of UKA was dismal results[2,3,4] reported in the initial series but with the improvement in patient selection, refinement of implants[5,6,7], surgical techniques, component materials and fixation options the results of UKA reported in the recent literature[1,8,] are almost comparable to the Total Knee Arthroplasty.

Currently there has been an increased interest in Unicompartmental arthroplasty. Few of the reasons are recent reports showing excellent results[1,8], more physiologic and conservative operation retaining both Cruciate ligaments and the other two compartments, accelerated rehabilitation compared with Total knee arthroplasty, increased range of motion, low incidence of blood transfusion and infection, more normal feel , improved proprioception with the UKA compared to TKA, low cost and the likelihood that a future revision to a TKA will not be complex. Repicci[9] described UKA as "an arthritic bypass" procedure suggesting it as a "pre-TKA". He advised a combination approach i.e. a UKA performed earlier and is used as a supplement to the TKR done later. The UKA will absorb approximately 10 years of functional capacity and when a future arthroplasty is needed the longevity of the entire knee prosthetic system is prolonged. The UKA in conjunction with the TKA may increase the survivability of the entire knee prosthetic system to 20-30 yrs.

Studies show that osteoarthritis affects the knee in distinct patterns with principal involvement of a single compartment. The involvement of the other compartments is usually mild and the progress slow. Most commonly affected compartment is the medial compartment which is affected in isolation in about 25% of the patients with osteoarthritis. Changes limited to isolated affection of lateral compartment are present in 5% of the patients. On the medial side the degenerative process starts anteriorly both over tibia and femur. It is this anteromedial disease for which unicompartmental arthroplasty is most suited to though Hendel et al[10] have shown good results after use of UKA in mild Tricompartmental disease in elderly low demand population. Repicci[9] describes it as an anatomic defect of the articular cartilage in the extension gap with no corresponding defect in the flexion gap. In patients with damaged or ruptured ACL the area of deepest wear moves posteriorly, and progressing to formation of osteophytes in the intercondylar notch and lateral subluxation of the tibia.

Considering the diversity and undecided nature of the subject, abstracts of all articles appearing under the heading of Unicompartmental arthroplasty or Unicondylar arthroplasty in Medline were retrieved and reviewed by the authors, in addition references from major Orthopedic and Arthroplasty Textbooks were obtained. After discussion among authors only relevant papers were retrieved completely from the respective Journals. Since it is not a meta-analysis so no statistical analysis was performed.

INDICATIONS AND CONTRAINDICATIONS

This procedure is primarily done for arthritis involving single, medial or lateral compartment of the knee (Figure I). Erosion of Patellofemoral joint especially the medial facet, the medial margin of the lateral femoral condyle and fibrillation of cartilage of lateral condyle is not considered a contraindication by few authors. The fixed flexion deformity should not be more than 15 degrees[11]. Ten Degrees of varus deformity and 15° of valgus deformity is acceptable but they should be passively correctable. There should be adequate range of motion[12] of the knee which should be at least 90°. The absence of Anterior Cruciate Ligament (ACL) is still considered to be a contraindication in UKA. Goodfellow and O'Connor[13] reviewed clinical results in patients with mobile bearing Oxford UKA. They found that cumulative success rate in 165 joints in which ACL was normal at 6 years was 95% whereas the 110 joints with a damaged or absent ACL was only 81%($p<0.05$).

Chondrocalcinosis has been cited by most authors as a contraindication as it may lead to progression of the arthrosis into the unresurfaced compartment.

Figure-I: Preoperative X-rays Showing medial compartment arthritis. Postoperative X-rays shows Femoral and metal backed Tibial components in place.

There should be no rest pain[12]. Rest pain indicates inflammatory origin for the pain. Patients suffering from polyarthropathy should not be considered for unicompartmental arthroplasty even when there appears to be end stage medial osteoarthritis. The results[14] of UKA reported in the Swedish Knee Arthroplasty Register (SKAR) have not supported its use in rheumatoid arthritis. They reported a much higher revision rate of UKA in rheumatoid knees compared with those performed in knees in which the disease was likely to stay confined to one compartment.

Previous High Tibial Osteotomy (HTO) is also cited as relative contraindication by Rees et al [15] for UKA. Comparison of a group of primary Oxford UKA with another group of similar UKA after failed HTO showed that the revision rate in primary group was 3.1% compared with 27.7% in the failed HTO group. Mean duration to revision in primary group was 4.1years compared to 2.9years in HTO group, the difference was statistically significant. The authors concluded that reason for high failure rate in HTO group was over correction of an already valgus knee leading to progression of arthritis in the lateral compartment. Ritter[16] et al prospectively analyzed 4021 knees intraoperatively who were subjected to TKA, for assessment to qualify as a candidate for UKA. These patients had a medial tibiofemoral Osteoarthritis (OA) and all had a varus or a neutral (<5° valgus) alignment. They applied following criteria for qualification: Normal ACL, Normal lateral meniscus, No or mild patellofemoral or lateral femoral osteophytes, no more than grade II patellofemoral and grade I lateral femoral chondromalacia. They found that only 247 (6.1%) of the patients qualified as candidates for UKA, when slightly more stringent criteria were used (patellofemoral chondromalacia grade I or 0) only about 3.5% of the patients got qualified for UKA. They also found that patients with preoperative varus alignment of 5-8° had significant tendency to get selected as a candidate for UKA which peaked at 7°. In another study only 6% of the patients could qualify as candidates for unicompartmental arthroplasty[17].

UNICOMPARTMENTAL ARTHROPLASTY - IMPLANT DESIGN

Marmor[18,19] in 1973 introduced the prosthesis which involved replacement of both femoral and tibial surfaces. The femoral component was made of stainless steel and a tibial component that was cemented on cancellous bone within a cortical rim as inlay prosthesis. The designer after reporting a 10-13-year follow-up[20] recommended the widest tibial component be used to allow the prosthesis to rest on the peripheral cortical rim. It has been one of the most widely used unicompartmental arthroplasties.

Gunston designed the Polycentric prosthesis with separate unicompartmental components. This design had a constrained articular bearing with a narrow tibial component leading to subsidence. Therefore later on unconstrained designs were introduced which became the standard for many years.

St. George Sled[21] introduced in Germany in the seventies an all polyethylene flat and minimally constrained tibial component. The femoral component was rounded in the sagittal plane to avoid edge loading. Both the Marmor

and the St. George sledge prostheses were later, in the mid-eighties, also offered with metal backed tibial components and were at the same time slightly modified as regards the femoral component, resulting in the Richard Mk III and Endo-Link, respectively. Robert-Brigham unicompartmental knee is also a similar design.

Mobile or meniscal bearing knees were developed and later refined by the group at Oxford[22]. The philosophy behind the design was to create an implant that would have a high contact area leading to low point-loading, allow normal kinematics of the knee as before by being unconstrained so there is minimal stress at implant bone interface and the forces at juxta-articular bone should be only compressive. This implant would decrease wear as well as loosening. The original meniscal bearing design introduced in the seventies consisted of a spherical femoral component, a flat tibial component and a plastic washer in between. The initial design (Phase I) had a high dislocation rate (3%) so it was modified (Phase II) leading to a decreased dislocation rate[23] which was 0.4%. The recent design Oxford Phase III UKA now consists of a spherical femoral component, a polished tibial component and a fully congruent unconstrained polyethylene bearing which articulates with the femoral component and has a flat surface which is articulates with the tibial surface (Figure II). The articulation[24] has a contact area of 5.7cm^2. The femoral and tibial components are available in various sizes along with polyethylene spacers from 3 to 10 mm.

Cementless designs in UKA have not been found to have a comparable success with the cemented designs. Higher failure rates have been reported due to femoral and tibial component loosening.

Some of the causes of failure of earlier designs were thin polyethylene and the techniques used for manufacturing and sterilization of the polyethylene. The modularity introduced in the initial fixed bearing designs by using tibial metal base plates lead to decreased thickness of polyethylene in these designs leading to failure and damage to tibial base plate. The earlier designs also had a narrow dimension of femoral components in coronal plane leading to subsidence into the femoral condyles[25]. The biomechanical disadvantage associated with fixed bearing implants was that only one compartment was being replaced and with the intact ligaments the knee would try to retain the normal kinematics of the joint. Any extra constraints posed by this arthroplasty will resist the normal kinematics and leading to increased stresses at the cement-bone interface leading to a theoretically increased risk of loosening. So in fixed bearing UKA (Figure III) this issue was dealt with by designing implants with minimal constraints offered between the articulating surfaces. This

Figure-II: The Mobile or Meniscal bearing Design, Phase III Oxford Unicompartmental Arthroplasty, with fully congruent unconstrained meniscal bearing (Biomet Ltd).

Figure-III: A fixed Bearing Design (Accuris, Smith & Nephew, USA) with flat metal backed tibial articulating surface.

is achieved by a round or flat femoral component on a flat tibial polyethylene which would allow relatively normal kinematics of the joint to take place. On the other hand it leads to high point -loading at the metal-polyethylene interface.

The issue of using metal backed or all polyethylene tibial insert is still controversial. Studies have shown that metal backed tibia (MBT) reduces the compressive loads at the bone implant interface. The disadvantages of using a MBT are that in order to get an adequate thickness of polyethylene more tibial bone resection is required because the metal backing also occupies 3-4 mm. If an enough tibial resection is not done a thinner polyethylene insert may be used which will accelerate wear and lead to failure. Another disadvantage is that one more interface is added which might enhance wear and the locking mechanism might also fail. The proposed advantage of MBT is that it improves fixation of the implant and only the polyethylene can be changed rather complete tibial base plate which is rarely the case. Hyldahl[26] et al In a prospective randomized study analyzed the loosening of MBT and all polyethylene tibia (APT) with radiostereometric analysis at 3, 12 and 24 months. They found no significant difference in the clinical and radiostereometric outcome of both implants. The HSS scores for both types of implants were also similar. They concluded that MBT is not superior in fixation to the all Polyethylene tibia and considering its advantages they recommended all polyethylene tibia.

CLINICAL RESULTS

The early series showed dismal results with UKA but the few reasons for failure were the poor implant design and lack of proper patient selection. Insall and Walker[2] and later on Insall and Aglietti[3] reported poor results on a series of patients undergoing UKA. At the latest followup according to Hospital for Special Surgery Knee score out of 28 knees only one knee was excellent, seven good, four fair and ten poor. Seven knees (28%) had been revised to a TKA. In this series 15 patients underwent patellectomy prior to UKA. Laskin[4] in 1978 reported on 37 Marmor UKA prosthesis with a minimum followup of 2 years. Inspite of employing strict indications for surgery only 65% of patients reported adequate relief of pain.

Marmor[27] in 1988 reported on the results of 60 UKA followed for a minimum of 10 years. There were 53 medial UKA and 7 lateral UKA with an average age of 65 years. The criteria used in patients were not that stringent. According to the Hospital for Special Surgery Score thirty knees were excellent, 8 good, 4 fair and 18 were poor. Seventy percent of the patients had satisfactory result with pain relief accomplished in 86.6% of the patients. The major causes of failure were tibial component loosening, progression of disease in the opposite compartment and patellofemoral impingement Marmor attributed the 21 failures in his series to poor implant design and improper selection of the patients due to the learning curve. He predicted that with the improvement in patient selection and implant design will take the success of the procedure to more than 90%.

Murray[8] et al reported results for medial UKA for knees with an intact ACL and primarily anteromedial arthritis. They used meniscal bearing Oxford Knee (Phase I and PhaseII). The ten year analysis showed survival figures of 98%. There were five reoperations. Two for progression of arthritis in the lateral compartment, one each for infection, unexplained pain and dislocation of the meniscal bearing. They had one more dislocation of the meniscal bearing which was reduced closed with a good subsequent result. They concluded that in medial compartmental OA unicompartmental arthroplasty with mobile bearing can survive for long period of time with low reoperations and complication rate.

Svard[28] et al have reported a 95% survival rate at 10 years in medial UKA. They retrospectively analyzed results of 124 patients who underwent Oxford UKA for medial compartmental osteoarthritis. Revision procedures were required in 6 patients with dislocation in three, loosening in two and infection in one

patient. Two other patients required operations for removal of loose body and closed reduction of the mobile bearing.

In one study 699 Oxford knees, reported to the Swedish knee arthroplasty register in 1983-1992, were identified[29] and compared with 2364 Marmor prostheses reported during the same period. It was found that the revision rate for the Oxford prostheses after one year was higher than that for the Marmor prostheses. This difference increased gradually and after 6 years the revision rate was more than twice that of the Marmor group. No significant wear problems were noted in the revised Oxford prostheses. Frequent dislocation of the polyethylene meniscus were noted, and there were more cases of femoral than tibial component loosening. Exchange of the meniscus rarely prevented the need for further revision with exchange arthroplasty. Two units having done more than 100 Oxford operations had the same crude revision rate as those doing fewer and there was no improvement in revision rate of Oxford knees over time.

Results of Fifty one Miller-Galante UKA prosthesis were analyzed by Richard Berger[1] et al at an average follow-up of 7.5 years. On an average the other compartment had grade II arthritic changes. The Kaplan-Meier 10 years survival analysis with radiographic loosening or revision as the end point showed a survival of 98%. A recent report[70] on the same group of patients at an average follow-up of 13 years showed good clinical results. The Kaplan-Meier survivorship with loosening or revision for any reason was 95.7% ± 4.3% at 15 years.

Robertson[30] et al reported from the Swedish registry that the TKA patients had lower revision rate than the UKA patients-i.e., 10-year cumulative revision rate (CRR) of 12% and 16%, respectively. After adjusting for age, gender and year of operation, UKA patients were found to have a 2-day shorter hospital stay and fewer serious complications than TKA patients. The mean estimated cost of a unicompartmental implant was 57% of that of a tri-compartmental implant.

Squire[31] et al analyzed results in 142 Marmor UKA done for medial and lateral compartment arthritis. At a minimum 15 year follow up only 14 knees were revised. Survivorship analysis using revision surgery for any reason as an end point was 84% ± 9% at 22 years. Survivorship analysis using revision surgery for aseptic loosening as an end point was 93% ± 5% at 22 years.

The results for lateral compartment UKA have not been as consistent as for the medial compartment UKA. The reasons described are the different kinematics of both the compartments. Ashraf[32] et al analyzed results in 88 knees with isolated lateral compartment arthritis undergoing Lateral UKA (St. George Sled). The valgus deformity was intentionally under corrected. At a mean follow-up of nine years (2 to 21) 15 knees had revision surgery, nine for progression of arthritis, six for loosening, four for breakage of a component and four for more than one reason. The survival rate of 83% at ten years and of 74.5% at 15 years was reported which is comparatively inferior to medial compartment UKA. Comparing the results with the mobile bearing UKA for lateral compartment with a higher failure and complication rate the authors concluded that only fixed bearing UKA should be used for the lateral compartment arthritis.

The decision whether to do a fixed or a mobile bearing UKA is still controversial. The various advantages of a fixed bearing are technically easier to perform, no chances of meniscal dislocation and with flat on flat or flat or spherical articulation may still allow near normal kinematics of the knee. The advantages cited by the meniscal bearing group are the fully congruent articulation reducing the point-loading as in flat on flat articulations leading to very low wear rate as quoted as 0.036mm/year linear wear by the Oxford Group. Secondly the unconstrained meniscus provides a normal kinematics without excessive forces/stress at the bone and cement-implant interface. The disadvantage of the mobile bearing is that it requires precise matching of the flexion and extension gaps and is technically more demanding to use. Any mismatching of the

flexion-extension gap leads to meniscal dislocation. The other objection raised by few authors is that in the fear of dislocation it is quite likely that a thicker spacer be inserted in the resurfaced compartment to make it more stable leading to overloading and excessive transfer of stress to the unresurfaced compartment leading to joint degeneration though the group at Oxford has not observed this phenomenon in their series.

UNICOMPARTMENTAL KNEE ARTHROPLASTY Vs HIGH TIBIAL OSTEOTOMY AND TOTAL KNEE ARTHROPLASTY

During a validation process[33] of the Swedish arthroplasty register living registered patients were sent a questionnaire to find whether they have been reoperated and they are satisfied with the procedure or not. It was found that in osteoarthritis the procedures with the highest amount of satisfaction level were TKA and medial UKA. Patients with bilateral and lateral UKA were more unsatisfied. A higher proportion of revision patients were unsatisfied in TKA group compared with UKA group.

Bruce Rouggraff [34]et al compared a group of 120 UKA patients with 81 patients undergoing TKA. The mean follow-up was 78 and 68 months respectively. The knee society scores in the UKA group were significantly better than patients with TKA. The need for postoperative transfusion was significantly more in TKA patients. A study done by Laurencin[35] et al compared UKA and TKA in the same patient with an average follow up period of 81 months. The TKA patients were divided into 2 groups on the basis of patellar resurfacing. Ninety six percent of UKA patients had mild or no pain compared with 83% of the TKA patients. Forty four percent of the patients said that UKA was their better knee, 12% said that TKR was their better knee and 44% could not tell the difference. This proportion improved in the TKA subgroup with unresurfaced patella. Newman et al in a prospective study demonstrated better clinical results and greater range of motion in the UKA group compared with the TKA group[36].

The issue of doing a high tibial osteotomy or UKA often ignites discussion among the orthopedic group. Naudie et al showed a 51% survivorship of high tibial osteotomy at 10 years follow-up[37]. Broughton[38] et al analyzed a group of patients with single compartment arthritis 49 of whom had high tibia osteotomy and 42 had St. Georg Sled UKA. The UKA group was slightly older compared to the HTO group otherwise the both group were similar in characteristics. The results at 5-10 years followup showed that UKA group performed much better than the HTO group, the results were good in 76% of UKA patients Compared with 43% of HTO patients. Only 7% of UKA patients underwent revision procedures compared with 20% of the osteotomy group. The number of complications encountered in the osteotomy group was also higher. Adrian Weale[39] et al in 1991 published a 12-17 years follow up of same group of patients, with good results in 42% of the UKA group and 21% of the osteotomy. At the latest follow-up 5 knees in UKA group compared with 17 knees in the osteotomy group had undergone Revision. The UKA group had 80% of patients with no or mild pain compared to 43% of osteotomy patients.

Ivarsson[40] et al reported faster rehabilitation after UKA compared with HTO. The muscle torque also improved earlier than HTO group, additionally there was increase in maximal gait velocity and the duration of single support in UKA group.

RESULTS OF REVISION AFTER UKA

The common causes of failure in the early implants was aseptic loosening, wear of the thin polyethylene, poor bone coverage and implant subsidence with the inlay designs, cement fragmentation and osteolysis. The amount of bone loss encountered at the time revision of UKA depends on the amount of bone resected at the index procedure, bone loss cause by the implant failure and during removal of the implant. Secondly delayed revisions can also lead

to continued bone loss making the procedure more complicated. Early designs of femoral components had a narrow coronal plane dimensions leading to subsidence and large fixation legs and spikes leading to excess bone loss during removal. Because of these reasons the early reports of revision of UKA by Insall[41] and Scott[42] described frequent technical difficulties, including the need for bone grafting and use of revision stemmed and custom implants in as high as 50-76% of patients. The greatest bone loss was caused by the failure of the components and during their removal. With the advent of the modern designs of UKA there have been a few reports which describe good results. Chakraborty[43] et al analyzed results in a series of revision of UKA consisting mainly of St. Georg sled and PCA implants. They had to employ quadriceps turn down and tibial tubercle osteotomy in three of the knees due to difficult exposure and stiffness. They reported that they encountered major bone defects in only 22% of the cases. They used primary knee implants except in two cases where stemmed components were used but primarily for ligamentous instability. They used cement and bone graft for reconstruction. The average tibial insert thickness used was 11.5 mm. At average follow-up of 56 months there are excellent results in 79%, fair 11% and poor 10%. There have been two re-revision in this group.

James McAuley[44] reported on 32 UKA in 30 patients. The predominant cause of failure was polyethylene wear and loosening. The mean thickness of failed polyethylene insert was 7.3mm. The authors described the revision procedures to be straight forward. Levine[45] at al similarly did not find the revision of unicompartmental arthroplasty complicated. They also report high knee scores. Palmer[46] and Bert[47] also did not require any bone grafting and used primary TKA implants without wedges for his revisions of UKA in his series.

Lewold [48]et al analyzed results of revision of 1,135 of 14,772 primary unicompartmental knee arthroplasties (UKA) done by the end of 1995 in the Swedish registry. Two hundred and thirty two revisions were performed as an exchange UKA (partial in 97) and 750 as a total knee arthroplasty (TKA). One hundred and fifty three were revised by other modes. In medial UKA, the indication for revision was component loosening in 45% and joint degeneration in 25% and in lateral UKA, the corresponding figures were 31% and 35%, respectively. In 94 cases, unicompartmental components were added to the initially untreated compartment, in 14 with partial exchange of a component. After only 5 years, the risk of having a second revision was more than three times higher for failed UKAs revised to a new UKA (cumulative rerevision rate CRRR 26%) than for those revised to a TKA (CRRR 7%). This difference remained, even if those revised before 1985, when modern operating technique was introduced, were excluded (CRRR 31% and 5%, respectively).On failure of UKA it should be revised to a TKR in most modes of failure. Not even joint degeneration of the unoperated compartment can be safely treated by adding contralateral components; CRRR after this procedure was 17%, while it was 7% when converted to a TKA.

MINIMALLY INVASIVE UKA - IS THERE A ROLE?

Traditionally the successful outcome of any knee arthroplasty was measured by the implant longevity and low revision rate with less emphasis on the size of the incision. The Mini-Incision or Minimally invasive surgery (MIS) concept is based on the premise that a patient spends less time in the hospital, returns to function more quickly, has less pain and uses assistive devises for a shorter duration of time without compromising the long term outcome. Interest in Minimally Invasive Surgery (MIS) among the Orthopaedic community and patients has lead to the investigation of the role of minimally invasive unicompartmental Arthroplasty. Minimally invasive technique decreases tissue dissection, prevents dislocation of the patella, preserves the suprapatellar pouch, maintains the integrity of the quadriceps mechanism. The routine UKA approach

resembles the TKA approach which requires splitting the quadriceps tendon and dislocation of the patella. This leads to disruption of the suprapatellar pouch which requires extensive physiotherapy to reverse the iatrogenic damage and regain motion at the knee.

Minimally invasive approach to the knee for UKA involves a short medial or lateral incision approximately 8-10cms in size starting from the superior pole of the patella and continues about 2 cms distal to the tibial joint line. A short arthrotomy is made on the corresponding side (Figure IV). Flexion and extension balancing should be achieved without extensive ligament release. John Repicci[49,10] advocates doing an arthroscopy before the skin incision and determining the status of cartilage the opposite compartment and its meniscus, so the option of TKR is always left open if there is unexpected opposite compartment arthritis or meniscus damage. Alfred Tria[50] considers the short incision enough to inspect the joint. Engh reviewed the challenges of using minimally invasive techniques. They include the following: the difficulty of evaluating the opposite compartment and patellofemoral joint, the inability to use intramedullary devices for alignment, difficulty balancing soft tissues. He recommended that before surgeons begin performing minimally invasive procedures, they become comfortable with open unicompartmental replacements.

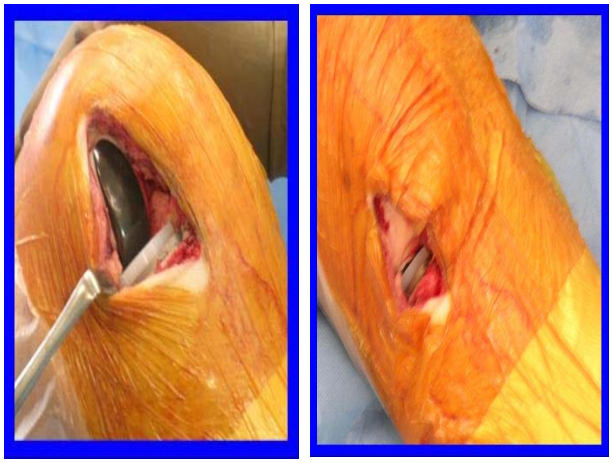

Figure-IV: MIS unicompartmental arthroplasty showing adequate exposure without eversion of the patella. The First Picture shows the knee in flexion. The second picture shows the incision size on extension of the knee.

It has been advocated by few authors[51] that minimally invasive techniques in UKA are associated with shortened hospital stay, rapid recovery and early rehabilitation. In a retrospective study[10] all patients ambulated with walker 4 hours postoperatively and most (>98%) were discharged from hospital within 23 hours. The authors of that series recommend discharging the patient on a walker 4-6 hours postoperatively. They recommended injecting local anesthesia in all incised areas before closure which also decreases the requirement for narcotic analgesia postoperatively.

Repicci[10] et al reported on 136 UKA with 8 years follow-up employing MIS technique. He reported 86% good or excellent results at 8 years using Knee Society scoring system. Average Range of motion at 8 years was 4 ^{o} to 117°. Ahlback stage 2 and 3 patients had 4% revision rate and Ahlback stage 4 had 25% revision rate at 8 years. Alfred Tria[50] has also reported encouraging early results with his MIS unicompartmental arthroplasty series.

Price[52] et al compared 40 Oxford UKA done with minimally invasive technique with UKA and total knee arthroplasty procedures done with open approach. The time of recovery of MIS knees was twice as fast as the open UKA and thrice as fast as the open TKR. Eleven variables were used to assess the implant position in all cases. Accuracy of implant positioning achieved by MIS techniques was comparable to the open approach.

Due to the limited exposure one of the concerns might be the risk of implant malposition in MIS unicompartmental arthroplasty. Peter Muller[53] et al conducted a study using standard open and MIS techniques for Oxford meniscal bearing UKA. The prosthesis used in open surgeries was Oxford Phase II and in MIS procedures was the Oxford Phase III. An incision of 8 cms was employed for MIS knees. On measurement of various variables regarding implant positioning in postoperative x-rays they found that Minimal invasive technique group scored high in 14 of the 17 measured parameters. The HSS score was significantly

high in the MIS group. The range of motion was better in the MIS group (113° vs. 107°) but the differences were not significant. The number of patients with extension lag was also significantly higher in the open technique group. The authors attributed decreased tissue dissection rather than dissimilarity of prosthesis design as a difference in postoperative results of patients.

Graham Keys[54] et al compared a group of minimally invasive UKA with UKA performed with routine approach requiring eversion of the patella. With minimally invasive approach straight leg raising was achieved in two days. Flexion to 90° was achieved in all patients by day 3. All patients could climb stairs by day 5. The patients with the routine approach achieved all these goals 3 days later than the minimally invasive approach group. At three months achievement of both groups was similar. No problems were detected on cementing or positioning of implants in both groups on radiographs. No patient required blood transfusion in the minimally invasive group but two patients in the other group required blood transfusion.

KY Yang[55] et al compared two groups one undergoing UKA with the reduced invasive approach and the other had TKA done with cruciate retaining prosthesis using the routine exposure. The UKA and TKA group were well matched with regard to age, grade of arthritis (Ahlback II or III) preoperative hemoglobin and preoperative ROM. Analysis showed that UKA had regained independent ambulation earlier, had lower drainage, lower fall of postoperative hemoglobin, increased ROM at the knee at 6 months, decreased duration and cost of hospital stay compared with the TKA group, all these differences were statistically significant ($p<0.01$). No patient in the UKA group received blood transfusion compared to two patients in the TKA group. One patient each in the TKA group had a DVT and pneumonia.

Regardless of the encouraging results with MIS Unicompartmental knee arthroplasty it is a technically demanding procedure and requires adequate surgical experience to prevent complications and implant malpositioning. J.L. Rees[56] et al in short term follow up of the first 104 Oxford Knees performed with the MIS technique by a group of surgeons found that the average knee score improved from 37 to 94 points and the average functional score from 50 to 92. The average knee score during a surgeon's first ten cases was 88 points which was significantly low compared to scores achieved in the subsequent procedures (95 points).

COMPLICATIONS

The complications inherent in Unicompartmental Arthroplasty include all the problems associated with TKA with the exception of Patellofemoral implant related problems. Sepsis in UKA has been reported less frequently than the Total Knee Arthroplasty, being about less than 1%. Subsidence of the femoral and tibial components was another complication reported frequently in few of the early series. The mediolateral dimensions of the femoral implant in few earlier designs were quite narrow leading to subsidence. The tibial designs were also used as an inlay prosthesis which had a higher subsidence rate. Currently most designs use on lay tibial components supported by the strong cortical rim of proximal tibia. Overcorrection of the deformity, can lead to increased stress and wear of the cartilage of the unresurfaced tibiofemoral compartment (Figure V) whereas excessive under correction

Figure-V: Overcorrection of the deformity, leading to excessive stress and cartilage degeneration in the lateral compartment.

might lead to increased wear of the polyethylene[57]. So most of the authors have consensus on keeping the knee in slight under correction and ligament releases are not recommended in UKA. Chandler[58] et al recommends leaving a laxity of about 2mm in the replaced compartment throughout the range of motion. A E Weale[59] et al have suggested that degeneration of the unresurfaced compartment may be due to damage produced by the wear from the polyethylene. Toshihiro[60] et al also recommended keeping the valgus knees slightly under corrected after UKA and proposed a postoperative valgus alignment of 5-7° to balance the forces in both compartments. O.H. Khan[61] reported a rate of 10% of radiological progression of arthritis in the remaining unresurfaced compartment at 10 years of follow-up. They overcorrection of deformity was deliberately avoided. The authors labeled these arthritic changes as minor. No patient required revision for progressive arthritis.

Another complication of UKA is increased wear of the polyethylene. The various reasons of excessive polyethylene wear can be decreased thickness of the polyethylene, sterilization with Gamma radiation in air, malalignment of the limb and defective fixation of the polyethylene to tibial metal base plate in metal backed components. Polyethylene mechanical toughness dramatically decreases with increasing shelf life if the tibial polyethylene is sterilized with Gamma radiation in air. The polyethylene gets oxidized and free oxygen radicals are generated which tend to decrease mechanical strength and cause delamination and increased wear of the polyethylene[62]. Another study[63] showed a six year survival rate of the 96% when the shelf life of the polyethylene was less than 1.7 years compared with 71% when it exceeded 1.7 years. It is recommended that surgeon be aware of mode of sterilization of the polyethylene.

Psychoyios[64] et al suggested that increased congruence and mobile bearing characteristics of the Oxford UKA causes minimal wear leading to decreased wear of the polyethylene independent of the polyethylene thickness. The average polyethylene wear on upper and lower surfaces of the Oxford polyethylene bearing was 0.036mm per year but in the inserts which had impingement the wear was greater.

The most common mode of failure in knee arthroplasty is aseptic loosening of the tibial component. From 1975 to 1995, the Swedish knee arthroplasty register[65] recorded 14,772 unicompartmental arthroplasties for arthrosis. 1,135 of the primary arthroplasties were revised. In medial unicompartmental arthroplasties, indication for revision was component loosening in 45% and joint degeneration in 25%; in lateral unicompartmental arthroplasties, it was 31% and 34%, respectively. Early designs were constrained which lead to excessive force transmission to the bone and cement-implant interface. Chandler[58] et al in a study demonstrated significantly improved results and decreased revision rates with unconstrained UKA compared with the constrained designs. Later on less constrained designs were introduced. Unfortunately this instead introduced new modes of failure, namely excessive delamination wear of the tibial component because of higher point contact stress, as well as abrasion during the sliding and roll-back of the femoral component on the tibial plastic surface[66]. Cold flow and creep are few other causes of loosening of all polyethylene components leading to their deformation and allowing micromotion due to breakup at cement-bone interface. Introduction of metal backing to reduce cold flow has also not solved the problem. Aseptic loosening still remains the major cause of failure.

The Oxford UKA employs a meniscal bearing unconstrained, fully congruent mobile bearing which is analogous to the natural meniscus. When used on the medial side[8] the Oxford UKA has a dislocation rate about 1%. When used on the lateral side the same group[67] at Oxford has reported a dislocation rate of more than 11% (6 of 53 Knees). The authors have mentioned reasons like different kinematics and anatomy of the lateral side of the knee compared to the medial side, more laxity of the ligaments on the lateral side and the

bowstringing of the popliteus tendon pushing the bearing to dislocate. In another study[68] on analysis of radiographs of the same group difference noted between the dislocated and non dislocated group was proximal tibial varus angle. If this angle was greater or equal to 8° the chances of dislocation were 40%. If the angle was <8° the chances of dislocation were 4%.

One of the complications of UKA is the impingement of anterior edge of femoral Component on Patella[69]. More than 10° of extension leads to anterior placement of the femoral component and patellar impingement (Figure VI). Different anatomy of the femoral condyles and similar implants for them and the excessive resection of the posterior femoral condyle can be few of the other reasons for patellofemoral Impingement.

Figure-VI: Impingement of the Anterior Edge of the Femoral Component on the Patella.

One of the other complications which are very rare is fracture of the tibial condyle. It can occur intraoperatively[70] as well as present later as stress fracture[71]. Few reasons responsible for it could be a very thick resection of the condyle leading to weakness of the condyle or the pin holes used for anchorage of instrumentation leading to stress fracture later in the course of treatment.

In minimally invasive surgery the space to operate and inspect the joint after implantation of the components is quite small which can lead to retention of cement especially in the posterior portion. The all polyethylene tibia further adds to this difficulty of posterior visualization. It is recommended to achieve satisfactory clearance of the posterior compartment using instruments like nerve hooks or dental mirrors. In case loose cement fragment is detected postoperatively it can be removed arthroscopically[72].

CONCLUSION

There is definitely a renewed interest in Unicompartmental arthroplasty because of its more physiologic nature, good results, improved proprioception, decreased cost and faster recovery with a decreased morbidity than a TKA or a HTO. The success of the procedure depends on strict patient selection, meticulous surgical technique and proper implant selection. The sedentary patient with unicompartmental arthritis is currently the primary indication for UKA. One question which still remains unanswered in the current literature is the role of UKA in younger patients. High tibial Osteotomy still remains the best option in a patient involved in manual labor and impact sports. The revision following UKA usually is uncomplicated, usually not requiring revision components. The concept of minimally invasive Unicompartmental arthroplasty is definitely exciting but requires more long term studies to support its role. UKA especially minimally invasive UKA is a technically demanding procedure. Surgeons not familiar with this technique will benefit from appropriate preoperative instruction.

REFERENCES

1. Berger RA, Nedeff DD, Barden RM, Sheinkop MM, Jacobs JJ, Rosenberg AG. Unicompartmental knee arthroplasty. Clinical experience at 6 to 10 year followup. Clin Orthop 1999; 367:50-60.
2. Insall J, Walker P. Unicondylar knee replacement. Clin Orthop 1976;120:83-5.
3. Insall J, Aglietti P. A five to seven-year follow-up of unicondylar arthroplasty. J Bone Joint SurgAm 1980;62(8):1329-37.
4. Laskin RS. Unicompartmental tibiofemoral resurfacing arthroplasty. J Bone Joint Surg Am 1978;60(2):182-5.

5. Lindstrand A, Stenström A, Lewold S. Multicenter study of unicompartmental knee revision. PCA, Marmor, and St Georg compared in 3,777 cases of arthrosis. Acta Orthop Scand 1992; 63(3): 256-9.
6. Lewold S, Knutson K, Lidgren L. Reduced failure rate in knee prosthetic surgery with improved implantation technique. Clin Orthop 1993; (287): 94-7.
7. Chakrabarty G, Newman JH, Ackroyd CE. Importance of choosing the right prosthesis: The Bristol experience of the PCA prosthesis. The Knee 1997;4:167-9.
8. Murray DW, Goodfellow JW, O'Connor JJ. The Oxford medial unicompartmental arthroplasty: a ten-year survival study. J Bone Joint Surg Br 1998; 80(6): 983-9.
9. Marcus R, Romanoski , John A. Repicci. Minimally invasive Unicondylar arthroplasty in the Post-Menisectomy Knee: Repicci Knee. Sports Medicine and arthroscopy review 2002;10:253-9.
10. Hendel D, Beloosesky Y, Garti A, Weisbort M. Medial unicompartmental replacement for tricompartmental disease in the elderly. Knee 2003;10(4):363-5.
11. Ackroyd CE. Medial compartment arthroplasty of the knee. J Bone Joint Surg Br 2003;85(7):937-42.
12. Kozinn SC, Scott R. Unicondylar knee arthroplasty. J Bone Joint Surg Am 1989;71(1):145-50.
13. Goodfellow J, O'Connor J. The anterior cruciate ligament in knee arthroplasty. A risk-factor with unconstrained meniscal prostheses. Clin Ortho 1992; (276):245-52.
14. Robertsson O. ,Unicompartmental arthroplasty. Results in Sweden 1986–1995. Orthopade 2000;29:S6–8.
15. Rees JL, Price AJ, Lynskey TG, Svard UC, Dodd CA, Murray DW. Medial unicompartmental arthroplasty after failed high tibial osteotomy. J Bone Joint Surg Br 2001;83(7):1034-6.
16. Ritter MA, Faris PM, Thong AE, Davis KE, Meding JB, Berend ME. Intra-operative findings in varus osteoarthritis of the knee. An analysis of pre- operative alignment in potential candidates for unicompartmental arthroplasty. J Bone Joint Surg Br 2004; 86 (1):43-7.
17. Stern SH, Becker MW, Insall JN. Unicondylar knee arthroplasty. An evaluation of selection criteria. Clin Orthop. 1993;286:143-8.
18. Marmor L. The modular knee. Clin Orthop 1973; 94:242-8.
19. Antoniou J, Hadjipavlou A, Enker P, Antoniou A. Unicompartmental knee arthroplasty with patelloplasty. Int Orthop 1996;20(2):94-9.
20. Marmor L. Unicompartmental knee arthroplasty. Ten to 13-year follow-up study. Clin Orthop 1988; 294:14–20.
21. Engelbrecht E, Siegel A, Rottger J, et al. Statistics of total knee replacement: partial and total knee replacement, design St. Georg: a review of a 4-year observation. Clin Orthop 1976; 120:54–64.
22. Goodfellow J, O'Connor J. The mechanics of the knee and prosthesis design. J Bone Joint Surg Br 1978; 60:358–369.
23. Murray DW. Unicompartmental knee replacement. Paper presented at: Canadian Orthopaedic Association Annual Meeting, London, Ontario, June 1–4, 2001.
24. Psychoyios V, Crawford RW, O'Connor JJ, et al. Wear of congruent meniscal bearings in unicompartmental knee arthroplasty: a retrieval study of 16 specimens. J Bone Joint Surg Br 1998; 80:976–82.
25. Barnes CL, Scott RD. Unicompartmental knee arthroplasty. Instr Course Lect 1993; 42:309–14.
26. Hyldahl HC, Regnér L, Carlsson L, Johan Kärrholm, Weidenhielm L. Does metal backing improve fixation of tibial component in unicondylar knee arthroplasty? A randomized radiostereometric analysis . J Arthrosplasty 2001; 16(2):174 9.
27. Marmor, Leonard. Unicompartmental arthroplasty. Ten to 13 year follow-up study. Clin Orthop 1988; 226:14-20.
28. Svard UC, Price AJ. Oxford medial unicompartmental knee arthroplasty. A survival analysis of an independent series. J Bone Joint Surg Br 2001; 83:191–4.
29. Lewold S, Goodman S, Knutson K, Robertsson O, Lidgren. Oxford meniscal bearing knee versus the Marmor knee in unicompartmental arthroplasty for arthrosis. A Swedish multicenter survival study. J Arthroplasty 1995; 10(6): 722-31.
30. Robertsson O, Knutson K, Lewold S, Lidgren L. The Swedish Knee Arthroplasty Register 1975-1997: an update with special emphasis on 41,223 knees operated on in 1988-1997. Acta Orthop Scand 2001; 72(5):503-13.
31. Squire MW, Callaghan JJ, Goetz DD, Sullivan PM, Johnston R C. Unicompartmental Knee Replacement: A Minimum 15 Year Followup Study. Clin Orthop 1999;1(367):61-72.
32. Ashraf T, Newman JH, Evans RL, Ackroyd CE. Lateral unicompartmental knee replacement survivorship and clinical experience over 21 years. J Bone Joint Surg Br 2002; 84(8):1126-30.
33. Robertsson O, MJ Dunbar, K Knutson & L Lidgren: Patient satisfaction after knee arthroplasty: a report on 27,372 knees operated on between 1981 and 1995 in Sweden. Acta Orthop Scand 2000;71(3):262-7.
34. Rougraff BT, Heck DA, Gibson AE. A comparison of tricompartmental and unicompartmental arthroplasty for the treatment of gonarthrosis. Clin Orthop 1991; 273: 157-64.
35. Laurencin CT, Zelicof SB, Scott RD: Unicompartmental versus total knee arthroplasty in the same patient. A comparative study. Clin Orthop 1991; 273: 151-6.
36. Newman JH, Ackroyd CE, Shah NA. Unicompartmental or total knee replacement? Five-year results of a prospective, randomised trial of 102 osteoarthritic knees with unicompartmental arthritis. J Bone Joint Surg Br 1998;80(5):862.
37. Naudie D, Bourne RB, Rorabeck CH, Bourne TJ.The Install Award. Survivorship of the high tibial valgus osteotomy. A 10 to 22-year followup study. Clin Orthop 1999;(367): 18-27.
38. Broughton NS, Newman JH, Baily RA. Unicompartmental replacement and high tibial osteotomy for osteoarthritis of the knee. A comparative study after 5-10 years' follow-up. J Bone Joint Surg Br 1986; 68(3): 447-52.
39. Weale AE, Newman JH. Unicompartmental arthroplasty and high tibial osteotomy for osteoarthrosis of the knee. A comparative study with a 12- to 17-year follow-up period. Clin Orthop 1994; 302: 134-7.

40. Ingemar Ivarsson and Jan Gillquist . Rehabilitation after high tibial osteotomy and unicompartmental arthroplasty. A Comparative study. Clin Orthop 1991; 266: 139-44
41. Padgett DE, Stern SH, Insall JN.Revision total knee arthroplasty for failed unicompartmental replacement. J Bone Joint Surg Am 1991;73(2):186-90.
42. Barrett WP, Scott RD. Revision of failed unicondylar unicompartmental knee arthroplasty. J Bone Joint SurgAm 1987;69(9):1328-35.
43. Chakrabarty G, Newman JH, Ackroyd CE. Revision of unicompartmental arthroplasty of the knee. Clinical and technical considerations. J Arthroplasty 1998;13(2):191-6.
44. McAuley JP, Engh GA, Ammeen DJ. Revision of failed unicompartmental knee arthroplasty. Clin Orthop 2001; 392:279–82.
45. Levine WN, Ozuna RM, Scott RD. Conversion of failed modern unicompartmental arthroplasty or high tibial osteotomy. Clin Orthop 1995; 321: 10-18.
46. Palmer SH, Morrison PJ, Ross AC. Early catastrophic tibial component wear after unicompartmental knee arthroplasty. Clin Orthop 1998;350:143-8.
47. Jack M Bert. 10 Year Survivorship of Metal-Backed Unicompartmental Arthroplasty. J Arthroplasty 1998; 13(8)901-5
48. Lewold S, O Robertsson, K Knutson & L Lidgren. Revision of unicompartmental knee arthroplasty: outcome in 1, 135 cases from the Swedish Knee Arthroplasty study. Acta Orthop Scand 1998; 69(5): 469-74.
49. Repicci JA. Minimally invasive surgical technique for unicondylar knee arthroplasty. Journal of the Southern Orthopedic Association 1999; 8: 20–7.
50. Alfred J Tria Jr. Minimally invasive unicompartmental Knee arthroplasty. Techniques in Knee Surgery 2002;1(1):60-71.
51. Romanowski MR, Repicci JA. Minimally invasive unicondylar arthroplasty. Eight-year follow-up. Am J Knee Surg 2002;15(1):17-22.
52. Price AJ, Webb J, Topf H, et al. Rapid recovery after oxford unicompartmental arthroplasty through a short incision. J Arthroplasty 2001; 16:970–6.
53. Muller PE, Pellengahr C, Witt M, Kircher J, Refior HJ, Jansson V. Influence of minimally invasive surgery on implant positioning and the functional outcome for medial unicompartmental knee arthroplasty. J Arthroplasty 2004;19(3): 296-301.
54. G W Keys. Reduced invasive approach for oxford II medial unicompartmental knee replacement a preliminary study. The Knee 1999;6:193-6.
55. Yang KY, Wang MC, Yeo SJ, Lo NN. Minimally invasive unicondylar versus total condylar knee arthroplasty-early results of a matched-pair comparison. Singapore Med J 2003; 44(11):559-62.
56. Rees JL, Price AJ, Beard DJ, Dodd CA, Murray DW. Minimally invasive Oxford unicompartmental knee arthroplasty: functional results at 1 year and the effect of surgical inexperience. Knee 2004;11(5): 363-7.
57. Hernigou P, Deschamps G .Alignment influences wear in the knee after medial unicompartmental arthroplasty. Clin Orthop 2004;423:161-5.
58. Hodge WA, Chandler HP. Unicompartmental knee replacement: A comparison of constrained and unconstrained designs. J Bone Joint Surg Am 1992; (74-A)6: 877-83.
59. Weale AE, Murray DW, Crawford R, Psychoyios V, Bonomo A, Howell G, Does arthritis progress in the retained compartments after 'Oxford' medial unicompartmental arthroplasty? A clinical and radiological study with a minimum ten-year follow-up. J Bone Joint Surg Br 1999;81(5):783-9.
60. Ohdera T, Tokunaga J, Kobayashi A. Unicompartmental knee arthroplasty for lateral gonarthrosis: midterm results. J Arthroplasty 2001; 16(2):196-200.
61. Khan OH, Davies H, Newman JH, Weale AE. Radiological Changes ten years after St. Georg Sled Unicompartmental Knee replacement. The Knee 2004;11:403-7.
62. Thomas F McGovern, Deborah J Ammeen, John P Collier, Barbara H. Currier & Gerard A Engh . Rapid Polyethylene Failure of Unicondylar Tibial Components Sterilized with Gamma Irradiation in Air and Implanted After a Long Shelf Life. J Bone Joint Surg Am 2002; 84: 901–6.
63. Matthew B. Collier, C. Anderson Engh, Jr., and Gerard A. Engh. Shelf Age of the Polyethylene Tibial Component and Outcome of Unicondylar Knee Arthroplasty. J Bone Joint Surg Am 2004; 86: 763–69.
64. Psychoyios V, Crawford RW, O'Connor JJ. Wear of congruent meniscal bearings in unicompartmental knee arthroplasty: a retrieval study of 16 specimens. J Bone Joint Surg Br 1998; 80(6): 976-82.
65. Lewold S, O Robertsson, K Knutson & L Lidgren. Revision of unicompartmental knee arthroplasty: outcome in 1,135 cases from the Swedish Knee Arthroplasty study. Acta Orthop Scand 1998;69(5): 469-74.
66. Blunn G W, Joshi AB, Minns RJ, Lidgren L, Lilley P, Ryd L, Wear in retrieved condylar knee arthroplasties. A comparison of wear in different designs of 280 retrieved condylar knee prostheses. J Arthroplasty 1997; 12: 281-90.
67. Gunther T, Murray DW, Miller R: Lateral unicompartmental arthroplasty with the Oxford meniscal knee. The Knee 1996; 3: 33-9.
68. Robinson BJ, Rees JL, Price AJ, Beard DJ, Murray DW, McLardy Smith P, Dodd CA. Dislocation of the bearing of the Oxford lateral unicompartmental arthroplasty. A radiological assessment. J Bone Joint Surg Br 2002;84(5):653-7.
69. P. Hernigou and G. Deschamps. Patellar Impingement Following Unicompartmental Arthroplasty. J Bone Joint Surg Am 2002; 84: 1132–7.
70. Sloper PJ, Hing CB, Donell ST, Glasgow MM. Intraoperative tibial plateau fracture during unicompartmental knee replacement: a case report. The Knee 2003;10(4):367-9.
71. Brumby SA, Carrington R, Zayontz S, Reish T, Scott RD. Tibial plateau stress fracture: a complication of unicompartmental knee arthroplasty using 4 guide pinholes. J Arthroplasty 2003;18(6):809-12.
72. David J Howe, David Taunton O Jr. & Gerard A Engh. Retained Cement After Unicondylar Knee Arthroplasty. A Report of Four Cases. J Bone Joint Surg Am. 2004; 86: 2283-6.