Case Report

BRUCELLAR SPONDYLODISCITIS IN THE CERVICAL REGION

Omer Evirgen[1], Murat Altas[2], Ramazan Davran[3], Vicdan Koksaldi Motor[4], Yusuf Onlen[5]

ABSTRACT

Diagnosis of brucella infection may be difficult, because it can mimic many other diseases. We report a 57-year old man who had presented with the complaints of radiculopathy, and was diagnosed as cervical spondylodiscitis. The spondylodiscitis was diagnosed via rose bengal test, positive serology, and positive culture results after the initial suspicion with magnetic resonance imaging. Streptomycin for 14 days and doxycycline rifampicin for tree months were used for the treatment. Brucellar spondylodiscitis in the cervical region is a rare presentation, beside that prognosis with early diagnosis and adequate treatment is good.

KEY WORDS: Brucellosis, Spondylodiscitis, Cervical Vertebrae.

Pak J Med Sci July - September 2010 Vol. 26 No. 3 720-723

How to cite this article:

Evirgen O, Altas M, Davran R, Motor VK, Onlen Y. Brucellar spondylodiscitis in the cervical region. Pak J Med Sci 2010;26(3):720-723

1. Omer Evirgen, MD,
Assistant Professor,
Dept. of Infectious Diseases and Clinical Microbiology
2. Murat Altas, MD,
Assistant Professor,
Department of Neurosurgery
3. Ramazan Davran, MD,
Assistant Professor,
Department of Radiology
4. Vicdan Koksaldi Motor, MD,
Assistant Professor,
Dept. of Infectious Diseases and Clinical Microbiology
5. Yusuf Onlen, MD,
Associated Professor,
Dept. of Infectious Diseases and Clinical Microbiology
1-5. School of Medicine,
Mustafa Kemal University,
Hatay, Turkey.

Correspondence:

Dr. Omer Evirgen,
Department of Infectious Diseases and
Clinical Microbiology,
School of Medicine,
Mustafa Kemal University,
31120, Hatay,
TURKEY.
E-mail: omerevirgen@gmail.com

* Received for Publication: December 4, 2009

* Accepted: April 12, 2010

INTRODUCTION

Brucellosis is one of the most frequently seen bacterial zoonotic disease worldwide.[1] Although it is eradicated in many countries such as Canada, Australia, New Zealand, UK and in many Northern European countries, it is observed as hyper-endemic in many other countries such as Mediterranean reservoir, Arabian Peninsula, India, Mexico and Middle and Southern America.[1,2] Brucellosis is a systemic infection where any organs of the body may get involved. The condition mimics several diseases and therefore can be difficult to diagnose. Frequency of osteoarticular complications is about 10-80% and it may lead especially to spondylodiscitis and sacroilitis in adults and elderly patients.[3] In the present case we will discuss the cervical region involvement in brucellosis.

CASE PRESENTATION

The patient was a 57 year-old male and had complaints related with neck pain which extends towards his right arm and causes

numbness. The patient experienced a slight fever and night sweats episodes for the last three months. There are no other specific conditions of the patient in his medical background. The patient is not involved with livestock breeding, but his story is related with consumption of fresh cheese made from raw milk was positive. His pain seemed to decrease after using anti-inflammatory drugs, being more intense in the evenings.

At physical examination, temperature was 37.1°C and movements in the right upper extremity and neck were painful. Pain and sensitivity was present at the cervical region with palpation. There was 1/5 strength loss in flexion of the right arm, and hypoesthesia was present at the dermal region that corresponds to the right C5-6 dermatome area. Pathological reflexes were absent. Deep tendon reflexes (DTR) were normoactive. No pathological finding was encountered in the examination of the lower extremities.

According to first lab findings, the erythrocyte sedimentation rate (ESR) was 45 mm/h (2-20) and the C-reactive protein (CRP) was 41 mg/L (0-5). ASO (antistreptolysin-O antibody), RF (Rheumatoid Factor) and tuberculin skin test were negative. Rose-Bengal was strongly positive and Standard Tube Agglutination Testing (SAT) were positive at 1/1280 titration. C5 and C6 vertebral corpus heights were reduced at the cervical region radiogram, significantly at C5 and the distance of the C5-6 intervertebral disc was narrowed (Fig-I). MRI study of the cervical region displayed findings compatible with spondylodiscitis (Fig-II). *B. melitens*is was grown in the blood culture. Based on these findings, the patient was diagnosed with Brucella-induced spondylodiscitis and therapeutical therapy was initiated by the administration of streptomycin (1 g/day, IM) and doxycyline (200 mg/day, PO). Streptomycin was stopped two weeks after and the treatment was continued with doxycycline and rifampicin (600 mg/day, PO) for another ten weeks to complete the three months period.

Starting from the 4th week of the therapy, patient stated that his pain had diminished and control lab tests ESR was 25 mm/h (2-20) and CRP was 8 mg/L (0-5). A control MRI could not be obtained from the patient, but his neurological symptoms improved at week six and his neurological findings were completely recovered at the end of therapy.

DISCUSSION

Brucellosis commonly comes in sight with musculoskeletal system findings. Spondylitis is one of the most frequent and significant involvements. However, involvements related to musculoskeletal system may vary with respect to age. Peripheral arthritis, sacroiliitis and spondylitis is frequently seen in patients up to 45 years of age, while spondylitis is the most frequent finding in patients over 45.[4] Our patient was 57 years old and complies with this situation.

Fig-I: Cervical lateral plain graph: Lordosis is relatively preserved. However, vertebrae corpuses are reduced significantly at C5, heights of the C5 and C6 and the distance of C5-6 intervertebral disc is narrowed. Osteophytic changes can be noticed at vertebrae end-plates. Vertebra posterior elements and the uncovertebral joint distance are preserved.

Brucella-induced spondylodiscitis mostly affects the lumbar region and rarely the cervical region.[5,6] Cervical region involvement is a very rare condition and therefore diagnosis and treatment may be difficult. Late diagnosis may lead to surgical therapy in many patients with spondylodiscitis with cervical involvement.[6,7] Diagnosis can be managed if a scrutinized anamnesis is obtained. The occupation and residential site of the patient should be investigated in regions where brucellosis appears to be endemic. In our patient, we detected no occupational risks, but the patient was residing at a brucellosis endemic zone and he was consuming cheese made from raw milk (non-pasteurized) at a large extent. However, we suspected that he might have caught brucellosis and we managed to diagnose our patient at an early period. Therefore, no need was required for surgical intervention.

The differential diagnosis of Brucella-induced spondylitis should include traumas of the musculoskeletal system, osteoarthritis, intervertebral disk hernias, local or metastatic malignities and tuberculosis. Radicular pain of the patient may be confused with disc hernia.[8,9] In our patient, we considered a cervical disc hernia at the first sight as hypoesthesia was present at the region that complies with the C5-6 dermatome, but MR image displayed findings compatible with spondylodiscitis at the C5-6 level. The patient was diagnosed with Brucella-induced spondylodiscitis due to the positive results obtained from Brucella SAT, Rose-Bengal testing and culture and the negative result of the tuberculin skin test.

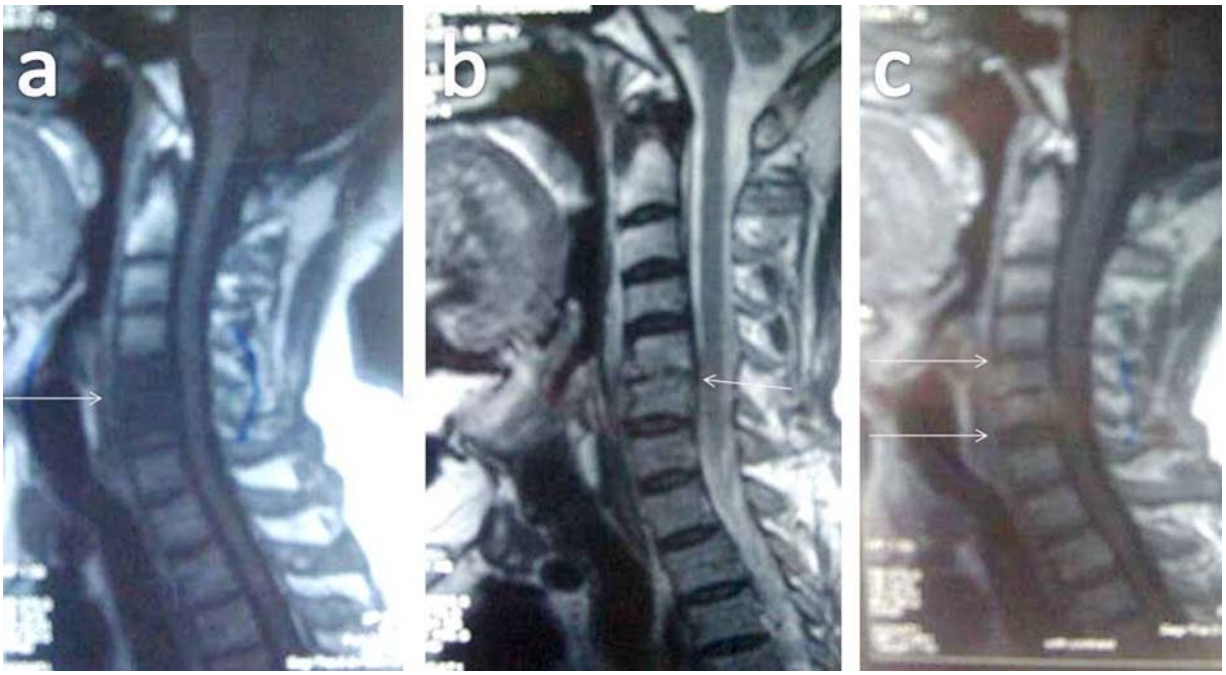

Fig-II:

(a) *T1 W images:* A decrease in the heights of C5 and C6 vertebrae corpuses and a narrowing in the disc distance (shown by an arrow) are noticed. Disc signal intensity and the intensities of the vertebrae corpus are lost. A minimal expansion was observed in the spinal cord at this location. The A-P distance of the spinal canal is narrowed.

(b) *T2 W images:* Cervical lordosis is preserved. The heights of the C5 and C6 vertebrae corpuses are reduced and osteophytic signal variations are noticed at the end-plate anterior. The distance of C5-6 intervertebral disc is considerably narrowed and an anterior hyperintense signal increase can be noticed especially in the disc of the patient with spondylodiscitis. At this level, a thickening is noticed at the posterior longitudinal ligament (PLL) and a moderate expansion is observed at the spinal cord. The A-P diameter of the spinal canal is narrowed.

(c) *In T1 W images:* A significant contrasting pattern can be observed at the C5-C6 vertebrae corpuses, inside the disc and at end-plates neighboring the disc (shown by an arrow). However, no any contrasting is observed at the spinal cord, but a PLL contrast involvement is noticed.

The definite diagnosis of brucellosis depends on the isolation of the bacteria in a culture medium. Nevertheless, bacterial isolation by culture may vary between 15-90%. When a bacteriological validation is not available, then high specific antibody titration is searched in the serum and serum agglutination test is widely used for this purpose. Titrations equal to 1/160 and above are admitted positive. Additionally, Rose Bengal test is also a very useful test. However, a titration cannot be determined by this test and therefore the test must be validated by SAT especially, in endemic zones.[3] In our patient, Rose-Bengal test was found positive, and SAT titer was 1/1280. Furthermore, *B. melitensis* was grown in the blood culture.

Although spinal radiography and computerized tomography provide detailed information of the condition, the principle findings that constitute a base for diagnosis of spondylodiscitis are those obtained by MRI. In general, at the early stage of radiography no findings may be noticed. However, an irregularity may be seen at the edge of the vertebrae corpuses after 2-4 weeks of the beginning of the condition and a narrowing in the distance of the intervertebral disc.[10,11] In our patient, we determined a decrease in the height of the vertebrae corpuses at C5-6 and a narrowing at the C5-6 intervertebral disc distance. In acute brucellosis-induced spondylodiscitis, MR imaging shows low signal intensity in T1-weighted images while a hyperintense appearance can be noticed at the regions adjacent to the intervertebral disc and the vertebrae corpuses. MRI also clearly shows the epidural extension of the inflammation and the involvement of the spinal cord.[10] In our patient, disc signal intensity and the intensities of the vertebrae corpuses could not be traced in T1-weighted images. In T2-weighted images, an increase was noticed in hyperintense signals especially at the anterior. Additionally, posterior longitudinal ligament was thickened and a moderate degree of expansion was observed at the spinal cord (Fig-II).

The prognosis of spondylodiscitis is usually good if an appropriate therapy is applied. Typically a combination that consists of streptomycin, doxycyline and rifampicin is administered. The duration of antibiotic therapy should be longer than systemic brucellosis. Generally, streptomycin is administered for a period of 14-21 days while doxycycline and rifampicin is administered for duration of 3-12 months. This period may vary according to the therapeutical response of the patient and the formation of epidural and paravertebral masses.[5,6] In our patient we administered a combination of antibiotics that included streptomycin, doxycyline and rifampicin. Streptomycin was stopped at day 14 and the treatment was continued with doxycycline and rifampicin to complete the three months period.

In conclusion, brucellosis may mimic the clinical features of many disorders. Brucellosis should exactly be borne in mind particularly at endemic areas where patients are presenting with cervical osteoarticular involvement.

REFERENCES

1. Pappas G, Papadimitriou P, Akritidis N, Christou L, Tsianos E. The new global map of human brucellosis. Lancet Infect Dis 2006;6(2):91-9.
2. Black TF. Brucellosis. In: Cohen J, Powderly WG, editors. Infectious diseases. 2nd ed. St. Louis: Mosby; 2004. p. 1665-7.
3. Young EJ. Brucella species. In: Mandell GL, Bennett JE, Dolin R, editors. Principles and Practice of infectious diseases. 6th ed. Philadelphia: Churchill Livingstone; 2005. p. 2669-72.
4. Gotuzzo E, Carrillo C. Brucella. In: Gorbach SL, Bartlett JG, Blacklow NR, editors. Infectious Diseases. 3rd ed. Philadelphia: Lippincott Williams & Wilkins 2004. p. 1717-24.
5. Solera J, Lozano E, Martinez-Alfaro E, Espinosa A, Castillejos ML, Abad L. Brucellar spondylitis: review of 35 cases and literature survey. Clin Infect Dis 1999;29(6):1440-9.
6. Bodur H, Erbay A, Colpan A, Akinci E. Brucellar spondylitis. Rheumatol Int 2004;24(4):221-6.
7. Turunc T, Demiroglu YZ, Uncu H, Colakoglu S, Arslan H. A comparative analysis of tuberculous, brucellar and pyogenic spontaneous spondylodiscitis patients. J Infect 2007;55(2):158-63.
8. Quinones-Hinojosa A, Jun P, Jacobs R, Rosenberg WS, Weinstein PR. General principles in the medical and surgical management of spinal infections: a multidisciplinary approach. Neurosurg Focus 2004;17(6):E1.
9. Turgut M, Cullu E, Sendur OF, Guyrer G. Brucellar spine infection—four case reports. Neurol Med Chir (Tokyo) 2004;44(10):562-7.
10. Harman M, Unal O, Onbasi KT, Kiymaz N, Arslan H. Brucellar spondylodiscitis - MRI diagnosis. Clinical Imaging 2001;25(6):421-7.
11. Namiduru M, Karaoglan I, Gursoy S, Bayazit N, Sirikci A. Brucellosis of the spine: evaluation of the clinical, laboratory, and radiological findings of 14 patients. Rheumatol Int 2004;24(3):125-9.