Original Article

SURGICAL OUTCOME OF 7-MILLIMETER BILATERAL MEDIAL RECTUS RECESSION IN LARGE ANGLE CHILD ESOTROPIA

Sameen Afzal Junejo[1], Arshad Ali Lodhi[2], Munawar Alam Ansari[3]

ABSTRACT

Objective: To evaluate the surgical success in the patients undergoing bilateral 7 mm medial rectus recession for large angle esodeviation.

***Methodology*:** The subjects less than 15 years of age presenting with concomitant esotropia with deviations of 60 prism diopter (PD) and more were registered for bilateral medial rectus recession surgery. Anterior segment slit lamp examination and posterior segment examination was performed with 90 D and 78D fundoscopes in selected cases. Angle of deviation was measured. All necessary investigations were completed. Surgical procedures were performed under general anesthesia. Postoperative follow-up was done.

***Results*:** Almost 71% children underwent successful surgery with residual deviation of less than 15 PD, while 29.0% subjects developed residual strabismus. Four patients presented with foreign body granuloma. Two children developed limitation in adduction. The preoperative deviations of 60 PD showed good results with residual deviation of fewer than 15 PD.

Conclusion: There is a need for guarded muscle correction during bilateral medial rectus recession for improvement in visual alignment and binocular function.

KEY WORDS: Pediatric esotropia; 60 PD and more; medial rectus recession; Success rate.

Pak J Med Sci July - September 2010 Vol. 26 No. 3 589-594

How to cite this article:

Junejo SA, Lodhi AA, Ansari MA.Surgical outcome of 7-millimeter bilateral medial rectus recession in large angle child esotropia. Pak J Med Sci 2010;26(3):589-594

1. Sameen Afzal Junejo,
Professor,
Dept. of Ophthalmology,
2. Arshad Ali Lodhi,
Assistant Professor, Dept. of Ophthalmology
3. Munawar Alam Ansari,
Associate Professor, Dept. of Pharmacology,
1-3: Liaquat University of Medical and Health Sciences,
Jamshoro - Hyderabad, Pakistan.

Correspondence:

Dr. Sameen Afzal Junejo, MCPS; DOMS; FCPS,
Professor and In charge Unit-III,
Liaquat University Eye Hospital,
Liaquat University of Medical and Health Sciences,
Jamshoro,
Hyderabad, Pakistan.
E-Mail: sameenafzal1@gmail.com

* Received for Publication: September 2, 2009
* Revision Received: March 2, 2010
* Revision Accepted: April 10, 2010

INTRODUCTION

Strabismus is defined as the ocular misalignment resulting to deviation of visual axis from bi-foveal fixation. It is a common problem in ophthalmology. The global prevalence of strabismus ranges from 3% to 5%.[1,2] It was detected in 2% to 4% of white population, 0.6 % in Africans and Asians.[3] The prevalence of strabismus was 3.98% in a study conducted by Donnelly and his associates.[4] while in another study from Sydney Australia the squint was observed in 48 patients (2.8% of total population).[5] In a local study from Peshawar in 2004 the prevalence of strabismus was 2%.[6] In another survey among Afghan refugees in Pakistan, the squint was detected in 1.4% subjects.[7]

The management of strabismus includes proper assessment, treatment of amblyopia, correction of refractive errors and surgery. Dr. J. Friederich performed first squint surgery in 1839.[8]

The surgical intervention for ocular alignment of visual axis becomes necessary when conservative treatment is unsuccessful. Important indications for strabismus surgery are; elimination of double vision, restoration of three dimensional vision, ocular alignment of visual axis, widening of visual fields, betterment in psychological status and cosmesis.[9]

The routine surgical management for esotropia consists of monocular recession of medial rectus with resection of lateral rectus or bilateral recession of medial recti. The patients with large angles esodeviation of more than 50 PD require surgery on more than two horizontal recti. Von Noorden and others in their study have recommended 7 mm bilateral medial rectus recession or more instead of operating on three or four muscles.[10,11]

The proper extra ocular muscle alignment in strabismus surgery is considered as residual deviation of 10 PD or less.[12] Following this concept of under correction the residual deviation of 15 PD and less was considered in this study.

METHODOLOGY

Study Area: This is a retrospective clinical analysis conducted on the patients of both sexes with concomitant esotropia presenting for the first time, from July 2002 to June 2006.

Inclusion criteria: All the subjects suffering from constant concomitant esotropia with deviations of 60 prism diopters and more present on at least two visits prior to surgery and without any associated vertical dissociations were included.

Exclusion criteria: The patients with refractive accommodative esotropia (fully corrected by spectacles), history of paretic or restrictive muscle element, nystagmus and prior strabismus surgery were excluded from this study.

Patient's Assessment: In out patient section after obtaining informed consent the assessment was carried out as:

a- General History including age, sex, residence, eye affected and use of corrective lenses (singles and Bi-focal).The parents of affected children less than five years were requested to produce past photographs to exclude developmental element.

b- Best-corrected visual acuity, for dominant (fixating eye) and squinting (non-fixating) eye, using Snellen's chart and E-chart for preschool children,

c- Slit lamp biomicroscopy and applanation tonometry if possible.

d- Dilated indirect ophthalmoscopy by 90D and 78D fundoscopes in selected cases.

e- Ocular movements including versions and ductions in co-operative patients,

f- Measurement of deviation in prism diopter for both distance and near vision as Prism and cover test for near and far distance with good visual acuity , and for subjects with poor vision and less than five years age modified krimsky test was performed.

g- In children refraction under cycloplegia using cyclopentolate 1% eye drops was performed and the element of accommodative component of more than 2.0 diopters hyperopia excluded pre-operatively.

The patients were admitted for strabismus surgery under general anesthesia and investigations like blood complete picture, bleeding and clotting time, detailed urine analysis, X-Ray

Figure-1: A 14 year girl with right eye concomitant esotropia.

Table-I: General characteristics of patients with strabismus: (n=31)

Sex	*N/O Patients*	*Percentage %*
Male	13	41.9
Female	18	58.1
Age in Yrs		
Up to 5	07	22.5
06 to 10	09	29.1
11 to 15	15	48.4
Residence		
RuralUrban	1219	38.761.3
Use of lenses	06	19.3
Financial Status		
Upper	Nil	0.00
Middle	10	32.2
Lower	21	67.8

chest were performed. The surgical procedure consisted of 7 mm bilateral medial rectus recession as; The muscle was exposed by conjunctival incision through limbal approach.

The muscle tendon was engaged by applying two whip stitches with 6'0 poly gelactin 910 absorbable sutures at its upper and lower edges near the insertion. The muscle was cut near its insertion and allowed to retract. The muscle was sutured on sclera posterior to insertion after measuring with caliper. The retracted muscle was pulled to become adherent with attachment site by stretching the suture knots. Conjunctiva was replaced with interrupted absorbable

Figure-2: A 5 year girl with right eye concomitant esotropia.

sutures. Sub-conjunctival injection of genticyn 20 mg mixed dexamethasone 4 mg was given and the eye bandaged for 24 hours.

Postoperative follow-up was done after 15 days, 12 weeks and 16 weeks, which included orthoptic assessment, including visual acuity, measurement of angle of deviation and patients photograph. The final best-corrected visual acuity and angle of deviation was recorded at sixth month.

RESULTS

Out of seven thousand patients (approximately), eighty seven (1.24%) subjects with strabismus presented within the study period. Out of which thirty nine patients having constant concomitant esodeviation fulfilled the study criteria. Eight subjects refused to under go

Table-II: Pre and Post-Operative Clinical Characteristics: Concomitant Esotropia (n = 31)
Surgical Technique: 7 mm Bi-Lateral Medial Rectus Recession.

N/OPts	Age-Yrs	Angle of Deviation in PD		
		Pre-Op	Post-Op	Residual
07	Up to 05	60 (05Pts)	<15 (04 Pts)	>15 (01Pt)>
		60(02Pts)	<15 (01Pt)	>15 (01Pt)
09	06 to 10	60 (06Pts)	<15 (06Pts)	Nil
		>60(03Pts)	<15 (01Pt)	>15 (02Pts)
15	11 to 15	60 (09Pts)	<15 (07Pts)	>15(02 Pts)
		>60(06Pts)	<15 (03Pts)	>15 (03Pts)

Success rate = 71%
PD= Prism Diopter; N/O= Number/Of; Pts= Patients; Yrs=Years;
<= Less than; >= More than.

Figure-3: A 2 year girl with left eye concomitant esotropia

surgical procedure, while remaining thirty one patients (esotropia of 60 PD=20 (64.5%) and esotropia > 60 PD=11 (35.5%) were selected for surgery. The successful surgical outcome was considered as angle deviation of 15 prism diopters or less at sixth month post operative follow up. The general characteristics of selected patients are shown in Table-I.

The patient's data including preoperative angles of deviation (Figures -1-5), surgical procedures and post operative results (Figures - 6-10) are summarized in Table-II.

Out of thirty One operated subjects, seven children were lost to follow up while remaining twenty four completed post operative follow up of six months.

A total of 22 (71%) patients were successfully aligned (orthophoric), while remaining nine

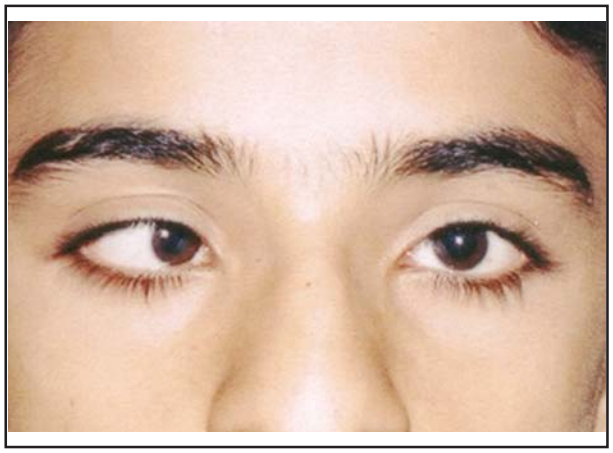

Figure-5: A 12 year boy with right eye concomitant esotropia

Figure-4: A 7 year boy with right eye concomitant esotropia

(29%) subjects presented with residual deviation. Four patients developed suture related foreign body granuloma formation, which resolved within few weeks during the course of treatment. The ocular movements including convergence were normal in all patients. Any tendency towards consecutive (over correction as exodeviation) squint was not observed in any patient during post operative out patient visits. Out of nine patients who exhibited residual strabismus, only four subjects completing the follow up were advised for secondary surgical procedure.

DISCUSSION

Monocular strabismus surgery is quite beneficial as the procedure is completed in short time. Manipulation of fellow dominant eye is also avoided.[13,14] The larger deviations of more than 60 PD are usually difficult to align and needs second surgery on dominant eye or

Figure-6: Right eye concomitant esotropia after surgical correction

Figure-7: Right eye concomitant esotropia after surgical correction

Figure-9: Right eye esotropia after surgical correction

Figure-8: Left eye concomitant esotropia after surgical correction

Figure-10: Right eye esotropia after surgical correction

binocular three muscles surgery on horizontal recti.[15,16]

Bilateral symmetrical medial rectus recession is a most suitable surgical procedure towards correction of constant concomitant esotropia.[17] There are many advantages of this technique including preservation of the whole muscle, reduced tendency to post operative granuloma formation, and less chances of induced astigmatism in the early post operative period.[18] As regards the amount of muscle recession many authors have favored 7 mm of symmetrical medial rectus recession. Weakley and his associates reported 75% success rate in visual alignment after 7 mm of recession.[19] In our study 71% of the subjects achieved orthophoria which is quite consistent with the results of Weakley.
Development of delayed consecutive exotropia and post operative limitations in adduction have been reported as some of the possible disadvantages of large symmetrical medial rectus recession.[20] However, guarded muscle recession (not exceeding 7 mm on medial rectus and 8 mm on lateral rectus)[21,22] and surgical intervention before 24 months reduces the incidence of consecutive exodeviation and ocular movements limitation thereby improving binocular function and stereopsis.[23]

CONCLUSION

A 7 mm recession of medial recti is an effective procedure for the correction of large angle esotropia of 60 PD and more can be considered as an acceptable alternative to operation on three or four muscles.

REFERENCES

1. Arora A, Williums B, Arora AK. Decreasing strabismus surgery. Br J Ophthamol 2005;89:409-412.
2. Abrahamsson M, Magnusson G, Sjostrand J. Inheritance of strabismus and the gain of using heredity to determine population at risk of developing strabismus. Eye 2002;16:519-21.
3. Hu DN. Prevalence and mode of inheritance of major genetic eye diseases in China. J Med Genet 1987;24:584-588.
4. Donnelly UM, Stewart NM, Hollinger M. Prevalence and outcomes of childhood visual disorders. Ophthalmic Epidemiol 2005;12:243-250.

5. Robaei D, Rose KA, Kifley A. Factors Associated With Childhood Strabismus: Findings from a population-based study. Ophthalmology 2006;113:1146-1153.
6. Ahmed N, Aamir AH, Hussain I, Ghulam S. Annual Prevalence of Various Diseases in Hospitalized Patients in a Tertiary Level Teaching Hospital at Peshawar. Pak J Med Res 2004;43(4):166-171.
7. Awan HR, Ahsan T. Prevalence of Visual Impairment and Eye Diseases in Afghan Refugees in Pakistan. East Medi Health J 1998;4(3):560-566.
8. Cooper J, Medow N. Major review, Intermittent Exotropia, Basic and Divergence Excess Type. Bino V Eye Mus Surgery 1993;8:185-216.
9. Keenan JM, Willshaw HE. Outcome of strabismus surgery in congenital esotropia. Br J Ophthalmol 1992;76:342-345.
10. Spiritus M. Large medial rectus recessions versus bimedial posterior fixation with additional rectus recessions. Trans 19th meeting ESA. Crete 1991:59-64.
11. Von Noorden GK. A reassessment of infantile esotropia. XI.IV Edward Jeckson Memorial Lecture. Am J Ophthalmol 1988;105:1-10.
12. Scott WE, Reese PD, Hirsh CR, Flabetich CA. Surgery for large angle congenital esotropia. Arch Ophthalmol 1986;104:374-377.
13. Celebi S, Kukner AS. Large bilateral lateral rectus recession in large angle divergence excess exotropia. Eur J Ophthalmol 2001;11(1):6–8.
14. Livir-Rallatos G, Gunton KB, Calhoun JH. Surgical results in large-angle exotropia. J APOS 2002;6(2):77–80.
15. Amitava AK, Goswami AK, Mishra A. Large-angle strabismus and primary true muscle transplantation. J Pediatr Ophthalmol Strabismus 2005;42(4):211–215.
16. Forrest MP, Finnigan S, Finnigan S, Gole GA. Three horizontal muscle squint surgery for large angle infantile esotropia. Clin Experiment Ophthalmol 2003;31(6):509–516.
17. Anna R. O'Connor, Sherry I. Fawcett, David R. Stager, Eileen E. Birch. Factors Influencing Sensory Outcome Following Surgical Correction of Infantile Esotropia. Am Orthop J 2002;(52):69-74.
18. Agarwal SP. Comparison of symmetrical and asymmetrical surgery in the management of esotropia: Induced Astigmatism. Midland Opth Soc Registrar's Prize. 1985.
19. Weakley DR, Stager DR, Everett M: Seven-millimeter bilateral medial rectus recessions in infantile esotropia. J Pedr Ophth Strabismus 1991;28:113–115.
20. Stager DR, Weakley DR, Everett M, Birch EE:Delayed consecutive exotropia following 7-millimeter bilateral medial rectus recession for congenital esotropia. J Ped Ophth Strabismus 1994;31:147–150.
21. Prieto-Díaz J, Souza-Dias C, Prieto-Díaz, Souza-Dias C. Estrabismo. São Paulo: Livraria Santos Editora Esotropias 2002;149–199.
22. Tatiana Millán, Keila Monteiro de Carvalho, and Nilza Minguini. Results of Monocular Surgery Under Peribulbar Anesthesia for Large-Angle Horizontal Strabismus. Clinics 2009;64(4):303–308.
23. Birch EE, Fawcett S, Stager DR: Why does early surgical alignment improve stereo acuity outcomes in infantile esotropia. J AAPOS 2000;4:10–14.