

## MANAGEMENT OF CHILDHOOD ABDOMINAL MASSES BY NIGERIAN TRADITIONAL DOCTORS: A worrisome cause of delay in presentation

Osifo O.D<sup>1</sup>, Evbuomwan P, Efobi C.A<sup>3</sup>

### ABSTRACT

Abdominal masses are very common in Nigeria. These have been managed by traditional doctors even before the advent of orthodox medications. Traditional doctors are however, not able to distinguish between the various causes of abdominal swellings, hence all are diagnosed and managed as splenomegaly (ude). Their modes of treatment are scarification, tattooing and concoction application in different combinations. We retrospectively studied twenty two patients who were mismanaged by traditional doctors before presenting to us at the University of Benin Teaching Hospital, Benin City - Nigeria. They all presented very late with life threatening complications and advanced diseases. Treatment offered on presentation included wound dressing, resuscitation, blood transfusion, antibiotics and laparotomy with resection of the masses, depending on diagnoses. These could only salvage 13(59.1%) of the patients while a high mortality of 9(40.9%) was recorded. The need to improve on our health care delivery system is stressed.

**KEY WORD:** Traditional doctors, Childhood, Abdominal masses.

Pak J Med Sci October - December 2007 (Part-I) Vol. 23 No. 5 809-813

### INTRODUCTION

Childhood abdominal masses are very common in Nigeria. Tropical splenomegaly due to malaria fever is frequently seen in children.<sup>1</sup> This is called by various native names such as "Ude" by the Edo people. Traditional doctors often treat this by scarifications, tattooing and concoction application which they have come to regard as standard mode of treatment. Unfortunately, all abdominal masses and even abdominal swellings without mass are taken as "ude" and treated as such irrespective of location within abdominal quadrant. Even

poorly treated malaria fever which persists longer than necessary is attributed to "ude" and is treated accordingly. Complications resulting from this and other forms of traditional treatment<sup>2-5</sup> have been alarming & worrisome.

Nigerian traditional medical practice, like in other parts of the world was well established before the advent of orthodox medications. The practice is still, however, with us after over five hundred years of contacts with modern medical practice. It still remains as the only form of medical care that is affordable and available to the majority of Nigerian population. It also still serves as the first line of defense against diseases in a great proportion of people even amongst the enlightened city dwellers and the elites.<sup>6</sup> Although the Nigerian traditional healers and herbalists are general practitioners, some of them do specialize, though in rudimentary form.<sup>6</sup>

Many patients who develop complications are not referred for orthodox care until it is too late. This is even worse in case of children who depend on their parents' or guardians' consent

1. Osifo OD,
  2. Evbuomwan I,
  3. Efobi CA,
- 1-3: Paediatric Surgery Unit, Dept. of Surgery,  
University of Benin Teaching hospital,  
Benin City - Nigeria.

Correspondence

Dr. Osifo O.D,  
E-mail: Leadekso@yahoo.com

- \* Received for Publication: May 26, 2007
- \* Revision Accepted: August 30, 2007

for treatment and hence for the quality of healthcare received. A number authors have reported complications resulting from management of gunshot injuries<sup>2</sup> & fractures<sup>3-5</sup> by traditional doctors. Not much has been said about management of abdominal masses by them.

The purpose of this retrospective study was to report our experience with abdominal masses treated by traditional doctors over a seven years period, so as to highlight the types of cases treated as abdominal masses, treatment received, complications and outcome. This also highlights the need to improve health education and bring community health services to the doorstep of our people especially the underprivileged and rural dwellers.

### PATIENTS AND METHODS

University of Benin Teaching Hospital is a tertiary teaching hospital located in the South-south geopolitical zone in Nigeria. Complicated cases are referred from other hospitals within the region, from the paediatric department in the hospital and other health institutions including traditional health providers. A total of 37 patients who presented in our unit between January, 2000 and December, 2006 were studied. The patients (n=15) who presented to orthodox doctors from the start, those who presented stable and without abdominal mass and those whose case files could not be retrieve for analysis were excluded from the study. The remaining 22 were studied for variables such as age, sex, aetiology of abdominal mass/swelling, traditional treatment received, complications arising from it, orthodox treatment and final outcome. The data obtained from the study are presented in tables and figures.

### RESULTS

There were 37 cases that presented with abdominal mass and swelling over the period of study and 22 of these cases were studied. All cause of abdominal swelling was treated as "ude". Abdominal swelling without a mass constituted 40.9% of the cases treated and Wilm's tumour accounted for 18.2%. Only in 9.1% was splenomegaly (ude) correctly diagnosed. Ovarian mass constituted 9.1% and

hepatoblastoma, neuroblastoma, intussusception and mesenteric cyst constituted 4.5% each (Table-I).

Ages of the patients range between 6 days and 12 years with a male/female ratio of 1.2:1. Tattooing, scarifications and concoction application in various combinations were the usual mode of treatment. Scarifications was combined with concoction application in 18.18%, scarification alone in 36.50%, scarification/tattooing in 18.18%, tattooing alone in 18.18% while tattooing/concoction application and attempted anal perforation were done in 9.1% (Table-II and Fig.1a-2b).

All the patients developed one form of complication or the other. These were minor in 9.1% but life threatening morbidities in 90.9%, ranging from wound infection, dehydration, shock, anaemia, advanced tumours and respiratory failures. Treatment offered on presentation included wound dressing, resuscitation, blood transfusion, antibiotics and laparotomy with resection of the masses, depending on diagnoses. Only 13 (59.1%) of the patients could be salvaged by our intervention and a total of 9 (40.9%) patients succumbed to the illness. The causes of death were multiple organ failures from advanced malignancy or overwhelming infections.

### DISCUSSION

Childhood abdominal masses are quite common worldwide and neuroblastoma is most common, followed by Wilm's tumour in Caucasian.<sup>7</sup> From our series and previous report<sup>8</sup>

Table-I: Various cases treated as abdominal mass by traditional doctors and their relative frequency

Cases	Frequency	Percentage (%)
Abdominal swelling without mass	9	40.9
Wilm's tumour	4	18.2
Ovarian mass	2	9.1
Splenomegaly	2	9.1
Hepatoblastoma	1	4.5
Lymphoma	1	4.5
Neuroblastoma	1	4.5
Intussusception	1	4.5
Mesenteric cyst	1	4.5
Total	22	100.0

Table-II: Age/ Sex Distribution, the Diagnosis and Treatment given by Traditional Doctors

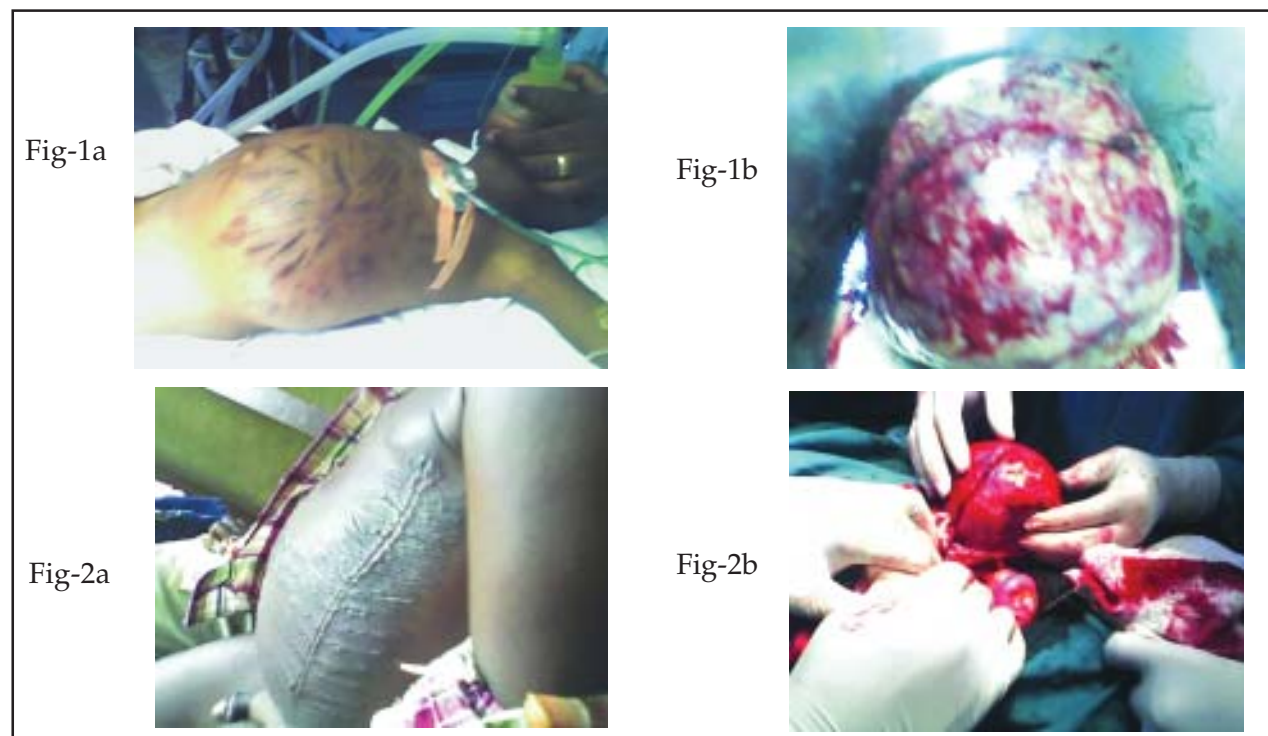
<i>Names</i>	<i>Age</i>	<i>Sex</i>	<i>Diagnosis</i>	<i>Traditional Medications</i>
O.D	4months	Male	Intussusception	Scarification/concoction
E.U	5years	Male	Left Wilm's tumour	Scarification/concoction
O.J	2years	Male	Right Wilm's tumour	Tattoos/concoction
D.T	1year	Male	Left Wilm's tumour	Scarification
O.Y	2years	Female	Hepatoblastoma	Scarification
U.I	6days	Female	Imperforate anus	Scarification/concoction
B.U	1week	Female	Hirschsprung's disease	Scarification
O.B	3years	Male	Malaria fever/splenomegaly	Scarification/tattoos
P.T	1year	Male	Hirschsprung's disease	Scarification/tattoos
P.B	2years	Female	Malaria fever/splenomegaly	Scarification/tattoos
R.B	2years	Male	Bilateral. Wilm's tumour	Scarification/concoction
N.M	1year	Female	Malaria fever without mass	Tattoos
T.B	1.5years	Female	Malaria fever without mass	Tattoos
C.Y	4years	Male	Malrotation	Scarification
G.P	12years	Female	Left ovarian teratoma	Tattoos/scarification
M.O	8years	Female	Left ovarian cyst	Scarification
P.I	11years	Female	Abdominalwall tuberculosis	Tattoos
B.P	6years	Male	Intraabdominal tuberculosis	Scarification
P.W	4years	Male	Lymphoma	Tattoos
B.S	1year	Male	Neuroblastoma	Scarification
C.B	2months	Female	Mesenteric cyst	Scarification
N.O	6days	Male	Imperforate anus	Attempted anal perforation

in Nigeria, Wilm's tumour is the commonest cause of childhood abdominal mass, followed by tropical splenomegaly syndrome due to malaria endemicity. Other less common causes include liver tumours, ovarian tumours, mesenteric cysts, neuroblastoma lymphoma etc which are all treated as "ude" by traditional doctors as shown in (Tables-I, II). The high mortality rate recorded in this study is in keeping with other forms of treatment by traditional doctors. Osime et al<sup>2</sup> reported the high morbidity and mortality associated with management of gunshot injuries by traditional doctors. Omololu et al<sup>3</sup> and Onuminya et al<sup>4</sup> from the western part of the country drew attention to the high complications and avoidable amputations resulting from traditional bonesetters treatment. Reports from the northern part of the country by Yakubu et al,<sup>5</sup> also revealed the high rate of avoidable limb amputations due to treatment by traditional doctors. Encouraging revelation came much earlier when Oyebola<sup>11</sup> conducted an interview on 156 traditional doctors and discovered that 125 (80%) of them were willing to cooperate and learn from the western-trained doctors in order to

improve their efficiency. It is hoped that health policy makers in Nigeria will incorporate this into their curriculum in the nearest future.

Apart from complications resulting from poor management, all the patients presented very late and at times in terminal stage of the disease. Many of them got the assurance that the ailment can only be handled by traditional methods. This is in consonance with the work of other researchers who reported that superstitious beliefs still play a major role in delaying and at times prevent seeking orthodox medication in many African countries.<sup>11-13</sup> Poor responses to treatment were blamed on some spiritual forces which cannot be handled by orthodox medications except sacrifice, incantations, tattoos scarification and application of concoction. These made even the enlightened people to have faith in them, only to seek orthodox help when the case was terminal.

Inspite of the high mortality recorded many patients still patronized them perhaps because they have no alternative means either due to non availability of modern health services or lack of funds to come to a sophisticated centres. These contributed immensely to the delay



Figures:-1a- shows a 2 year old boy with extensive tattoo and concoction application, 1b- shows stage 4 Wilm's tumour resected in the same boy. 2a- shows deep scarifications and concoction application in a 5 year old boy; 2b-shows stage 3 Wilm's tumour being mobilized intra-operatively in the same boy.

in presentation in this study. These traditional health carers are readily available, affordable and appeal to traditional belief that ill healths are caused by unseen forces which can only be appeased by traditional means without much financial involvement.<sup>12,13</sup> Osuntokun<sup>9</sup> reported that in Nigeria, because of gross shortage of western-trained health personnel, many patients frequently resort to traditional doctors who spend 8-10 years in training. Their pharmacotherapeutics are based in part on observation tested through the ages, and not on cause and effect phenomena, hence the poor results. Many ailments such as gunshot injuries,<sup>2</sup> bone fractures<sup>3-5</sup> and psychiatric illness<sup>10</sup> therefore, have established traditional clinics in Nigeria. We also noted from this study that a large proportion of cases who presented with abdominal swelling such as intussusception, imperforate anus, hirschsprung's disease, malrotation and even persistent malaria fever were treated as splenomegaly. The distinction between other solid tumours was also not made, as only in 2(9.1%) patients was splenomegaly

present. The remaining 90.9% were victims of not only result of poor treatments received but also of wrong diagnosis. Those who had anorectal anomaly and hirschsprung's disease presented in neonatal period. They developed septic shock shortly after traditional treatment and died within few days of life. Findings from this study necessitate the need for us to improve our health awareness campaign. Poor access roads to most rural communities in Nigeria also make it impossible for people, especially children to benefit from standard health care services as obtains in developed countries of the world.

## CONCLUSION

Abdominal masses/swellings are grossly mismanaged by traditional doctors in Nigeria with resultant high morbidity and mortality rates. Poverty, ignorance, superstitious beliefs, non availability and affordability of orthodox medication encourage their patronage. Cooperation between orthodox and traditional doctors may in the near future reverse this ugly trend.

Table-III: Complications from traditional medications, clinical state at presentation and outcome

Names	Complication from traditional treatment	Clinical state on presentation	Orthodox treatment	Outcome
O.D	Sepsis	Shock	Resuscitation	Died
E.U	Abdominal wall fasciitis	Anaemia/ Adv tumour	Dressing/exploratory laparotomy	Died
O.J	Scars	Adv. tumour	Exp. Lap/nephrectomy	On chemo.
D.T	Sepsis	Adv. tumour	Exp. Lap/nephrectomy	On chemo.
O.Y	Scars	Adv. Tumour/ C.N.S spread	Resuscitation/transfusion	Died
U.I	Aspiration/ sepsis	Toxaemia/shock	Resuscitation/colostomy	Died
B.U	Sepsis	Resp. difficulty/ dehydration	Colostomy/pull through	Survived
O.B	Wound Infection	Anaemia	Trasfusion/antimalaria	Survived
P.T	Scars	Gross abdominal distension	Colostomy/pull through	Survived
P.B	Abdominal wall fasciitis	Sepsis/anaemia	Wound dressing/ antimalaria	Survived
R.B	Septic wound	Adv. tumour	Transfusion/laparotomy	Died
N.M	Septic wound	No mass/anaemia	Antimalaria/transfusion	Survived
T.B	Wound infection	No mass/sepsis	Antimalaria/transfusion	Survived
C.Y	Healed scars	Dehydration	Lap/Lad's procedure	Survived
G.P	Healed scars	Adv. Tumour	Oophorectomy	Died
M.O	Healed scars	Stable	Lap/ovarian cystectomy	Survived
P.I	Scars/tattoos	Stable	Antituberculosis	Survived
B.P	Healed scars	Adv. T.B	Antituberculosis	Survived
P.W	Tattoos/scars	Adv. disease	Laparotomy/biopsy	Died
B.S	Wound infection	Adv./anaemia	Laparotomy/biopsy	Died
C.B	Wound infection	Gross abdominal distension	Laparotomy/cystectomy	Survived
N.O	Sepsis	Aspiration/ abd. Distension/shock	Resuscitation	Died

## REFERENCES

- Rains AJ, Ritchie HD. Tropical splenomegaly; Bailey and Love's Short Practice of Surgery, nineteenth edition, H.K Lewis & Co. Ltd, London 1984;837-8.
- Osime OC, Elusoji SO. Outcome of management of gunshot injuries by Nigerian Traditional Doctors. *Park J Med Sci* 2006;22(3):316-9.
- Omololu B, Ogunlade SO, Alonge TO. The Complications seen from the Treatment by Traditional bonesetters. *West Afr J Med* 2002;21(4):335-7.
- Onuminya JE, Obekpa PO, Ihezue HC, Ukegbu ND, Onabowale BO. Major Amputations in Nigeria: A Plea to Educate Traditional Bonesetters. *Trop Doct* 2000;30(3):133-5.
- Yakubu A, Muhammad I, Mobogunje OA. Major Limb Amputations in Adults, Zaria, Nigeria. *JR Coll Surg Edinb* 1996;41(2):102-4.
- Osunhor PC, Osunhor A: In: Contact with Traditional Medicine. *West Afr J Pharmacol Drug Res* 1979;5(1):85-91.
- Hutson JM, Beasley SW. Abdominal Masses. The surgical examination of children, Heinemann Medical Books, London, 1988;188-201.
- Nwako FA. Abdominal Masses in Infants; A Textbook of Paediatric Surgery in the Tropics, The Macmillan Press Ltd, London. 1980;165-9.
- Osuntokun BO. The Traditional Basis of Neuropsychiatric Practice among the Yorubas of Nigeria. *Trop Geogr Med* 1975;27(4):422-30.
- Aluede OC. Music Therapy in Traditional African Societies: Origin, Basis and Application in Nigeria; *J Him Ecol* 2006;20(1):31-5.
- Oyebola DD. Some Aspects of Yoruba Traditional Healers and their Practice. *Trans R Soc Trop Med Hyg* 1980;74(3):318-25.
- Nbiti JS. African Religion and Philosophy; Heinemann Educational Books Ltd, London 1976;25-7.
- Awolalu JO, Dopamy PA. West African Traditional Religion, Onibonjo Press Ltd, Ibadan. 1979;15-7.