

## BILIARY-BRONCHIAL FISTULA AS A LATE COMPLICATION OF HEPATIC RESECTION

Adnan Al-Suleihat<sup>1</sup>

### SUMMARY

Biliary-Bronchial Fistula (BBF) is a rare but serious complication of hepatic resection. We present a 31-year-old woman with a biliary-bronchial fistula due to common bile duct stricture that developed three years after right hepatectomy for metastatic colonic carcinoma. The diagnosis was based on clinical presentation, analysis of sputum, radiological findings, and bronchoscopy. Drainage of the intrahepatic biliary tract resulted in complete resolution of her symptoms.

**KEY WORDS:** Bile ducts, Biliary-bronchial, Fistula.

Pak J Med Sci October - December 2008 (Part-I) Vol. 24 No. 5 757-761

### How to cite this article:

Suleihat AA. Biliary-bronchial fistula as a late complication of hepatic resection. Pak J Med Sci 2008;24(5):757-61.

### INTRODUCTION

Biliary-Bronchial Fistula (BBF) is defined as a passageway between the biliary system and bronchial tree with presence of bile in the bronchus and the sputum (bilioptysis). Biliary-bronchial fistulas are rare but serious complications of hepatic resection that can present from days to years after operation.<sup>1</sup> However, in most cases they are caused by hepatic or subphrenic abscesses, resulting from different conditions.<sup>2,3</sup> Pulmonary symptoms dominate the clinical picture and the main manifestations are chronic irritant cough, production of watery dark-yellow sputum, bronchopneumonia, and dyspnea. The diagnosis of BBF can be confirmed by imaging procedures such as biliary

scintigraphy with hepatic iminoacetic acid (HIDA),<sup>4</sup> percutaneous transhepatic cholangiography (PTC),<sup>1,3</sup> or endoscopic retrograde cholangiopancreatography (ERCP).<sup>5</sup> Bronchoscopy can demonstrate the presence of bile in the bronchial tree and may delineate the site of fistula.<sup>6</sup> The treatment strategy for patients with BBF and biliary tract obstruction is the reestablishment of bile drainage, which allows the fistula to heal by reducing intrabiliary pressure. We present a case of biliary-bronchial fistula due to common hepatic duct stricture in a patient with previous right hepatectomy for colonic metastasis to the liver.

### CASE REPORT

A 31-year-old female patient was initially diagnosed with adenocarcinoma of the left colon. In April 2003, she underwent left hemicolectomy with total resection of the mass followed by chemotherapy. One year later, she developed nausea, vomiting, right upper quadrant abdominal pain and jaundice. At that time computed tomography scan of the abdomen showed an enlarging hypoechoic lesion in the right lobe of the liver suggestive of liver metastasis. She underwent right hepatectomy.

---

1. Adnan Al-Suleihat, MD,  
Jordanian Board of Internal Medicine,  
Respirator Division, King Hussein Medical Center,  
Amman, Jordan

#### Correspondence

Adnan Al-Suleihat, MD  
P. O. Box: 141192, Al-Biader,  
Amman: 11814, Jordan.  
E-Mail: drasabbadi@yahoo.ca

\* Received for Publication: April 25, 2008

\* Accepted: August 15, 2008

Her postoperative course was complicated by right basal pneumonia and small pleural effusion, which resolved with antibiotic therapy alone. She remained relatively well until June 2007 when she developed clinical picture of obstructive jaundice associated with fever, shortness of breath, cough and bilious expectoration (bilioptysis).

On examination, she was in a poor general condition, emaciated with a body weight of 51kg for 172cm height. She was jaundiced, mildly dyspnic, coughing frequently and expectorating watery bile-stained sputum. The blood pressure was 120/60mmHg, the pulse rate 95 beats/minute and regular, respiratory rate 20 breaths/minute, oral temperature 38.3°C and oxygen saturation 94% on room air. Her chest examination revealed dullness on percussion and crackles at the right lower base. On abdominal examination, there were scars of previous abdominal surgeries and mild hepatomegaly but no signs of hepatic insufficiency or portal hypertension. The rest of her physical examination was normal. Laboratory evaluation revealed a hematocrit of 31%, white blood cell count of 13.500/mm<sup>3</sup> with a predominance of neutrophils, and platelet count of 196000/mm<sup>3</sup>. Her liver function tests showed a total bilirubin of 11.5mg/dl; with a direct bilirubin of 8.2mg/dl, serum alkaline

phosphatase 1658U/l,  $\alpha$ -glutamyltransferase ( $\alpha$ -GT) 460U/l, and albumin 2.7mg/dl. The rest of her laboratory investigations including the transaminases, were all-normal. Urine analysis revealed bilirubinuria and absent urobilinogen. Blood and sputum cultures were negative for pathogenic organisms. Chest radiography and CT scan showed subsegmental collapsed consolidation in right lower lobe (Figure-1A and B, black arrows), and large intrahepatic collection (Figure-1B, red arrow). Bronchoscopy revealed abundant yellowish secretions coming from the right lower lobe, but failed to show the site of the fistula. The sputum and bronchial wash were tested for bile and it was positive. Bronchial washing cytology was negative for malignancy. Endoscopic retrograde cholangiopancreatography (ERCP) revealed stricture of the common bile duct (CBD) with contrast medium seen in the right bronchial tree (Figure 2, arrow). A postoperative stricture of the common bile duct and a biliary-bronchial fistula were highly suspected. Then percutaneous transhepatic cholangiography (PTC) was performed which showed the large intrahepatic biliary collection which was seen in the CT scan (Figure-3, red arrow), combined by intrahepatic bile ducts dilatation (Figure 3, black arrow), with sever narrowing of the common bile duct (Figure-3, black

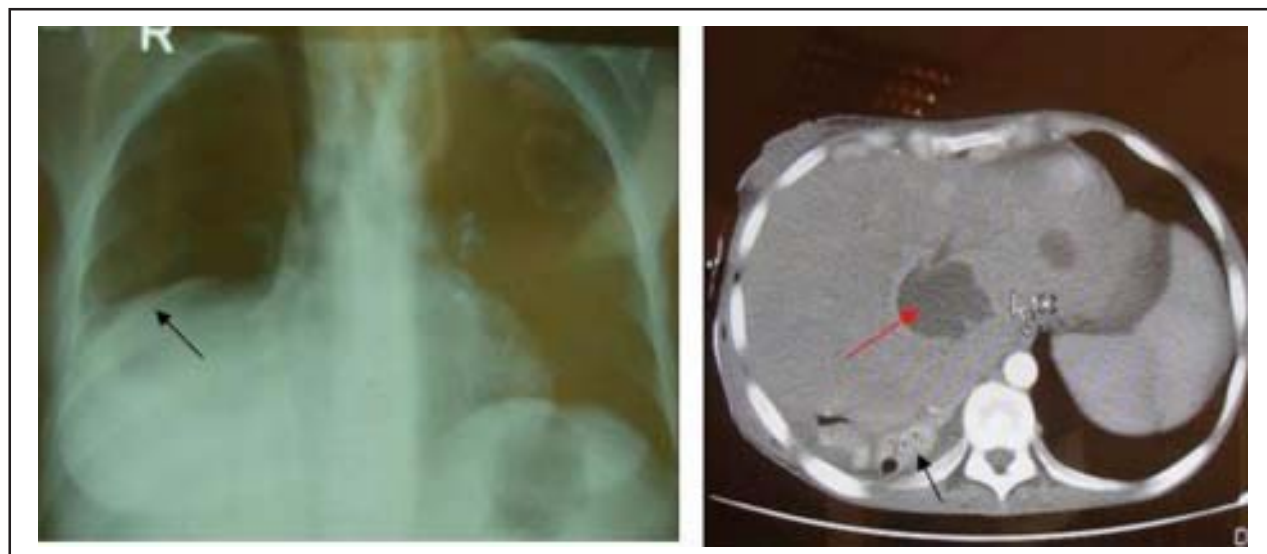


Fig-1: Chest x ray (A) and CT scan (B) showing right lower lobe subsegmental collapsed consolidation (black arrows), and large intrahepatic collection (Fig 1, B red arrow).

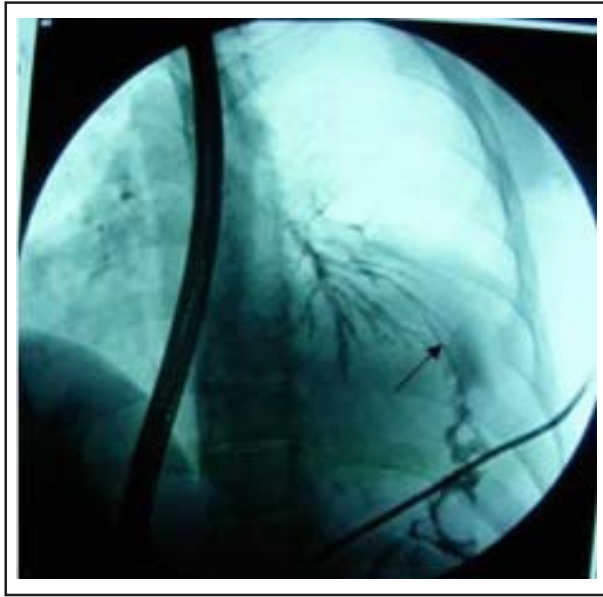


Fig-2: Endoscopic retrograde cholangiopancreatography showing the fistula between the biliary and right bronchial tree (arrow).

arrow head), and there was a fistulous communication between the dilated intrahepatic biliary tract and the right lower lobe of the lung. (Figure 3, white arrow).

The patient was considered unsuitable for surgery because of her poor general condition, advanced malignancy and malnourishment. She underwent percutaneous internal-external biliary drainage across the right hepatic duct and she received a course of antibiotics for her pneumonia. Postprocedure, the patient showed dramatic improvement with the disappearance of respiratory complaints. The laboratory investigations showed gradual decrease in the serum bilirubin and alkaline phosphate level. After two weeks the external biliary drainage was removed and percutaneous transhepatic stenting of the common bile duct (CBD) was performed to provide adequate biliary drainage. The patient remained asymptomatic and was discharged to be followed up by her primary surgical team of oncology and gastroenterology.

## DISCUSSION

BBF is an uncommon condition usually seen in endemic regions as a complication of hydatid

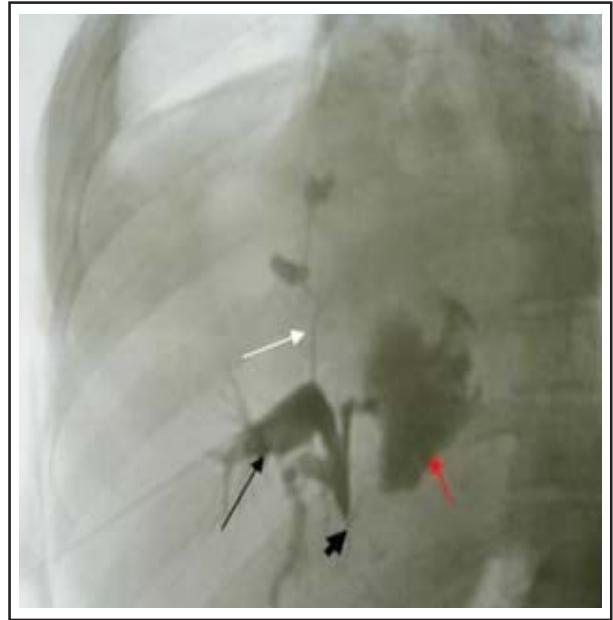


Fig-3: Percutaneous transhepatic cholangiography showing large intrahepatic biliary collection (red arrow), with intrahepatic bile ducts dilatation (black arrow), severe narrowing of the common bile duct (black arrowhead) and a fistula is seen between the biliary and bronchial tree (white arrow).

or amebic disease of the liver, but there are many other causes, including congenital malformation, trauma, malignancy,<sup>4</sup> hepatic abscess formation<sup>2,7</sup> and postoperative complications of hepatobiliary surgery.<sup>8,9</sup> Worldwide, the most common cause of BBF formation is parasitic organisms. In 1850, Peacock<sup>10</sup> reported the first case of BBF in a patient with a hydatid cyst. In most patients with nonparasitic BBF, obstruction of the bile ducts is usually an associated feature.<sup>11</sup> Biliary-bronchial fistulas (BBFs) after hepatic resection are rare; as a result, very few cases have been reported in literature. Rose et al<sup>1</sup> reported a case of BBF which developed four years later after hepatic resection in a patient with colorectal metastasis to the liver. The pathogenesis of BBF caused by bile duct obstruction probably involves a local inflammatory processes (cholangitis) followed by intrahepatic abscess formation and rupture of these abscess into the pleural space or, if adhesions exist, into the bronchial tree.<sup>12</sup> This explains the preferential location of BBFs in the right side of the chest.

Most fistulae involve the right basilar segments of the lung.<sup>13</sup> The classic clinical presentation of such cases is irritant cough productive of copious dark-yellow sputum (bilioptysis) which is very specific symptom of biliary-bronchial fistula.<sup>14</sup> In addition, acute pneumonitis or bronchiolitis can result from the intense inflammatory reaction of the bronchial mucosa secondary to bile or even chronic bronchopneumonia can be present. Time of inciting event to patient presentation is also variable, ranging from days to years. Our case presented three years after hepatic resection with expectoration of yellow bile stained sputum (150-200 ml/day) and bile in sputum and bronchial wash was confirmed with analysis of bilirubin levels. The diagnosis can be confirmed by imaging procedures such as biliary scintigraphy with hepatic iminoacetic acid (HIDA),<sup>4</sup> percutaneous transhepatic cholangiography (PTC),<sup>1,3</sup> or endoscopic retrograde cholangiopancreatography (ERCP).<sup>5</sup> Bronchoscopy rarely demonstrates the fistula but in our case, it was helpful because it discovered bile in the right bronchial tree. Ultrasound examination and CT scan can be useful in the detection of associated pathological conditions such as abscess, biloma, stones, or tumors. However, PTC and ERCP are the diagnostic studies of choice and offer the possibility of therapeutic intervention.<sup>1</sup> The treatment strategy for patients with BBF and obstruction is reestablishment of bile drainage into the duodenum, which allows the fistula to heal by reducing intrabiliary pressure.<sup>9</sup>

Morton and Philips<sup>15</sup> have reported that a BBF would heal spontaneously after establishment of adequate biliary drainage obtained either endoscopically or percutaneously. Because surgical treatment is difficult and tend to be complicated with significant morbidity and mortality, endoscopic or percutaneous transhepatic biliary drainage has been developed to avoid surgery-related complications. Surgical treatment should be considered only after failure of less invasive techniques.<sup>1</sup> Many techniques are available for bile drainage reestablishment, such as nasobiliary drainage

catheters,<sup>16</sup> endoscopic sphincterotomy, placement of biliary stents,<sup>17</sup> dilatation of stenotic bile duct and embolization of biliary fistula with diverse embolic materials (coils, Histoacryl).<sup>9</sup> The placement of a biliary stent is certainly a promising treatment method for patients with BBF. In this patient, the BBF was managed by percutaneous external biliary drainage followed by placement of metallic stent in the stenotic bile duct. The patient remained asymptomatic during the three months follow-up. Schwartz et al<sup>18</sup> reported successful treatment of postoperative stricture BBF with percutaneous external biliary drainage and ballon dilatation cholangioplasty. In 1992, D'Altorio et al<sup>19</sup> reported treating a case of post-traumatic BBF with percutaneous biliary metallic stent. These reports have introduced a nonsurgical treatment to a disease process that has traditionally been treated surgically. These nonsurgical methods of treatment should be considered in the case of postoperative strictures BBF when the patient is not a candidate for surgery. This case gives us the chance to review BBFs secondary to biliary obstruction after hepatic resection, placing particular emphasis on the opportunities of percutaneous biliary drainage and stenting as nonsurgical modalities of treatment.

## REFERENCES

1. Rose DM, Rose AT, Chapman WC, Wright JK, Lopez RR, Pinson CW. Management of bronchobiliary fistula as a late complication of hepatic resection. *Am Surg* 1998;64:873-6.
2. Borrie J, Shaw JHF. Hepatobronchial fistula caused by hydatid disease. The Dunedin experience 1952-1979. *Thorax* 1981;36:25-8.
3. Flemma RJ, Amlyan WG, Durham NG. Tuberculous bronchobiliary fistula. *J Thorac Cardiovasc Surg* 1965;49:198-201.
4. Andalkar L, Trow TK, Motroni B, Katz DS. Bronchobiliary fistula as a complication of liver metastases: Diagnosis by HIDA scans. *Clin Nucl Med* 2004;29(5):289-91.
5. Watkins L, Laufer I, Evans G, Mullens JE. Biliary bronchial fistula demonstrated by endoscopic retrograde cholangiography. *JAMA* 1975;113:868-74.
6. Kamal A, Mansour MD, Wiley S, Black MD, Dale E, Doming, Osler A, Abbott A. New cause for biliobronchial fistula. *Dis Chest* 1969;56(6):539-42.

7. Chua HK, Allen MS, Deschamps C, Miller DL, Pairolero PC. Bronchobiliary fistula: principles of management. *Ann Thorac Surg* 2000;70:1392-94.
8. San MG, Smith GW, De Leon EF. Biliary bronchial fistula after right hepatic lobectomy. *Arch Surg* 1985;120:1376-80.
9. Lucero Pizones JA, Iglesias López A, Alcázar Iribarren Marín M, Márquez Galán JL. Bronchobiliary fistula secondary to biliary stricture after hepatectomy. *Rev Esp Enferm Dig* 2005;97(2):135-6.
10. Peacock TB. Case in which hydatids were expectorated and one of suppuration of a hydatid cyst of the liver communicating with the lungs. *Edinburgh Med Surg J* 1850;74:33-46.
11. Memis A, Oran I, Parilder M. Use of histoacryl and covered nitinol stent to treat a bronchobiliary fistula. *J Vasc Interv Radiol* 2000;11:1337-40.
12. Adams HD. Pleurobiliary and bronchobiliary fistulas. *J Thorac Surg* 1955;30:255-64.
13. Chua HK, Allen MS, Deschamps C, Miller DL, Pairolero PC. Bronchobiliary fistula: principles of management. *Ann Thorac Surg* 2000;70(4):1392-4.
14. Gugenheim J, Ciardullo M, Traynor O, Bismuth H. Bronchobiliary fistulas in adult. *Ann Surg* 1988;207:90-4.
15. Morton JJ, Philips EW. Bronchobiliary fistula: Review of the recorded cases other than those due to echinococcus and amebic abscess. *Arch Surg* 1928;16:697-753.
16. Patrino V, Dougenis D, Kriticos N, Vagianos C. Treatment of postoperative bronchobiliary fistula by nasobiliary drainage. *Surg Endosc* 2001;15:758.
17. Oettl C, Schema W, Matz-Schimmed S, Fugger R, Mayrhofer T, Herold CJ. Bronchobiliary fistula after hemipatectomy: cholangiopancreatography, computed tomography and magnetic resonance cholangiography findings. *Eur J Radio* 1999;32:211-5.
18. Schwartz ML, Coyle MJ, Aldrete JS, Keller FS. Bronchobiliary fistula: Complete percutaneous treatment with biliary drainage and stricture dilation. *Radiology* 1988;168:751-2.
19. D'Altorio RA, McAllister JD, Sestric GB, Cichon PJ. Hepatopulmonary fistula: treatment with biliary metallic endoprosthesis. *Am J Gastroenterol* 1992;87:784-6.