

NEUROPROTECTIVE EFFECTS OF AQUEOUS DATE FRUIT EXTRACT ON FOCAL CEREBRAL ISCHEMIA IN RATS

Asadi Shekaari Majid¹, Panahi Marzieh², Dabiri Shahriar³,
Safi Khani Zahed⁴, Kalantaripour Taj Pari⁵

ABSTRACT

Objective: Many neuroprotective agents are introduced to protect neurons against oxidative injury. Aqueous Date Fruit Extract (ADFE) is a potent antioxidant agent. This study was designed to investigate neuroprotective effect of ADFE in focal cerebral ischemia in rats.

Methodology: Rats were fed with different doses of ADFE by gastric intubation daily for two weeks. After feeding, right middle cerebral artery was ligated for 30 minutes followed by 48 reperfusion. Then animals were sacrificed and brains removed for Nissl staining. Neuronal damage was then estimated in three distinct areas of CA1 of hippocampus subfield. After determination of ADFE optimal dose, immunohistochemistry was performed for p53 expression.

Results: The optimal dose of ADFE significantly inhibited neuronal damage induced by cerebral ischemia.

Conclusion: The results may suggest that the effectiveness of ADFE in focal cerebral ischemia is most probably due to its antioxidant property.

KEYWORDS: Neuroprotection, Date fruit extract, Ischemia, CA1, Hippocampus.

Pak J Med Sci October - December 2008 (Part-I) Vol. 24 No. 5 661-665

How to cite this article:

Majid AS, Marzieh P, Shahriar D, Zahed SK, Pari KT. Neuroprotective effects of Aqueous Date Fruit Extract on focal cerebral ischemia in rats. Pak J Med Sci 2008;24(5):661-65.

1. Panahi Marzieh, Ph.D,
Assistant professor of Histology,
Ahwaz Jondi Shapour Medical University, Ahwaz, Iran.
2. Asadi Shekaari Majid, Ph.D
Student of Histology, Academic Staff of Kerman
Neuroscience Research Center, Kerman, Iran.
3. Dabiri Shahriar, MD,
Professor of Pathology,
Kerman Medical University, Kerman, Iran.
4. Safi Khani Zahed Ph.D.
Associate Prof. of Anatomy,
Jondi Shahpour Medical University, Ahwaz - Iran.
5. Kalantaripour Taj Pari MS.c,
Academic Staff of Midwifery & Nursing Faculty,
Kerman Azad University, Kerman - Iran.

Correspondence

Panahi Marzieh,
No :18, West Kashan St.,
Golestan Bulvar, Ahwaz, Iran
E-mail: marzpanah@yahoo.com

* Received for Publication: March 4, 2008

* Accepted: July 22, 2008

INTRODUCTION

Ischemia is one of the basic and pathophysiological mechanisms of brain damage which is defined as a situation of severely reduced or completely blocked blood flow. The acute ischemia phase generates some of toxic compounds such as free radicals which can induce increased damage in the brain. The hippocampus is a classical predilection site for ischemic injury of the selective vulnerability type. The CA1 sector suffers from ischemic damage whereas the adjacent CA3 sector and the dentate gyrus are largely resistant.¹

It has been demonstrated that pharmacological agents that possess free radical scavenging or antioxidant properties reduce brain damage during ischemia. Recently, several dietary supplements have been reported to have strong

antioxidant effects and reduce neurological deficits in aged animals.² One of the dietary supplementation is date fruit which has great importance from nutritional and economic points of view and it is composed of a fleshy pericarp and seed.³ The importance of the date in human nutrition comes from its rich composition of carbohydrates, salts and minerals, dietary fibers, vitamins, fatty acids, amino acids and protein. In many ways, date may be considered as an almost ideal food.⁴

In addition, the date palm fruit possesses many useful properties such as antioxidant and antimutagenic,⁵ antibacterial,⁶ antifungal,⁷ anti-tumoral⁸ and gastrprotective.⁹ Meanwhile, date fruit has various neuroprotective agents such as melatonin,¹⁰ polyphenolic compounds³ etc.

This study was designed to investigate neuroprotective effect of ADFE in focal cerebral ischemia in rats.

METHODOLOGY

Animals: Adult male NMRI rats (200-300gr) were purchased from the animal house center of Jondishapour Ahwaz University. Experimental animals were handled according to the regulations of University legislation, controlled by the committee for the purpose of control and supervision of experiments on animals, Iranian Ministry of Health and Education.

The rats were randomly distributed to seven groups (10 animal in each group), four experimental groups (groups 1, 2, 3 and 4), two control groups (group 5 and 6) and sham-operated group (group 7).

The experimental groups were fed with different doses of ADFE (125, 250, 500 & 1000mg/kg) once per day for two weeks by gastric intubation. The control groups had surgery but one of them received the distilled water (control two) and the other one (control one) nothing. The sham-operated group neither received the ADFE nor had any surgical procedure.

Preparation of Date Fruit Extract: Fresh ripened date fruits (Bamy Mozafati Rutab) were collected from authenticated date palms from Bam city, Iran. Fruit flesh (800grams) was

extracted three times with distilled water (1500ml totally) by grinding with a mechanical set. It was centrifuged at 4°C for 20 minutes at 4000g, and the supernatant was collected, lyophilized and stored at -20°C until use. Most of the date fruit components were extracted in water as mentioned in the study by Vayalil.⁵

Surgical procedure: The animals were subjected to transient focal cerebral ischemia using the Middle Cerebral Artery Occlusion (MCAO) method.¹¹ In brief, the animals were anesthetized with chloral hydrate (400mg/kg ip). Under the neurosurgical microscope, the right Common Carotid Artery (CCA) was exposed to a midline incision. After blocking all branches of the External Carotid Artery (ECA) and extra cranial branches of the Internal Carotid Artery (ICA), a 4-0 nylon intraluminal suture was introduced into cervical ICA and advancing in intracranially to block blood flow into the Middle Cerebral Artery (MCA). After thirty minutes suture was withdrawn and blood flow resumed. Body temperature was monitored and maintained at 37± 0.5°C with a rectal thermistor coupled to a heating blanket during surgery. After recovery from the anesthesia, the animals were returned to their home cages. Two days after ischemia the animals were tested for neurological examination.

Neurological examination: Neurological deficits in rats were examined and scored after surgery to confirm the MCA occlusion. The neurologic findings were scored on a modified scoring system that was initiated by Longa et al. as follows: a score of 0 indicate no neurologic deficits; one indicates that the rat has difficulty in fully extending the contralateral forelimb; two indicates that the rat could not extend the contralateral forelimb; three indicates a mild circling to the contralateral side; four indicates a severe circling; five indicates falling to the contralateral side.¹¹

Light microscopy: Two days after ischemia, the animals were re-anesthetized and their brains were perfusion-fixed with 10% formaldehyde after transcatheterial wash-out with heparinized 9% normal saline. Paraffinized brains were cut

onto 6µm sections on a rotary microtome and the sections stained with thionin (Nissl method). Neuronal damage was then estimated as a rate of the number of degenerated pyramidal neurons to that of both surviving and degenerated in three distinct areas of the CA1 subfield in coronal sections for each animal.¹²

Immunohistochemistry (IHC): After determination of optimal dose of ADFE, to get a better insight on molecular mechanism underlying the neuronal death we studied the role of p53 in CA1 of hippocampus.

Brain sections (five µm) from paraffin-embedded tissue were dried overnight at 37°C, dewaxed in xylene and rehydrated through ethanol to Double Distilled Water (DDW). Before immunostaining, slides were totally immersed in boiling sodium citrate (pH 6.0) in a microwave plastic bowl and incubated for ten minutes plus ten minutes in microwave power. Then, sections were incubated with monoclonal antibody at 1:100 dilutions [DAKOTM, Code No. M 7001, Lot 056 at a dilution of 1:100] overnight at 4°C. After washing in Tris buffer, sections were incubated one hour with biotinylated secondary antibodies (Dako), followed by the incubation with avidin–biotin–horseradish peroxidase complex (Dako).

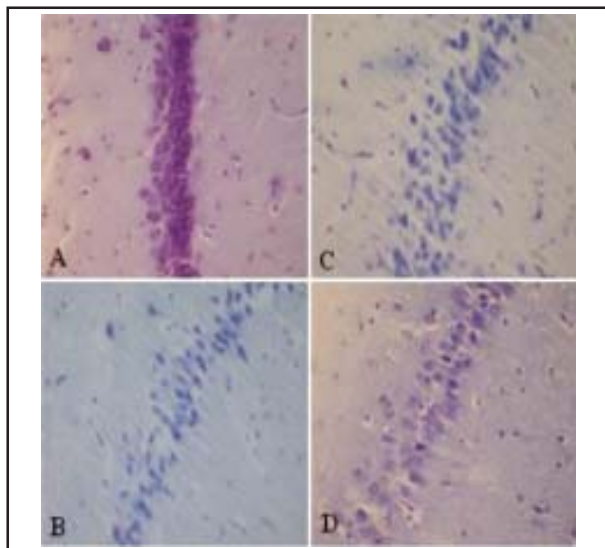


Fig-1: Histopathological changes in CA1 subfield of hippocampus from sham-operated (A) controls 1, 2 (B, C) and ADFE-pretreated group (D). Magnification × 400, Nissl staining.

The antigens were visualized by reaction with three, 3'-diaminobenzidine tetrahydrochloride (DAB, 0.05%) as a chromogen and hydrogen peroxide (0.003%), and contrasted with Mayer haematoxylin. Sections were dehydrated through graded ethanol and cover slipped with DPX.¹³

A sample of sections was reacted without primary antiserum as negative control. For positive control, sections from breast cancer were selected and used.

Statistical analysis: All statistical analysis was carried out using SPSS version 11.5. Differences in measured parameters among different groups were analyzed by one-way ANOVA. The differences were considered to be significant when the probability was less than 0.05.

RESULTS

Histological findings: In the sham group, the morphology of pyramidal neurons in hippocampal CA1 region (Fig-1 A) was normal. Meanwhile, most of pyramidal neurons in control groups showed severe degenerative changes including: shrunken cytoplasm and extensively dark picnotic nuclei (Fig-1 B and C).

In experimental groups the severity of degenerative changes in cytoplasm and nucleus were less than those in control group, especially

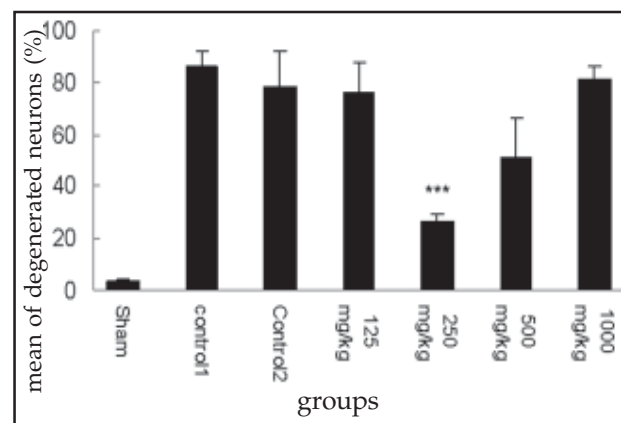


Fig-2: Effect of ADFE on hippocampal CA1 cell death induced by 30minutes MCAO followed by 48 hour reperfusion. Results are expressed as mean± S.E and data were analyzed by One-way ANOVA and followed by Bonferroni multiple comparisons test.

Significantly different from control one.***

with the dose of 250mg/kg of ADFE (Fig-1 D). Neuronal counting findings showed significant difference between 250mg/kg of ADFE group compared to control group ($p < 0.000$) (Fig 2). *Immunohistochemistry findings:* Immunoreactive p53 of pyramidal neurons were not found in CA1 subfield of any groups (Fig-3).

DISCUSSION

As a consequence of focal cerebral ischemia and particularly when reperfusion occurs, oxygen radicals are produced during enzymatic conversions, such as cyclooxygenase dependent conversion of arachidonic acid to prostanoids.¹⁴ Oxygen radicals serve as important signaling molecules that trigger inflammation and apoptosis.¹⁵ Apoptosis can be induced by increased expression of a mutant p53.¹⁶ It has been reported that low antioxidant activity in plasma is associated with higher lesion volumes and neurological impairments in stroke patients.¹⁷ Pretreatment with antioxidant chemicals reduced ischemia brain injury.¹⁸ The results of this study demonstrated for first time that intake of ADFE can protect neurons against ischemia-reperfusion induced insults. According to the results obtained 30 minutes of MCAO induced intensive neuronal damage in hippocampal CA1 neurons (about 86%) and this finding is in agreement with other studies.^{19,20}

Pretreatment of the animals with ADFE showed significant decrease of neural death in CA1 hippocampal neurons (60%) comparing to control group. Maximum protective effects of ADFE were observed with dose of 250mg/kg and with lower protective effect with dose of 500mg/kg. Meanwhile, ADFE with dose of 1000 mg/kg showed negative effect which may be due to high concentration of antioxidants that may be harmful.²¹

In ischemia stroke and some of neurodegenerative disorders a shared biochemical cascade of events appears to carry out the neuronal cell death process. Evidence for a pivotal function of p53 in neuron death in many neurodegenerative diseases is provided by data from in vitro and in vivo models documenting increased p53 levels in the affected neurons.²²

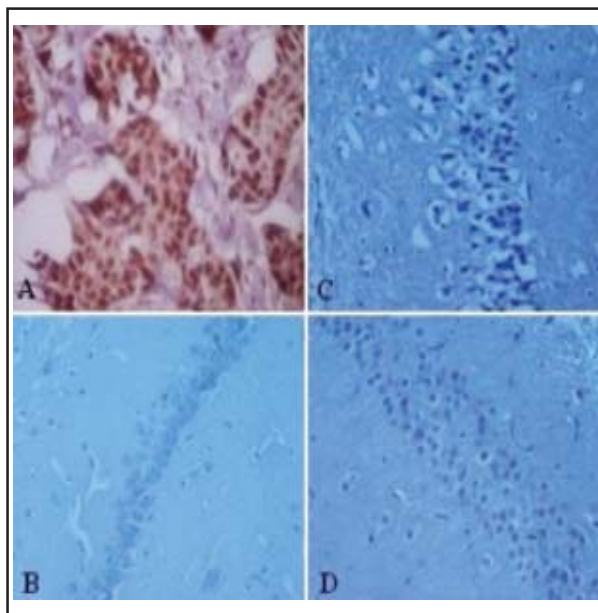


Fig-3: Immunohistochemical analysis of p53 in CA1 subfield of rat hippocampus from positive control (A), negative control (B), Control 1 (C) and ADFE pre-treated groups (D). Magnification $\times 400$.

According to immunohistochemical findings of this study, the neuronal death pathway may be due to necrotic mechanism. Some of known neuroprotective agents of ADFE are melatonin, a potent antioxidant and free radical scavenger with special tendency to brain,¹¹ Phenolic compounds consist of cinnamic acids and different flavonoids with strong antioxidant properties,³ Vitamin C, a known antioxidant compound,²³ Magnesium, an antagonist of NMDA receptors,²⁴ Vitamin B₃, a water-soluble vitamin with neuroprotective property,²⁵ manganese, a free radical scavenger,²⁶ selenium, an antioxidant agent with synergic effect with vitamin C.²⁷ Considering the existence of the different compounds, ADFE is a unique natural complex neuroprotective agent. In this study, we pretreated the animals with ADFE for two weeks before ischemia. It seems that different neuroprotective mechanisms may be involved that the diet could be having an antioxidant or anti-inflammatory effect.

However, the protective mechanism and related factors are not known precisely but the synergic effect of various antioxidative constituents of ADFE may explain its neuroprotective

mechanism. Further investigation should be designed to clarify the precise mechanism. Apparently, the present study has demonstrated that 250mg/kg dose of ADFE reduce the rate of neuronal death in CA1 hippocampus following focal cerebral ischemia. This is another effect of dates as a unique and useful fruit so its regular consumption may be helpful for health.

ACKNOWLEDGMENT

This study was supported by the Jondishapour Ahwaz University, Medical research service with grant number. 85U087.

REFERENCES

- Schmidt-Kastner R, Freund TF. Selective vulnerability of the hippocampus in brain ischemia. *Neurosci* 1991;40(3):599-636.
- Gemma C, Mesches MH, Sepesi B, Choo K, Holmes DB, Bickford PC. Diets enriched in foods with high antioxidant activity reverse age-induced decrease in cerebellar-adrenergic function and increases in proinflammatory cytokines. *J Neurosci* 2002;22(14):6114-120.
- Mansuri A, Embarek G, Kokkallon E, Kefalas P. Phenolic profile and antioxidant activity of the Algerian ripe date palm fruit (*Phoenix dactylifera*). *Food Chem* 2005;89:411-20.
- Al-Shahib W, Marshall R. The fruit of the date palm: its possible use as the best food for the future? *Int J Food Sci and Nutr* 2003;54:247-59.
- Vayalil PK. Antioxidant and antimutagenic properties of aqueous extract of date fruit (*Phoenix dactylifera* L. *Arecaceae*). *J Agric and Food Chem* 2002 50:610-17.
- Sallal AK, Ashkenani A. Effect of date extract on growth and spore germination of *Bacillus Sabtilis*. *Microbios* 1989; 59:203-210.
- Sallal AK, El-Teen KH, Abderahman S. Effect of date extract on growth and morphology of *Candida albicans*. *Biomed Lett* 1996;53:119-23.
- Ishurd O, Kennedy JF. The anti-cancer activity of polysaccharide prepared from Libyan dates (*Phoenix dactylifera* L.). *Carbo Polym* 2005;59:531-3.
- Al-Qarawi AA, Abdel-Rahman H, Ali BH, Mousa HM, El-Mougy SA. The ameliorative effect of dates (*Phoenix dactylifera* L.) on ethanol-induced gastric ulcer in rats. *J Ethnopharmacol* 2005;98:313-17.
- Lipartiti M, Franceschini D, Zanoni R, Gusella M, Giusti P, Cagnoli CM, et al. Neuroprotective effects of melatonin. *Adv Exp Med Biol* 1996;398:315-21.
- Longa EZ, Weinstein PR, Carlson S, Cummins R. Reversible middle cerebral artery occlusion without craniotomy in rats. *Stroke* 1989;20:84-91.
- Sakurai-Yamashita Y, Kinugawa H, Niwa M. Neuroprotective effect of pentosan polysulphate on ischemia-related neuronal death of hippocampus. *Neurosci Lett* 2006;409:30-4.
- Uberti D, Piccioni L, Colzi A, Bravi D, Canonico PI, Memo M. p53 is dispensable for apoptosis but controls neurogenesis of mouse dentate gyrus cells following gamma-irradiation. *Mol Brain Res* 2001;10:93(1):81-9.
- Lo CJ, Lin JG, Kuo JS, Chiang SY, Chen SC, Liao ET, et al. Effect of *salvia miltiorrhiza bunge* on cerebral infarct in ischemia-reperfusion injured rats. *Am J Chin Med* 2003;31(2):191-200.
- Dirnagl U, Ladecola C, Moskowitz MA. Pathobiology of ischaemic stroke: An integrated view. *Trends Neurosci* 1999;22(9):391-7.
- Li B, Greenberg N, Stephens LC, Meyn R, Medina D, Rosen JM. Preferential overexpression of a 172Arg→Leu mutant p53 in the mammary gland of transgenic mice results in altered lobuloalveolar development. *Cell Growth Differ* 1994;5(7):711-21.
- Leinonen JS, Phonon JP, Linnet K, Jehkonen M, Dastidar P, Molnar J et al. Low plasma antioxidant activity is associated with high lesion volume and neurological impairment in stroke. *Stroke* 2000;31(1):33-9.
- Yoshida H, Yanai H, Namiki Y, Fukatsu-Sasaki K, Furutani N, Tada N. Neuroprotective effects of edaravone: a novel free radical scavenger in cerebrovascular injury. *CNS Drug Rev* 2006;12(1):9-20.
- Al-Majed AA, Al-Omar FA, Nagi MN. Neuroprotective effects of thymoquinone against transient forebrain ischemia in the rat hippocampus. *Eur J Pharmacol* 2006;14:543(1-3):40-7.
- Knuckey NW, Palm D, Primiano M, Epstein MH, Johanson CE. N-acetylcysteine enhances hippocampal neuronal survival after transient forebrain ischemia in rats. *Stroke* 1995;26(2):305-10.
- Kuhn MA. Oxygen free radicals and antioxidants. *Am J Nutrition* 2003;103(4):58-62.
- Morrison RS, Kinoshita Y, Johnson MD, Guo W, Garden GA. P53-dependent cell death signaling in neurons. *Neurochem Res* 2003;28:15-27.
- Aydin N, Aydin N, Aydin MD, Yildirim U, Onder A, Kirpinar I. Neuroprotective effects of vitamin C on injured hippocampal neurons by impulse noise: experimental study. *Eur Neuropharmacol* 2005;15(3):S640.
- Lyden P, Wahlgren NG. Mechanisms of action of neuroprotectants in stroke. *J Stroke and Cerebrovasc Dis* 2000;9(6):9-14.
- Sakakibara Y, Alim PM, Ayoub IA, Ogilvy CS, Maynard KI. Delayed treatment with nicotinamide (vitamin B3) reduces the infarct volume following focal cerebral ischemia in spontaneously hypertensive rats, diabetic and non-diabetic Fischer 344 rats. *Brain Res* 2002;931(1):68-73.
- Rauhala P, Chiueh CC. Effects of atypical antioxidative agents, S-nitrosoglutathione and manganese, on brain lipid peroxidation induced by iron leaking from tissue disruption. *Ann N Y Acad Sci* 2000;899:238-54.
- Gupta R, Singh M, Sharma A. Neuroprotective effect of antioxidants on ischaemia and reperfusion-induced cerebral injury. *Pharmacol Res* 2003;48(2):209-15.