

NEW METHOD IN LAPAROSCOPIC SURGERY OF XANTHOGRANULOMATOUS PYELONEPHRITIS

Siavash Falahatkar¹, Sara Nikpour², Marzieh Akbarpour³

ABSTRACT

Laparoscopic surgery for Xanthogranulomatous pyelonephritis (XGP) is a difficult one so it seems that our experience may be helpful in other similar surgeries. The patient was a 75 years old woman who had right flank pain, several stones were observed in her kidney via IVU (Intra Venous Urogram). The patient underwent transperitoneal laparoscopic nephrectomy and on pathology, XGP was reported. Total nephrectomy is the treatment of choice for XGP, but it is usually contraindicated for laparoscopic or retroperitoneoscopic techniques. We propose that in laparoscopic surgery of XGP, the ureter should be preserved until the end of procedure in order to use it as a handle. Also the adhesion of the superoposterior of kidney should not be free before ligaturing the pedicle. We suggest that in laparoscopic surgery of XGP, in case of difficulties in dissection of artery and vein, we could initially clamp and cut the vein, then ligator and cut the artery.

KEY WORD: Xanthogranulomatous pyelonephritis, Laparoscopic surgery, Ligate pedicle.

Pak J Med Sci October - December 2007 (Part-II) Vol. 23 No. 6 953-955

INTRODUCTION

Xanthogranulomatous pyelonephritis (XGP) is an atypical and severe form of chronic renal infection characterized by destruction of the renal parenchyma and its replacement by masses of lipid laden macrophages.¹ The clinical presentation is nonspecific, and investigation often reveals a nonfunctional kidney. Pre-operative diagnosis is very difficult even with ultrasonography and computed tomography. Total nephrectomy is the treatment of choice.² Although the laparoscopic approach has been successfully used in other inflammatory renal

conditions such as tuberculosis, XGP remains a relative contraindication to laparoscopy.³ It is considered very difficult and is usually contraindicated for laparoscopic or retroperitoneoscopic techniques.² The laparoscopic approach has been used in cases of XGP but with increased complications and operative time.⁴

During the recent years, few reports of laparoscopic surgery of XGP were noted. At the present time the laparoscopic surgery of XGP remains difficult and complicated. We report a case of XGP that was managed with pedicle control in laparoscopic surgery.

CASE REPORT

The patient was a 75 years old woman who had right flank pain with radiation to suprapubic from one month before referring to urology clinic. She had no urinary symptoms and in past medical history she had hypertension and there was no renal colic pain. In familial history she had no significant disease. In physical examination, there was no positive point. She had pyuria in urinalysis. Urine culture was negative due to use of antibiotics. In IVP right

1. Dr. Siavash Falahatkar, Associate Professor,
 2. Dr. Sara Nikpour, MD,
 3. Dr. Marzieh Akbarpour, MD
- 1-3: Urology Research Center, Razi Hospital, Rasht - Iran.

Correspondence

Dr. Siavash Falahatkar,
E-mail: falahatkar_s@yahoo.com

- * Received for Publication: April 9, 2007
- * Revision Received: October 20, 2007
- * Revision Accepted: October 26, 2007

kidney was not visualized and several stones were reported. In radioisotope scan non functional right kidney was reported (Fig-1).

The patient underwent transperitoneal laparoscopic nephrectomy and several stones were observed in her kidney. At the time of surgery there was a dense adhesion. The kidney had two main veins and an artery. During tissue dissection we found fragile vessels due to dense adhesion that might be to induce uncontrolled hemorrhage. There was bleeding in an accessory vein that was controlled immediately. Because of inflammation and severe adhesion around the kidney's vessels, we ligated the main veins after minimal dissection then they were transected and after that the main artery was exposed then it was ligated and transected without releasing it. In this way operation time was reduced by twenty minutes.

On pathology, renal parenchyma was diffusely destroyed which was replaced by adipose tissue, dense collection of foamy histiocytes, dense infiltration of MNC's, extravasation of RBC's and foci of calcification. The diagnosis of Xanthogranulomatous pyelonephritis was made (Fig-2).

DISCUSSION

Xanthogranulomatous pyelonephritis is a rare atypical form of chronic pyelonephritis characterized by destruction of renal parenchyma with replacement by granulomatous tissue containing lipid-laden macrophages.⁵ XGP is classified as diffuse (92%) or focal (8%).⁶ XGP is further divided into three stages: stage I (nephric XGP), corresponds to inflammation

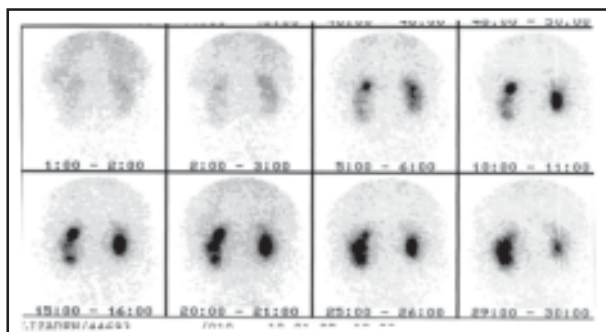


Fig-1: Radioisotope scan of right kidney

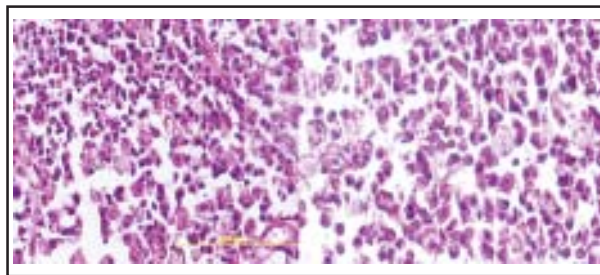


Fig-2: Pathologic slides of XGP

confined to the kidney; stage II (perinephric XGP), the inflammation involves both the kidney and perirenal fat; stage III (paranephric XGP), the inflammation involves the kidney, perirenal fat, and the retroperitoneum.

The etiology of XGP is poorly understood. The most common associated factors are urinary tract obstruction, infection, and renal calculi.^{5,7,8} Causes of obstruction include renal calculi, congenital abnormalities such as ureteropelvic junction obstruction, and tumors that occur mainly in the adult population (renal cell carcinoma, ureteral carcinoma, bladder carcinoma).⁵ Urinary tract infections with *E. coli* and *Proteus* species are the infectious agents most commonly related to XGP, found in 59% to 95% of positive cultures.^{5,7,8}

Pyuria is present in 60% to 90% of patients.^{5,7} The most common physical examination findings include a palpable mass and flank tenderness.^{5,6} Less than one half of patients present with hypertension.^{5,7}

The final diagnosis is only available after histopathologic examination of the resected specimen in most cases.⁴ Nephrectomy is the treatment of choice. Because of the renal and perirenal inflammatory changes that commonly accompany XGP the laparoscopic approach is difficult.⁹ Shekarriz et al, studied the role of laparoscopy in inflammatory renal conditions. Of 12 patients who had a histologic diagnosis of XGP, three underwent laparoscopic nephrectomy, with conversion to open surgery required in one patient. The mean hospital stay and length of convalescence were not different from those of patients with other inflammatory conditions.³ Khaira et al reported that the treatment of some XGP cases with laparoscopic nephrectomy is a possible, albeit

challenging, option. The incidence of intraoperative and postoperative complications were roughly equivalent in the laparoscopic and open-surgery patients in their study.⁹ In our experience no complications such as conversion to open surgery, ileus and pulmonary embolism, retroperitoneal hemorrhage and abscess formation were observed.

Bercowsky et al performed laparoscopic nephrectomy in four patients. Complications were reported in three patients. Failure to progress during laparoscopic surgery is one indication for conversion to the open approach. Keely and Tolley stated that they no longer offered laparoscopic nephrectomy to patients with suspected XGP.¹⁰

In the study performed by Kapoor R, Laparoscopic nephrectomy for XGP was successful in 80% of the cases. The dissection of the kidney was comparatively difficult in all cases because of dense adhesions in the perirenal region and required modification of the technique. The incidence of major complications was 20% and 10% in the open and laparoscopic groups, respectively. The mean hospital stay in the laparoscopic group was 3.8 days, significantly less than that for the open nephrectomy group (8.2 days). The mean operative time in the laparoscopic group was 3.8 hours compared with 2.5 hours in the open group. They concluded that although a longer operative time is required because of perinephric adhesions, the postoperative recovery is faster and cosmesis superior compared with the open approach. Modifications in the standard laparoscopic technique can be made to complete the procedure successfully and safely.³ Our operative time was 3.5 and the patient was discharged after 48 hours.

Laparoscopic nephrectomy for XGP is complicated and more technically demanding than the laparoscopic nephrectomy for noninfectious etiologies. Consideration should be made for using a hand port should the laparoscopic procedure fail to progress in a satisfactory manner. In experienced hands, the laparoscopic approach presents a reasonable surgical option for the treatment of XGP.¹¹ In the dense

inflammatory state of XGP, dissection of the renal hilum can be very difficult. Hand assisted technique and the harmonic scalpel were the most helpful intraoperative measures in approaching the hilar vessels. Brian et al didn't transect the hilar vasculature en masse but used a laparoscopic vascular stapler to ligate the renal artery and vein separately.¹⁰

This experience showed us that in difficult nephrectomy it is not necessary to release vessels completely, in addition it is possible to ligate vein prior to artery. In this way we could reduce the operation time and risk of bleeding. We suggest that in laparoscopic surgery of XGP, the ureter should be preserved until the end of procedure in order to use it as a handle. Also the adhesion of the superoposterior of kidney should not be free before ligating the pedicle. This issue may help us to complete the surgery.

REFERENCES

1. Petronic V, Buturovic J, Isvaneski M. Xanthogranulomatous pyelonephritis. *Br J Urol* 1989;64:336-68.
2. Merrot T, Ordorica-Flores R, Steyeart H, Ginier C, Valla JS. Is diffuse xanthogranulomatous pyelonephritis a contraindication to retroperitoneoscopic nephroureterectomy? A case report. *Surg Laparosc Endosc* 1998;8(5):366-9
3. Shekarriz B, Meng MV, Lu H. Laparoscopic nephrectomy for inflammatory renal conditions. *J Urol* 2001;166:2091-4.
4. Kapoor R. Is laparoscopic nephrectomy the preferred approach in xanthogranulomatous pyelonephritis. *Urology* 2006;68:5,952-5
5. Levy M, Baumal R, Eddy AA. Xanthogranulomatous pyelonephritis in children. *Clin Pediatr* 1994;33(6):360-6.
6. Samuel M, Duffy P, Capps S. Xanthogranulomatous pyelonephritis in childhood. *J Pediatr Surg* 2001;36(4):598-601.
7. Brown PS, Dodson M, Weintraub PS. Xanthogranulomatous pyelonephritis: Report of nonsurgical management of a case and review of the literature. *Clin Infect Dis* 1996;22(2):308-14.
8. Rafal RB, Kosovsky PA, Markisz JA. Xanthogranulomatous pyelonephritis in an infant. *Urology* 1991;37:553-6.
9. Khiara HS, Shah RB, Wolf JS. Laparoscopy and open surgical nephrectomy for xanthogranulomatous pyelonephritis. *J Endourol* 2005;19:813-7.
10. Brian A. Vanderbrink. Laparoscopic versus open radical nephrectomy for xanthogranulomatous pyelonephritis: contemporary outcomes analysis. *J Endourology* 2007;121:65-70.
11. Rosoff JS, Raman JD, Del Pizzo JJ. Feasibility of laparoscopic approach in management of xanthogranulomatous pyelonephritis. *Urology* 2006;68(4):711-4.