

## INVESTIGATION OF PROTECTIVE EFFECT OF PREDNISOLONE IN NEPHROPATHY INDUCED BY CO-TRIMOXAZOLE IN RAT

Alireza Mozaffari<sup>1</sup>, Iran Rashidi<sup>2</sup>

### ABSTRACT

**Objectives:** Co-trimoxazole is a sulfonamide derivative, which is used as an antibacterial drug. Prednisolone is a dermo-corticosteroid derivative, which is widely used as an anti-inflammatory and in the treatment of allergic reaction and collagen vascular diseases. The aim of this study was to find out the effect of co-trimoxazole on the renal interstitium and protective effect of prednisolone in rat.

**Methodology:** Four groups of animal were selected, namely A, B, C and control group. Groups A and B were treated with co-trimoxazole (150mg/Kg sulfa methoxazole + 30mg/Kg trimethoprim) while group C was treated with Co-trimoxazole and prednisolone (4mg/Kg) for 10 days. The reference group only received some dose of water. The blood samples were collected from groups A and C, 24 hours and from group B, 14 days after the last dose of drug were administered. Microscopic samples from kidney tissue were prepared. The slides staining was done with Hematoxylin and Eosine (H&E) stain for histopathological study.

**Results:** The creatinine level in serum of group A (1.54) showed a significant increase as compared with the control group (1.04). In the group that received co-trimoxazole the histopathological study showed acute interstitial nephritis (AIN). In the group that was treated with co-trimoxazole + prednisolone showed no histopathological changes.

**Conclusion:** The results from present study, support the theory that AIN is drug allergic reaction when co-trimoxazole is used.

**KEY WORDS:** Co-trimoxazole, Prednisolone, Rat, Histopathology, Creatinine.

Pak J Med Sci October - December 2007 (Part-II) Vol. 23 No. 6 847-850

### INTRODUCTION

Sulfonamides are a group of antimicrobial drugs, which are widely used now a days. Among the more often used sulfonamides is co-trimoxazole. A stimulation of interstitial

tissue of kidney by co-trimoxazole has been reported. Sulfonamide for the first time was prepared in 1908 by Gelmo during a research work on azo dyes. In 1932 it was found that prontosyl has a strong bacteriostatic property and this has led to one of the most important achievements in the history of chemotherapy. Terfonil, Kitty and Loven have reported that the antimicrobial effect of prontosyl is related to its sulfonamide part and that azo dyes of prontosyl type are reduced to sulfanilamide in animal body. Now a days with changes in their molecular structure, thousands of sulfonamide derivatives have been prepared synthesized.<sup>1</sup>

Co-trimoxazole is prepared by 5 to 1 ratios of sulfamethoxazole and trimethoprim respectively. It is absorbed 90-100 percent through

1. Dr. Alireza Mozaffari  
Department of Internal Medicine,  
Golestan University Hospital, School of Medicine,
2. Dr. Iran Rashidi  
Department of Pathology, School of Medicine,
- 1,2: Ahwaz Jondishapour University of Medical Sciences  
Ahwaz - Iran.

Correspondence

Dr. Alireza Mozaffari  
E. mail: ali\_mozaffari2003@yahoo.com

- \* Received for Publication: June 4, 2007
- \* Revision Received: October 2, 2007
- \* Revision Accepted: October 16, 2007

linking to protein and its metabolism is in liver. The half-life of sulfamethoxazole is 6-12 hours while for trimethoprim it is 8-10 hours. The maximum softness of both of them occurs within 2-4 hours after taking the drug. Eventually, they are excreted from kidney via glomerular and tubular secretion.<sup>2,3</sup>

Prednisolone is a glucocorticoid drug that has a considerable capability in controlling inflammation and immune phenomena. It prevents sticking of neutrophils to endothelium of vessels and reduces their movement from vessels to inflammation areas. Also, with controlling the providing system of antigens by macrophages and control the activity of lymphokines and with increasing the synthesis of lipomyolin which is itself a controller for the release of arachidonic acid from phospholipids of cell membrane through phospholipase A2 enzyme, cause a decrease in synthesis of the related derivatives i.e. prostaglandin and leukotriene, and in so doing prevents inflammation.<sup>4</sup>

In kidney in some infections and sensitivity to some drugs, changes happen in structure and function of renal tissue. In its acute case, edema of interstitial tissue can be seen which is usually along with infiltration of polymorphonuclear leucocytes in medulla of kidney and more often dispersed necrosis of tubular cells. In its chronic form fibrosis of interstitial tissue is more evident and inflammatory cells in secretion are mainly mononuclear, and also tubular changes are more developed.<sup>5</sup>

In this study, we have tried to investigate the damage induced by co-trimoxazole in laboratory animals (rat) from a pathological point of view. Also the effect of prednisolone in prevention of this damage in interstitial tissue of kidney has been studied.

## METHODOLOGY

In this study, we used N. Mari type rat supplied by Razi Institute, Tehran Iran. The weight of animals was in the range of 150-180 grams. Animals were kept in special metal cages in animal room, where a cycle of 12 hour light and 12 hour darkness was imposed. The

required amount of co-trimoxazole and prednisolone was determined according to animal's weight as 150+30mg/Kg and 4mg/Kg, respectively. An analytical balance was used for this purpose and the materials were kept out of light and moisture.

Groups A and B were treated with co-trimoxazole orally (150+30mg/Kg/day) for 10 days, while group C was at first treated with prednisolone (4mg/Kg/day) and every time after one hour the required dose of co-trimoxazole was also given. The control group received only distilled water during the 10 days period.

Anesthetization using ether was carried out on groups A and C 24 hours and on group B 14 days after the last dose of drug was given. Blood sample was taken from heart and then animal was sacrificed and the kidneys were taken out for further examination. The kidneys were washed in physiological serum and then were fixed in 10% solution of Formalin. The slides were stained with Hematoxylin and Eosine (H&E) for histopathological evaluation. Blood serum was collected from different groups and was sent for laboratory analysis to determine the level of BUN and creatinine an auto analyzer RA-1000 instrument was used for this purpose.

## RESULTS

Based on the results obtained, we could not find significant difference between BUN concentration among control group and A, B and C groups, which reflects that Co-trimoxazole did not have a considerable effect on BUN concentration of the serum (Table-I).

The measurement of creatinine has shown a significant difference of creatinine level between group A and control group, while this difference was not significant for group B and

Table-I: Serum B.U.N\*

Groups	N	Mean	S.D	S.E
Control	5	20	1.48	0.661
Group A	5	22	1.58	0.706
Group B	5	21.4	3.9	1.74
Group C	5	22.4	2.3	1.2

\* BUN: blood urea nitrogen

Table-II: Serum Creatinine

Groups	N	Mean	S.D	S.E
Control	5	1.04	0.16	0.071
Group A	5	1.54	0.15	0.067
Group B	5	1.14	0.26	0.116
Group C	5	1.18	0.19	0.084

C compared to control group. This means that there was a considerable increase in creatinine level of serum during the use of the drug, which returned to its normal serum level as prednisolone is used simultaneously (Table-II). The histological results showed interstitial nephritis in various groups treated by co-trimoxazole and in normal kidney in the group which had received co-trimoxazole + prednisolone (Table-III) (Figures 1-2).

### DISCUSSION

Research has shown that interstitial tissue of kidney is susceptible to damage by poisons and drugs which are among the important agents for stimulation of this tissue. Sulfonamide Co-trimoxazole is introduced as important agents for stimulation of interstitial tissue of kidney.<sup>6</sup>

In 1979 report concerning poisonous effects of Co-trimoxazole had been published that it can induce interstitial nephritis.<sup>7</sup> In 1994 during it was claimed that simultaneous use of co-trimoxazole and gentamycin in rat can reduce kidney damage and BUN increase, related to taking of gentamycin induced subclinical tubulitis.<sup>8</sup>

This study aimed to investigate the stimulation of interstitial tissue of kidney induced by co-trimoxazole. The status of being acute or chronic and / or allergic and the role of steroid type drugs in prevention of this stimulation have also been of interest. The extent of allergic reaction induced by drug in human depends on the nature of drug, method of tak-

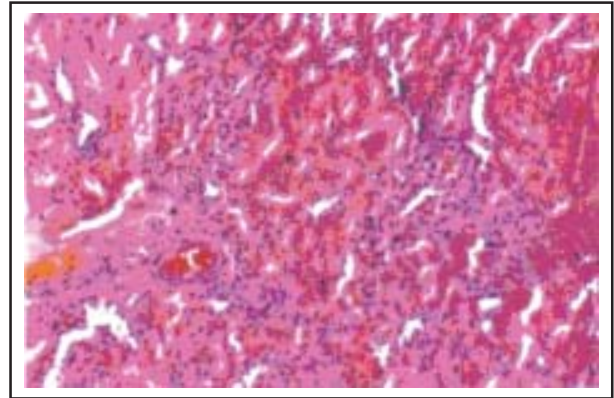


Figure-1: Renal tissue in rat that used Co-trimoxazole (H&E stain)

ing, genetic characteristics of the person and previous dose of consumption.<sup>9,10</sup> In acute stimulation, it is believed that an immunity mechanism is responsible for this damage.<sup>11</sup> Considering the cause of acute stimulation of interstitial, it is diagnosed with a wide variety of symptoms such as hypertension, fever, rash, increasing creatinine level and acute inefficiency of kidney.<sup>12</sup> Statistical investigation shows that about 15% of the cases involved with acute tubular necrosis (ATN) leads to acute renal failure.<sup>13</sup> However, Co-trimoxazole, which can cause an ATN through an allergic reaction, may not have many of clinical symptoms. In this case the damage can only be diagnosed with biopsy.<sup>14</sup>

The possible mechanism for interstitial nephritis can be expressed when Co-trimoxazole is used, microcrystal are formed inside the kidney,<sup>8</sup> which plays an antigen role. So the antibody which is produced against that, causes the above mentioned damage.<sup>10</sup> On the other hand it is possible that autoimmune reactions with the action of drug as Hapten and linking to kidney tissue and intervention of lymphocyte T, B through an allergic reaction can cause the damage to interstitial tissue of kidney.<sup>15</sup>

Table-III: Histopathological analysis of kidney tissue in different groups

Tissue change	Edema	FR	E	L	N	Tubular damage	Congestion	Hyaline cast
Control	-	-	-	-	-	-	-	-
Group A	+	+	+	+	+	+	+	+
Group B	-	-	-	+	-	-	+	-
Group C	-	-	-	-	-	-	-	-

FR: Fibroblast reproduction; E: Eosinophil; L: Lymphocyte; N: Neutrophil

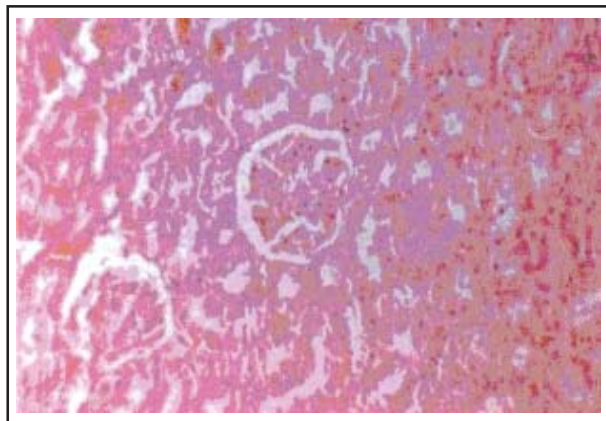


Figure-2: Renal tissue in rat that used co-trimoxazole + prednisolone (H&E stain)

Results from this and the previous research works confirmed that more care must be taken in consumption of this drug and perhaps this was the reason that in March 1986 British national formulary restricted the use of Co-trimoxazole for adult's.<sup>16</sup> In July 1995 the officials in charge of issuing license for using drugs announced that except for *Pneumocystis pneumonia* there are a few cases that drug is preferred as a simple antibiotic.<sup>17</sup>

Since we could not find any similar work regarding the application of prednisolone, hence we feel that all the effects we have seen, is strongly the sign of an interstitial nephritis, which is caused because of an immunological reaction. So any immune system suppression may be able to reduce the toxicity of Co-trimoxazole. In our study, prednisolone as an immune suppressor was able to reduce the damages caused by this antibiotic.

Finally, it is suggested that before prescribing the drug, full history of kidney disease should be taken besides clinical symptoms. BUN and creatinine of the patient under treatment with Co-trimoxazole is controlled. It is suggested to investigate the effect of Co-trimoxazole dosage in causing kidney damage to understand the usefulness of application of Co-trimoxazole and prednisolone for prevention of kidney damage in patients. Where possible it is useful to compare patient under treatment with Co-trimoxazole with normal people using immunologic experiments.

## REFERENCES

1. Fauci A, Hauser SL. Acute renal failure. In: Harrison's Principles of Internal Medicine. 16th Ed. New York: McGraw-Hill Professional Publishing 2005;1702-6.
2. Co-trimoxazole Injection; Med Master™ Patient Drug Information database provides information copyrighted by the American Society of Health-System Pharmacists, Inc., Bethesda, Maryland Copyright© 2004.
3. Masters PA, O'Bryan TA, Zurlo J, Miller DQ, Joshi N. Trimethoprim-Sulfamethoxazole Revisited. *Arch Intern Med* 2003;163:402-10.
4. Mann SB, Chung FK. Blood Neutrophil activation markers in severe asthma: lack of inhibition by prednisolone therapy; Published online 2006;6:10.1186/1465-9921-7-59.
5. Fonseca LE, Shapiro R, Randhawa PS. Occurrence of urinary tract infection in patients with renal allograft biopsies showing neutrophilic tubulitis. *Modern Pathology* 2003;16:281-5.
6. Albright RC. Acute renal failure: a practical update. *Mayo Clin Proc* 2001;76:67-74.
7. Richmond J, Withworth JA, Fairley KF, Kincaid S: Co-trimoxazole nephrotoxicity. *Lancet* 1979;1:493.
8. Shapiro R, Randhawa P, Jordan M, Scantlebury V, Vivas C, Jain A, et al. An analysis of early renal transplant protocol biopsies – the high incidence of subclinical tubulitis. *Am J Transplantation* 2001;1:47-50.
9. Tepel M, Vander GM, Schwarzfeld C, Laufer U, Liermann D, Zidek W. Prevention of radiographic-contrast-agent-induced reductions in renal function by acetylcysteine. *N Engl J Med* 2000;343:180-4.
10. Meduri GU, Tolley EA, Chrousos GP, Stentz F. Prolonged methylprednisolone treatment suppresses systemic inflammation in patients with unresolving acute respiratory distress syndrome: Evidence for inadequate endogenous glucocorticoid secretion and inflammation-induced immune cell resistance to glucocorticoids. *Am J Respir Crit Care Med* 2002;165:983-91.
11. Andersson AK, Chaduvula MV, Atkinson SE, Khanolkar-Young S, Jain S. Effects of Prednisolone treatment on cytokine expression in patients with leprosy type 1 reactions. *Infection and Immunity* 2005;73:3725-33.
12. Margassery S, Bastani B. Life threatening hyperkalemia and acidosis secondary to trimethoprim-sulfamethoxazole treatment. *J Nephrol* 2001;14:410-4.
13. Hemstreet BA. Antimicrobial-Associated Renal Tubular Acidosis. *The Annals of Pharmacotherapy* 2004;38:1031-8.
14. Geevasinga N, Kairaitis L, Rangan GK, Coleman PL. Acute interstitial nephritis secondary to esomeprazole. *The Med J Australia* 2005;182:235-6.
15. Kelly B. Nephrotoxic acute tubular necrosis. *Current Medical Diagnosis & Treatment*. New York: McGraw-Hill Professional Publishing 16:2006.
16. Jayne DRW, Chapel H, Adu D, Misbah S, O'Donoghue D, Scott D, et al. Intravenous immunoglobulin for ANCA-associated systemic vasculitis with persistent disease activity. *QJM* 2000;93:433-9.
17. Masters PA, O'Bryan TA, Zurlo J, Miller DQ, Joshi N. Trimethoprim-Sulfamethoxazole Revisited. *Arch Intern Med* 2003;163:402-10.