

## THE PROTECTIVE EFFECT OF CETIRIZINE AGAINST BLEOMYCINE INDUCED PULMONARY FIBROSIS IN RATS

Ali Asghar Hemmati<sup>1</sup>, Peyman Mikaili<sup>2</sup>, Mohammad Javad Khodayar<sup>3</sup>, Mehri Ghafurian<sup>4</sup>, Iran Rashidi<sup>5</sup>

### ABSTRACT

**Objective:** To evaluate the protective effect of cetirizine against bleomycin induced pulmonary fibrosis in rats.

**Methodology:** Male Sprague-Dawley rats (n=30), received an intratracheal injection of bleomycin (7.5 IU/kg) in saline solution for induction of pulmonary fibrosis. Two treatment groups received daily cetirizine five and 20mg/kg/day, seven days before and four weeks after administering a single-dose bleomycin (7.5IU/kg). The cytokines (IL-8, TNF- $\alpha$ , TGF- $\beta$ 1) through ELISA kits, the amount of collagen in the lungs (hydroxyproline content), and pharmacological activity of the lung strip tissues were determined.

**Results:** The cytokine levels have been decreased in the treated groups by cetirizine 5 (p< 0.05) and 20 (p<0.01) mg/kg/day, in comparison to positive control group.

**Conclusions:** Cetirizine may have a protective effect against bleomycin induced pulmonary fibrosis as evident by the reduction of the severity of lung tissue changes, collagen amounts and cytokines levels caused by bleomycine in rats lungs tissues.

**KEYWORDS:** Pulmonary fibrosis, Bleomycine, Cetirizine, Cytokines.

Pak J Med Sci October - December 2008 (Part-II) Vol. 24 No. 6 813-820

### How to cite this article:

Hemmati AA, Mikaili P, Khodayar MJ, Ghafurian M, Rashidi I. The protective effect of Cetirizine against Bleomycine induced pulmonary fibrosis in rats. Pak J Med Sci 2008;24(6):813-20.

1. Ali Asghar Hemmati,
  2. Peyman Mikaili,
  3. Mohammad Javad Khodayar,  
Dept. of Pharmacology & Toxicology, School of Pharmacy,
  4. Mehri Ghafurian,  
Department of Immunology,
  5. Iran Rashidi,  
Department of Pathology,
- 1-5: Jondishapour University of Medical Sciences,  
Ahwaz, Iran.

### Correspondence

Dr. Peyman Mikaili,  
Pharmacy Faculty,  
Ahwaz Jondishapour University of Medical Sciences,  
Golestan Ave. P.O. Box: 6287, Ahwaz, Iran.  
E-mail: payman\_michaeli@yahoo.com

- \* Received for Publication: May 22, 2008
- \* Revision Received: August 18, 2008
- \* Second Revision Received: September 2, 2008
- \* Final Revision Accepted: September 3, 2008

## INTRODUCTION

The pathological (including cellular and molecular) changes in the pulmonary fibrosis have been studied.<sup>1-6</sup> Connective tissue remodeling of the interstitium is an important feature of chronic lung diseases encompassing interstitial inflammatory changes and subsequent pulmonary fibrosis. The early inflammatory phase is usually associated with the release of several cytokines and chemokines by activated resident cells and infiltrating cells which, in turn, help further recruit inflammatory mononuclear cells. Cytokines and growth factors secreted by inflammatory cells and by interstitial cells (fibroblasts and myofibroblasts) play an important role in the fibrogenic phase of pulmonary fibrosis by inducing matrix synthe-

sis. In addition, matrix-degrading enzymes and their inhibitors also contribute to extracellular matrix remodeling in pulmonary fibrosis.<sup>1</sup>

The association between the development of pulmonary fibrosis in humans and the administration of various chemicals, especially various forms of cancer chemotherapy, has been made with increasing frequency in recent years. From a series of case reports it is clear that a great variety of chemical agents may induce rather similar clinical signs and symptoms and, on biopsy or at autopsy, the cellular changes seen in the lung, at least in late stages, are also similar. For example, pulmonary fibrosis has been reported as a side effect of nitrofurantoin, busulphan, melphalan, cyclophosphamide, amiodarone, mitomycin and bleomycin therapies, and also paraquat poisoning.<sup>2</sup>

Over the last decade, considerable evidence has emerged suggesting that important stimuli to collagen deposition in pulmonary fibrosis are polypeptide mediators known as cytokines.<sup>3</sup> Cytokines are released by resident lung cells and recruited inflammatory cells, and they are thought to stimulate fibroblast proliferation and increase synthesis of extracellular matrix proteins, including collagen. These effectors (inflammatory) cells, together with resident lung cells, such as macrophages, alveolar epithelial and endothelial cells, then release cytokines, which stimulate target cells, typically fibroblasts, to replicate and synthesize increased amounts of collagen. Breakdown of extracellular matrix protein may also be inhibited, thereby contributing to the fibrotic process.

Numerous cytokines have been implicated in the pathogenesis of lung fibrosis, including transforming growth factor- $\beta$  (TGF- $\beta$ ), tumor necrosis factor- $\alpha$  (TNF- $\alpha$ ), platelet-derived growth factor (PDGF), insulin-like growth factor-1 (IGF-1), endothelin-1 (ET-1) and the interleukins, IL-1 and IL-8. In vitro studies show that TGF- $\beta$ 1, secreted as a latent precursor, promotes fibroblast procollagen gene expression and protein synthesis. TNF- $\alpha$  can stimulate fibroblast replication and collagen

synthesis in vitro, and pulmonary TNF- $\alpha$  gene expression rises after administration of bleomycin in mice.<sup>4</sup> In patients with IPF or asbestosis, bronchoalveolar lavage fluid-derived macrophages release increased amounts of TNF- $\alpha$  compared with controls.<sup>5</sup>

Bleomycin is antineoplastic agent, related to antibiotic group. It has been used for the treatment of many types of cancers such as testicular and squamous cell carcinomas of the head and neck, cervix, skin, and rectum. The drug causes many adverse effects such as anaphylactoid reactions and a high incidence of fever, stomatitis and alopecia. Pulmonary fibrosis is an uncommon but sometimes fatal adverse effect seen particularly in older patients.<sup>6</sup>

Cetirizine is the pharmacological agent which has been selected to be evaluated in this study. Cetirizine is a long-acting H<sub>1</sub>-blocker antihistamine. It is the carboxylic acid metabolite of hydroxyzine. Cetirizine interacts with fibrogenic cytokine degranulation, thus it may have potentials to modulate the different stages of pulmonary fibrosis.<sup>7</sup>

*Aim of the study:* Trials investigating the protective effect of cetirizine against pulmonary fibrosis induced by drugs are not available. Thus the present study was designed to investigate the protective effect of cetirizine against pulmonary fibrosis induced by bleomycin in rats.

## METHODOLOGY

*Chemicals:* Bleomycin (Nippon Kayaku Co. Ltd, Japan), Ether and Ketamine (Rotexmedica Co., Germany), Sodium Pentobarbitone (Sagatal<sup>®</sup>), Cetirizin (Daru Pakhsh Co, Iran) and L-hydroxyproline (Sigma Chemical Co, England) were used. All other analytical grade reagents for histology and biochemical assays were bought either from Merck (Germany) or Sigma Chemical Co. (England).

*Animal housing:* Male Sprague-Dawley rats (n=30), weighing initially 180-250g, were bought from Jundishapur Research Institution (Ahvaz, Iran) for Animal Breeding and used throughout the study. All rats were housed in

large polypropylene cages (dimensions: 55cmx35cmx22cm, equivalent to 0.042m<sup>3</sup>) in single sex groups, with a maximum of six in each cage. Soft white-wood shavings were used as bedding. The temperature of holding rooms was regulated at 21-22°C and humidity was kept at 45-55%, with 14 hours light/10 hours dark cycle. Rats were fed on standard laboratory chow and tap water ad libitum.

Animals were free from detectable respiratory infection and were in good health. After delivery, the animals were allowed to acclimatize in holding rooms for at least five days before use.

*Induction of pulmonary fibrosis in the rat:* The rats, according to the method of Schraufnagel et al.,<sup>8</sup> were anaesthetized with ether and then they were placed on a slanted board (20 degree from vertical) hanging from their upper incisors. Bleomycin (7.5IU/kg) was delivered via the mouth into the trachea with a modified syringe needle in a volume of 1ml/kg body weight. So the animals received an intratracheal (IT) injection of bleomycin (7.5IU/kg) in saline solution. The rats were rotated immediately after receiving bleomycin to ensure that good drug distribution occurred in the lung. After recovery from anesthesia, the rats were returned to their cages and allowed food and water as normal. Control rats received an IT instillation of the same volume of sterile saline. Their food intake, respiration, and activity were observed every day.<sup>9</sup>

*Drugs Treatment:* The animals were divided into the following groups, (n=6 rats).

1. A group received only a single-dose bleomycin (7.5IU/kg, IT) as "positive control".
2. The rats in this group received vehicle (normal saline, IT) as "negative control".
3. "Treatment-C1 group" received daily cetirizine 5mg/kg/day intraperitoneally (IP), 7 days before and 4 weeks after administering a single-dose bleomycin (7.5IU/kg, IT).<sup>10</sup>
4. "Treatment-C2 group" received daily cetirizine 20mg/kg/day (IP), 7 days before and four weeks after administering a single-dose bleomycin (7.5 IU/kg, IT).<sup>11</sup>

5. Cetirizine 5mg/kg/day (IP) plus the vehicle (IT) for five weeks as "sham C".

All the administration routes were as intraperitoneal (IP) but the bleomycin, which was administered intratracheally (IT) as mentioned separately above and the vehicle in all solutions was distilled water. We also investigated the effects of the drugs and the vehicle (without bleomycin) as sham groups. All the ethical issues were considered throughout the experiment based on the Ahwaz Medical University Ethical Protocols (AMUEP) on animal experiments.

*Cytokines Assays:* The cytokines (e.g. IL-8, TNF- $\alpha$ , TGF- $\beta$ 1), were determined using conventional methods through ELISA kits, following the directions of the manufacturers. The samples were read, finally, by ELISA reader. The following kits were used: The Rat Tumor Necrosis Factor Alpha (Rt TNF- $\alpha$ ) ELISA; IL-8-EASIA Kit (BioSource, Belgium); The TGF- $\beta$ 1 Enzyme Immunoassay Kit.

*Determination of collagen and hydroxyproline content of lung tissue:* To estimate the amount of collagen in the lungs, hydroxyproline content was measured.<sup>12</sup> In brief, lungs were removed at weeks two and four post bleomycin instillation. After homogenization of lungs in 2ml of PBS (pH 7.4), 0.5ml of each sample was digested in 1ml of six NaHCl for 8 hour at 120°C. Then 50 $\mu$ l of citrate/acetate buffer (5% citric acid, 7.24% sodium acetate, 3.4% sodium hydroxide, and 1.2% glacial acetic acid, pH 6.0) and 1ml of chloramine-T solution (282 mg of chloramine-T, 2 ml of n-propanol, 2ml of H<sub>2</sub>O, and 16ml of citrate/acetate buffer) were added to 50 $\mu$ l of samples, and allowed to stand for 20 min at room temperature. After addition of 1ml of Ehrlich's solution (2.5 g of 4-dimethylamino benzaldehyde, 9.3ml of n-propanol, and 3.9ml of 70% perchloric acid) to each sample, the samples were placed in a water bath at 65°C for 15min. Samples were cooled for 10 min and their absorbance was measured at 550nm with a Unico UV-2100 spectrophotometer (United product, USA). A concentration series of 0-10 $\mu$ g/ml hydroxypro-

line were used to establish a standard curve.<sup>13</sup>

Preparation of isolated tissues

*Isolation of rat lung strip:* The animals were killed with a lethal overdose (120mg/kg, i.p.) of sodium pentobarbitone (Sagatal®). The animal was then placed on a dissection board in a supine position, the skin of the chest was excised with sharp scissors and the thorax was opened. The trachea, lung and heart were removed 'in toto' and placed in a beaker containing gassed (95% O<sub>2</sub> 5% CO<sub>2</sub>) Krebs-Henseleit solution.<sup>14</sup>

Using a scalpel blade on a wax block, strips of lung with approximate dimensions of 2.5mmx2mmx20mm were cut from the peripheral margin of left lobes, taking care to avoid the large bronchus. After securing the tissue holder to the apparatus, the hook which was attached to the superior end of the strip was further attached to a previously calibrated isometric Grass force displacement transducer (model FT03C or Dynamometer UF1), using twisted stainless steel wire. The tissue was preloaded with 1g resting tension and was allowed to equilibrate for at least one hour before using drugs. During the period of equilibration, the physiological solution was changed at least three times and again prior to the administration of test solutions.<sup>15</sup> The lung strips preparations from the rats of study groups were prepared after the test period. Contractile activity of lung-strip preparations from such animals was investigated compared with positive and negative control groups, lung strips. In order to study the effects of this pre-treatment on reactivity, possibly attributed to myofibroblasts or smooth muscles in the rat lung tissue, acetylcholine, depolarized potassium and sodium tungstate were employed as test agonists. Possible involvement of adrenoceptors and cholinceptors in contractions of lung strips evoked by acetylcholine or sodium tungstate was investigated.<sup>15</sup>

*Measurement of responses:* Responses to different drugs and agents used were recorded by the Grass polygraph, which had been calibrated to 0.2 or 0.5mv sensitivity, so that a one cm change in pen recorder amplitude repre-

sented 100 or 250mg change in tissue tension. The rate of paper advance was 2.5 or 5mm/min. All responses were then standardized in terms of tissue length and weight (mg tension/g weight/cm length). After addition of test agent solutions to the bathing fluid, a pH measurement was made (7.00 to 7.20) to ascertain the continuing effect of the CO<sub>2</sub>/bicarbonate buffer system.

*Histological examination:* Lung tissue was fixed by 10% neutral formalin solution for paraffin slides and sectioned at approximately 5-µm thickness. Tissue affixed to a glass slide deparaffinized, rehydrated and counterstained with hematoxylin and eosin (H&E) staining. The slides were examined by light microscopy and photographed. The effects of fibrogenic agent i.e. bleomycin and the healing effects of cetirizine were investigated histologically. Lung tissues were taken from groups of control or treated animals which were also used for pharmacological investigations. Lung tissue samples were fixed, processed, cut and stained for routine light microscopy and histopathology.

*Statistical Analysis:* Data has been presented as the mean±SEM. For determination of the significant differences, statistical analyses have been performed for parametric variables using student's t-test or one-way ANOVA and for non-parametric variables Mann-Whitney U-test was used by SPSS software. Values of p<0.05 has been regarded as statistically significant.

## RESULTS

Histological investigation of lung tissue: Fig-1 shows the histological analysis of lung tissues of the 4 groups of rats, including groups 1, 2, 3 and 4. The figure shows that rats of group 3 and 4 (c and d) had less pathological changes in lung tissues as compared to group 1(b). The severity of changes in lung tissues is less in group 4 (d) as compared with group 3 (c).

*Studies on contractility of lung-tissue strips:* Figure-2 shows the effects of sodium tungstate on contractions of lung strip preparations of

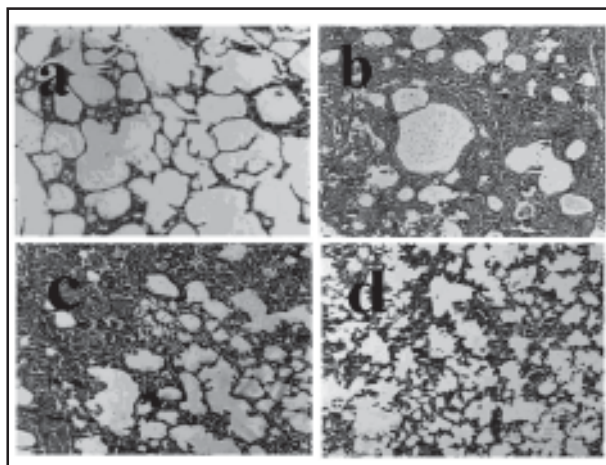


Fig-1: Hematoxylin-eosin histologic sections of lung tissue of different groups (magnifications  $\times 100$ ). (a) normal lung tissue of saline treated rat (negative control group); (b) there is an increase in cellularity (including myofibroblasts) of alveolar septal and intraalveolar fibrosis with collagenous bands accompanying great septal thickness and diffuse damage to lung architecture are observed (positive control group: bleomycin (7.5 IU/kg single dose)); (c) interstitial fibrosis with scattered septal thickness but slight infiltration of lymphocytes in comparison to the previous section (b) (group C1: cetirizine 5 mg/kg/day); (d) decreased fibrosis and septal thickness versus (b), although there are slightly thickened septa focally and fibrosis (group C2: cetirizine 20 mg/kg/day).

the four groups of rats, including groups one, two, three and four. The figure shows that rats of group three and four had less contractions of lung strip preparations as compared to group one. The amount of contractions of lung strip preparations is less in group four as compared with group three.

*Study of collagen and hydroxyproline content of lung tissue:* Fig-3 shows the effects of bleomycin on lung hydroxyproline content in the four groups of rats, including groups one, two, three and four. The figure shows that rats of group three (C1: cetirizine 5mg/kg/day) and group four (C2: cetirizine 20mg/kg/day) had less hydroxyproline content of lung as compared to group one. The amount of lung hydroxyproline content is less in group 4 as compared with group three.

*Studying the Cytokine Profile in the Studied groups:* Figure-4 shows the results from the

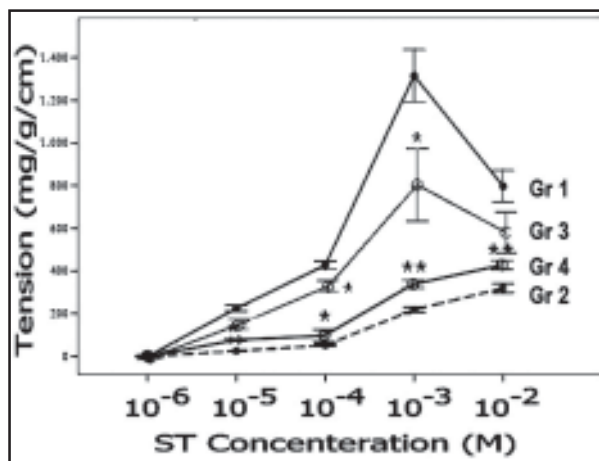


Fig-2: The effects of sodium tungstate on contractions of control positive (Gr 1) and control negative (Gr 2) rat lung strip preparations in comparison to group 3 (Gr 3) and group 4 (Gr 4). Each point represents the mean  $\pm$  SEM (n=6); value and data significantly different from control positive value are indicated \*  $p < 0.05$  and \*\*  $p < 0.01$  as shown by Mann-Whitney U-test.

ELISA Assays, processed by the statistical software of the data from three studied cytokines in the four groups of rats, including groups one, two, three and four. The figures shows that rats of group three and 4 had less amounts of fibrogenic cytokines as compared to group one. The amount of these cytokines is less in group four as compared with group three.

## DISCUSSION

Severe lung injury induces excessive cell death. Maintaining normal function and repair of parenchymal cells is the key to improving the prognosis of patients. Excessive cell death of parenchymal cells means irreversible tissue damage and may lead to pulmonary fibrosis. In this study the pathological changes in the lung tissue caused by bleomycine, were consistent with the findings of the other studies<sup>16</sup> as follows: the main features observed were intra-alveolar amorphous and cellular debris, hyaline membranes, interstitial edema and fibrosis, atypical proliferation of alveolar epithelial cells and collapse of alveoli.

Bleomycine affects on the contractility of lung tissue streps and the lung collagen contents. Additionally the cytokine levels are affected by

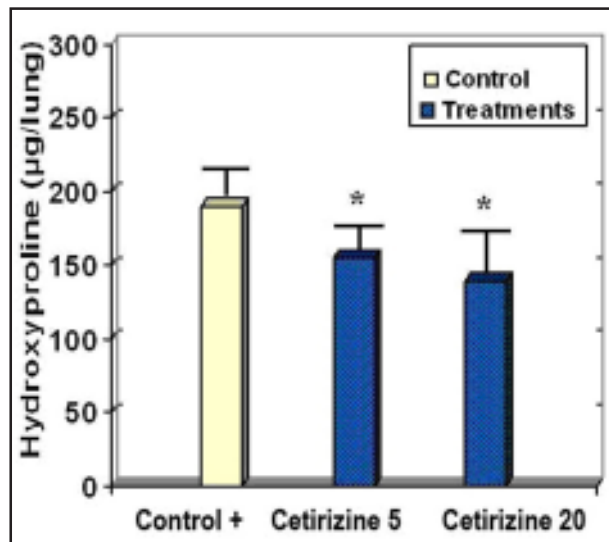


Fig-3: The effect of bleomycin on lung hydroxyproline content in the studied animals. Hydroxyproline content of lung tissue of rats was measured and normalized to micrograms per lung. Data are presented as mean ± SEM of n = 6; \*P <0.05 versus control. Positive control: bleomycin (7.5 IU/kg single dose); C1: cetirizine 5mg/kg/day; C2: cetirizine 20mg/kg/day.

bleomycin administration. The underlying mechanisms rest on physiology and pathophysiology of the intervening factors. The lung extracellular matrix (ECM) consists of collagen and elastic fibers interspersed with structural glycoproteins and proteoglycans (PGs). PGs influence lung tissue mechanical properties, and through their interactions with various macromolecules, contribute to a variety of biological functions. Changes in ECM synthesis and degradation play a part not only in physiological processes such as development, growth and aging but also in wound healing, inflammation and fibrosis.<sup>17</sup>

It is worth noting that, bleomycin-induced pulmonary fibrosis is an inflammatory interstitial lung disease characterized by excessive accumulation of fibroblasts and ECM molecules, including PGs, in the intraluminal and interstitial compartments of the lung. Evidence from human studies and animal models indicates that TGF-β1 plays a pivotal role in mediating pathophysiological changes in fibrotic diseases.<sup>18</sup> TGF-β1 stimulates fibroblasts to synthesize large amounts of ECM proteins.

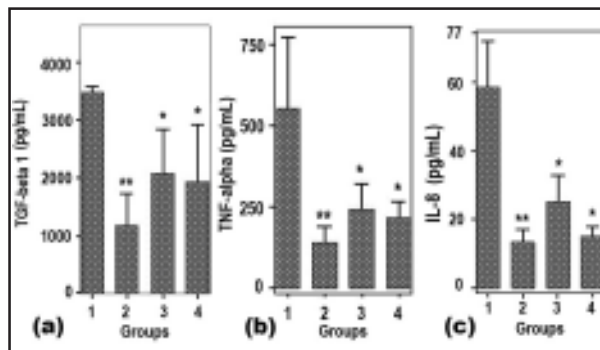


Fig-4: The results of ELISA Assay for detection of (a) TGF-beta1, (b) TNF-alpha and (c) IL-8 contents (pg/mL) of sera specimens in the groups at the end of the study. Results shown are averages of groups with standard deviations in comparison to the positive control group (which they had received only a single-dose of Bleomycin without the healing agents) (\*, P <0.05; \*\*, P <0.01).

TGF-β1 levels are upregulated in patients with pulmonary fibrosis and also in bleomycin-induced lung fibrosis in rats.

Fibroblasts participate in inflammatory responses and wound repair through their ability to release cytokines, secrete ECM proteins and through cell-cell interactions with other inflammatory cells such as macrophages. At sites of injury and wound repair, fibroblasts have been shown to migrate from different anatomic sites and transform into a less proliferative but more contractile and collagen synthetic phenotype. It has been reported that lung fibroblasts cultured from bleomycin-induced fibrotic rat lungs produced more collagen than normal lung fibroblasts in culture. Furthermore, Raghu *et al.*,<sup>19</sup> demonstrated that TGF-β1 stimulated collagen production and collagen mRNA levels in fibroblasts derived from normal and fibrotic human lungs.<sup>18</sup>

In this study we found that the pathological effects of bleomycin were dose-relatedly mitigated by cetirizine administration (in Figure 1, compare section (b) with (c) and (d) mainly by decreased fibrosis and septal thickness). Cetirizine mainly acts through the H1-receptors inhibition, but it acts also as a membrane stabilizer and may inhibit mediator release by degranulation of leucocytes.<sup>20</sup> This is suggested as “the main key function” of bleomycin-

induced pulmonary fibrosis protective effects and subsequently, prohibition of releasing the fibrogenic and inflammatory factors in the lung tissue and consequently, it causes to a reasonable degree of limiting the consequences of lung injury, especially pulmonary fibrosis.

In this study we found a direct relationship between the amount of (bleomycin-induced) fibroblast and myofibroblast proliferation and the increased lung tissue strips contractility (see Figure 1(b) and Figure 2 (Gr1)). These results were consistent with the previous studies.<sup>21</sup>

In this study we measured the hydroxyproline content as an indicator to estimate the amount of collagen in the lungs. According to the results of this study (Fig-3), the amount of collagen in the lungs of groups received ceterizine (both 5 and 20mg/kg/day, IP), showed statistically significant differences in comparison to the control group ( $p < 0.05$ ). It seems that membrane stabilization plays the main role in this protective effect of ceterizine.<sup>22</sup> These results confirm the findings of the previous studies.<sup>23</sup>

Numerous cytokines have been implicated in the pathogenesis of (bleomycin-induced) lung fibrosis, including transforming growth factor- $\beta$  (TGF- $\beta$ ), tumor necrosis factor- $\alpha$  (TNF- $\alpha$ ), platelet-derived growth factor (PDGF), insulin-like growth factor-1 (IGF-1), endothelin-1 (ET-1) and the interleukins, (IL)-1 and IL-8.<sup>24</sup> This has led to speculation that anticytokine therapeutic strategies, designed to inhibit cytokine production or function, will represent a new and effective treatment for pulmonary fibrosis. Cetirizine may have a main role in inhibition of the degranulation of the leukocytes and initiation and promotion of the inflammatory and fibrogenic processes in the lung tissue. According to the results of ELISA Assay in this study (Fig-4) for detection of TGF-beta1 (a), TNF-alpha (b) and IL-8 (c) contents (pg/mL) of sera specimens in the groups, the statistically significant differences between treatment groups which received ceterizine in comparison to the control group, shows the effectiveness of this agent in decreasing these important cytokines in the inflammatory

processes of pulmonary fibrosis. These results are according to the majority of previous studies,<sup>24</sup> but some other studies refused this activity of Cetirizine.<sup>25</sup> The exact reason of this conspiracy has not been yet exactly clear.

The study showed that cetirizine may have a protective effect against pulmonary fibrosis induced by bleomycine as evident by reduction of the severity of lung tissue changes, contractility of lung tissue strips, reduction of the amounts of collagens and cytokines in the lungs induced by bleomycine.

### ACKNOWLEDGMENTS

The authors wish to thank Professor Dr. Ardeshir Arzi, Dr. Narjes Zaeimzadeh, Mrs. Nazari and Mr. Mehdi Sameie for their assistance with this work. This research was supported by a grant from the research council of Ahvaz Jondishapour University of Medical Sciences.

### REFERENCES

1. Razzaque MS, Taguchi T. Pulmonary fibrosis: Cellular and molecular events. *Pathology International*, 2003;53(3):133-145.
2. Ian YR. Adamson. Drug-Induced Pulmonary Fibrosis. *Environmental Health Perspectives* 1984;55:25-36.
3. Kalayarasan S, Sriram N, Sudhandiran G. Diallyl sulfide attenuates bleomycin-induced pulmonary fibrosis: Critical role of iNOS, NF-kappaB, TNF-alpha and IL-1beta. *Life Sci* 2008;82(23-24):1142-53.
4. Li X, Molina-Molina M, Abdul-Hafez A, Uhal V, Xaubet A, Uhal BD. Angiotensin converting enzyme-2 is protective but downregulated in human and experimental lung fibrosis. *Am J Physiol Lung Cell Mol Physiol* 2008;295(1):178-85.
5. Nakashima T, Yokoyama A, Onari Y, Shoda H, Haruta Y, Hattori N, et al. Suppressor of cytokine signaling 1 inhibits pulmonary inflammation and fibrosis. *J Allergy Clin Immunol* 2008;121(5):1269-76.
6. Andrade RS, Kesler KA, Wilson JL, Brooks JA, Reichwage BD. Short and long term outcomes after large pulmonary resection for germ cell tumors after bleomycin-combination chemotherapy. *Ann Thorac Surg* 2004;78(4):1224-8.
7. Bartra J, Valero AL, Del Cuvillo A, Dávila I, Jáuregui I. Interactions of the H<sub>1</sub> antihistamines. *J Investig Allergol Clin Immunol* 2006;16: Supplement 1:29-36.

8. Schraufnagel DE, Mehta D, Harsbarger R, Trevianus K, Wang NS. Capillary remodelling in bleomycin induced pulmonary fibrosis. *Am J Pathol* 1986;125:97-106.
9. Hemmati AA, Nazari Z, Motlagh ME, Goldasteh S. The role of sodium cromolyn in treatment of paraquat-induced pulmonary fibrosis in rat. *Pharmacological Research* 2002;46(3):229-34.
10. Larsson AK, Fumagalli F, DiGennaro A, Andersson M, Lundberg J, Edenius C, et al. A new class of nitric oxide-releasing derivatives of cetirizine; pharmacological profile in vascular and airway smooth muscle preparations. *Br J Pharmacol* 2007;151(1):35-44.
11. Orzechowski RF, Currie DS, Valancius CA. Comparative anticholinergic activities of 10 histamine H1 receptor antagonists in two functional models. *Eur J Pharmacol* 2005;506(3):257-64.
12. Zhang Y, Lee TC, Guillemin B. Enhanced IL-1 $\beta$  and tumor necrosis factor- $\alpha$  release and messenger RNA expression in macrophages from idiopathic pulmonary fibrosis or after asbestosis exposure. *J Immunol* 1993;150:4188-96.
13. Pinart M, Serrano-Mollar A, Negri EM, Cabrera R, Rocco PR, Romero PV. Inflammatory related changes in lung tissue mechanics after bleomycin-induced lung injury. *Respir Physiol Neurobiol* 2008;160(2):196-203. Epub 2007.
14. Hemmati AA, Hicks R. Increased myofibroblast contractile sensitivity in paraquat pretreated rat lung tissue. *Life Sci* 1999;65:2325-32.
15. Hübner RH, Gitter W, Eddine El, Mokhtari N, Mathiak M, Both M, et al. Standardized quantification of pulmonary fibrosis in histological samples. *Biotechniques* 2008;44(4):507-17.
16. Hübner RH, Gitter W, El Mokhtari NE, Mathiak M. Standardized quantification of pulmonary fibrosis in histological samples. *Biotechniques* 2008;44(4):507-17.
17. Crouch EC. Pathobiology of pulmonary fibrosis. *Am J Physiol* 1990;259:159-84.
18. Sime PJ, O'Reilly KMA. Fibrosis of the lung and other tissues: New concepts in pathogenesis and treatment. *Clin Immunol* 2001;99:308-19.
19. Raghu G, Masta S, Meyers D, Narayanan AS. Collagen synthesis by normal and fibrotic human lung fibroblasts and the effect of transforming growth factor. *Am Rev Respir Dis* 1989;140:95-100.
20. De Vos C, Mitchev K, Pinelli ME, Derde MP, Boev R. Non-interventional study comparing treatment satisfaction in patients treated with antihistamines. *Clin Drug Investig* 2008;28(4):221-30.
21. Wallach-Dayana SB, Golan-Gerstl R, Breuer R. Evasion of myofibroblasts from immune surveillance: A mechanism for tissue fibrosis. *Proc Natl Acad Sci USA*. 2007;18;104(51):20460-5.
22. Grönke L, Schlenker J, Holz O, Magnussen H, Jörres RA. Effect of cetirizine dihydrochloride on the airway response to hypertonic saline aerosol in patients with chronic obstructive pulmonary disease (COPD). *Respiratory Medicine* 2005;99(10):1241-8.
23. Noah TL, Paradiso AM, Madden MC, McKinnon KP, Devlin RB. The response of a human bronchial epithelial cell line to histamine: Intracellular calcium changes and extracellular release of inflammatory mediators. *Am J Respir Cell Mol Biol* 1991;5(5):484-92.
24. Kang HR, Cho SJ, Lee CG, Homer RJ, Elias JA. Transforming growth factor (TGF)- $\beta$ 1 stimulates pulmonary fibrosis and inflammation via a Bax-dependent, bid-activated pathway that involves matrix metalloproteinase-12. *J Biol Chem* 2007;282(10):7723-32.
25. Cheng KC, Hsu JY, Fu LS, Chang WC, Chu JJ. Influence of cetirizine and loratadine on granulocyte-macrophage colony-stimulating factor and interleukin-8 release in A549 human airway epithelial cells stimulated with interleukin-1 $\beta$ . *J Microbiol Immunol Infect* 2006;39(3):206-11.