

## HEPATIC MESENCHYMAL HAMARTOMA

Heshmatalah Soufi Majidpour<sup>1</sup>, Vahid Yousefinejad<sup>2</sup>, Mohammad Gharib Salehi<sup>3</sup>

### ABSTRACT

Hepatic mesenchymal hamartoma (HMH) is a rare liver tumor in childhood. Yet its biology and pathogenesis are poorly understood. We report a case of a six month-old male infant, who presented with abdominal distension for two month and fever and vomiting for two weeks. The management and etiology of this case is discussed.

**KEY WORDS:** Mesenchymal hamartoma, Liver Tumor.

Pak J Med Sci October - December 2008 (Part-II) Vol. 24 No. 6 876-878

### How to cite this article:

Majidpour HS, Yousefinejad V, Salehi MG. Hepatic mesenchymal hamartoma. Pak J Med Sci 2008;24(6):876-78.

### INTRODUCTION

Hepatic mesenchymal Hamartoma (HMH) is a rare benign childhood tumor.<sup>1</sup> Approximately 55% of cases present in the first year of life.<sup>2</sup> About 75% of HMH occur in the right lobe of the liver; the rest are found in the left lobe or involve both lobes.<sup>3-5</sup> mesenchymal hamartoma of the liver may be found incidentally on physical examination or imaging, but typically

it presents with abdominal distention and/or an upper abdominal mass. Abdominal pain, anorexia, vomiting and poor weight gain have also reported.<sup>6</sup> We reported here a case of hepatic mesenchymal hamartoma in six month-old infant

### CASE REPORT

A six month-old male infant was referred to our hospital because of abdominal distension with progression for one to two months. He presented with fever and vomiting for two weeks. There was no history of cough, cyanosis and jaundice. On physical examination he looked ill. His liver was palpable 6-7cm below the right costal margin and there was no splenomegaly. The haemogram and liver function tests showed normal data. The serum AFP level was 290ng/ml (normal, <20ng/ml) and the 24h urine Vanillylmandelic Acid (VMA) amount was normal. Chest X-Ray showed decreased translucency in the right upper and lower zone [Fig-1]. Ultrasound revealed a 155×75mm cystic mass in the right lobe of the liver [Fig-2]. A computed tomography (CT) scan showed a cystic mass in the right hepatic lobe that pushed right kidney [Fig-3].

At laparotomy a cystic tumor (17×13×7cm) originating from the right lobe was resected.

1. Heshmatalah Soufi Majidpour, Assistant Professor, Department of Urology, Kurdistan University of Medical Sciences, Tohid Hospital, Sanandaj, Kurdistan, Iran.
2. Vahid Yousefinejad, Research Vice-chancellorship, Kurdistan University of Medical Sciences, Pasdaran Street, Sanandaj, Iran.
3. Mohammad gharib Salehi, Assistant Professor, Department of Radiology, Kurdistan University of Medical Sciences, Beahsat Hospital, Sanandaj, Kurdistan - Iran.

#### Correspondence

Vahid Yousefinejad  
E-mail: Vayo56@yahoo.com

- \* Received for Publication: January 10, 2008
- \* Revision Received: February 14, 2008
- \* Revision Accepted: September 3, 2008

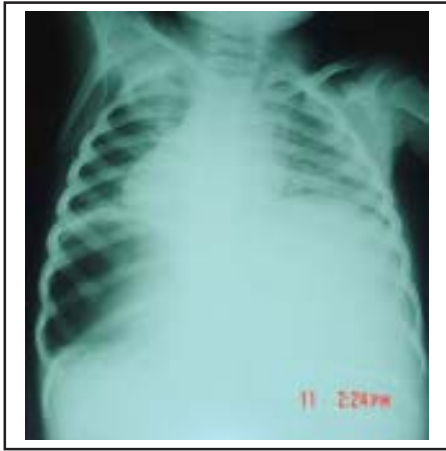

Fig-1: Chest X-Ray showed decreased trans lucency in the right upper and lower zone of abdomen.

The pathology sections showed hepatic nodules and sheaths with intervening loose edematous myxoid connective tissue with dilated lymphatics vessels, fluid-filled spaces and scattered disorganized elongated branching bile ducts & reported mesenchymal hamartoma [Fig-4].

### DISCUSSION

Mesenchymal hamartoma of the liver may be found incidentally on physical examination or imaging, but typically it presents with abdominal distention and/or an upper abdominal mass. Abdominal pain, anorexia, vomiting and poor weight gain have also reported, but pain is seldom a dominant feature.<sup>6</sup> Microscopically, HMH shows loose or myxomatous connective tissue containing cystic spaces, bile ducts, hepatocytes, fibrous tissue

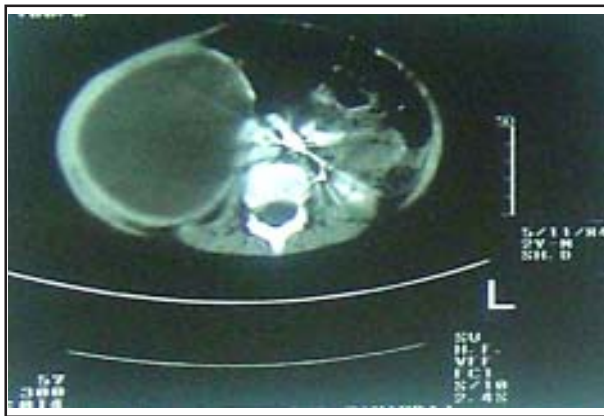


Fig-3: Abdominal CT scan with contrast of patient showed a cystic mass in the right hepatic lobe that induce right kidney shift.

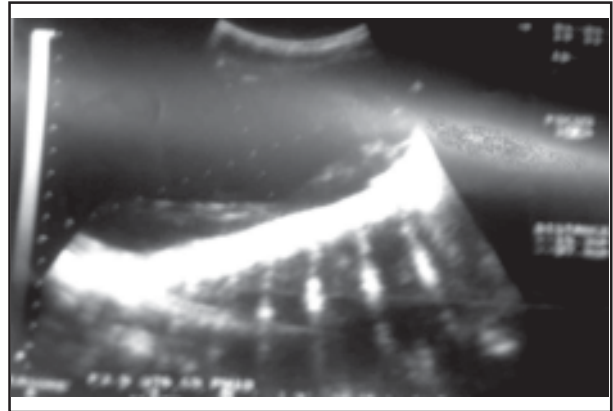


Fig-2: An abdominal ultrasound scan of patient showed single cyst, 155x75 mm in size, including hypoechoic debris in the right lobe of liver.

and vessels. Extramedullary haematopoiesis may be seen adjacent to the bile ducts, small vessels or at the periphery of the lesion. Vessel or lymphatic dilatation with fluid accumulation along the degenerated mesenchyme result in the cystic space.<sup>7</sup>

Plain radiography may show calcification within the hepatic tumor but this is uncommon.<sup>6</sup> On CT, the more common cystic form of mesenchymal hamartoma appears as a low-attenuation mass; enhancing septa may be seen.<sup>8</sup> On MRI examination, the appearance of mesenchymal hamartomas depends on the composition of the lesion. Cystic mesenchymal hamartomas may show low or high signal intensity lesions on T2 weighted images.<sup>8</sup>

Laboratory studies of HMH often reveal normal liver function tests. Serum AFP elevation up to 6000ng/ml has been reported in patients with HMH. Other tumor markers, such as  $\beta$ -HCG and VMA are negative.<sup>2,9</sup>

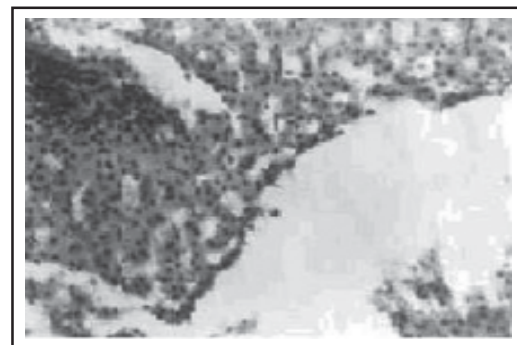

Fig-4: Microphotograph of liver biopsy showing multiple microcysts ( $\times 40$ ).

Benign liver tumors in children may be divided into two major groups: those of epithelial derivation, including simple cysts, focal nodular hyperplasias and adenomas and those of mesenchymal derivation including hamartomas and hemangiomas. Benign mesenchymal tumors of liver are common than their epithelial counterparts.<sup>10</sup>

Differential diagnoses of HMH include hepatoblastoma, hepatocellular carcinoma (HCC), infantile haemangioendothelioma and undifferentiated embryonal sarcoma (UES). The serum AFP level is often elevated in patients with HCC or hepatoblastoma. Most HCC and hepatoblastoma are solid on ultrasound and CT study.<sup>2</sup> Infantile haemangioendothelioma is the most common vascular tumor of the liver in infancy. On ultrasonography examination, it is predominantly hypo echoic and usually has well-defined margins. Computed tomography scans show a hypo attenuating lesion, and sometimes calcification can be seen. On enhanced scans, the peripheral enhancement of this tumor shows with filling in of the central low-attenuation areas on the delayed scans. Unlike HMH, patients with infantile haemangioendothelioma usually manifest heart failure and/or bleeding tendency. The UES is a rare liver tumor and usually appears as a solitary mass in the right lobe. Patients with UES present between six and ten years of age. The common symptoms are right upper-quadrant pain and abdominal mass.<sup>6,11</sup>

Hepatic mesenchymal hamartomas are best treated by complete excision. Progressive abdominal distension may be fetal in untreated infants.<sup>6</sup> Excision may be by conventional hepatic resection or by nonanatomical excision with a small margin of normal liver pedunculated lesions are amenable to laparoscopic resection.<sup>12</sup>

Despite the relative hypovascularity of most lesions the adjacent hepatic parenchyma may be very vascular. With modern techniques, complications during or after tumor resection are uncommon. Fatal hemorrhage is exceptionally rare.<sup>2</sup>

Biliary complications are unusual and treatable.<sup>13</sup> There is a small risk of late adhesive small bowel obstruction.<sup>6</sup> After complete resection, occasional clinical and ultrasonography review is advisable for at least five years, but an excellent prognosis can be anticipated.<sup>14</sup>

In the present case surgical excision of tumor was done and no tumor recurrence was noted during the follow-up period.

## REFERENCES

1. Kamata S, Nose K, Sawai T, Hasegawa T, Kuroda S, Sasaki T, et al. Fetal Mesenchymal Hamartoma of the Liver: Report of a case. *J Pediatric Sur* 2003;38(4):639-41.
2. Yen JB, Kong MS, Lin JN. Hepatic mesenchymal hamartoma. *J Paediatr Child Health* 2003;39:632-4.
3. Locham KK, Bal MS, Kapila AK, Singh M. Cystic Mesenchymal Hamartoma of Liver. *Indian Pediatrics* 1999;36:931-5.
4. Al-Rikabi AC, Buckai A, AL-Sumayers. Fine needle aspiration cytology of mesenchymal hamartoma of the liver, A case report. *Acta Cytol* 2000;44:449-53.
5. Jimenez-Heffeman JA, Vicandi B, Lopez-Ferrer. Fine-needle aspiration cytology of mesenchymal hamartoma of the liver. *Diagn Cytopathol* 2000;22:250-3.
6. Stringer MD, Alizai NK. Mesenchymal hamartoma of the liver: A systematic review. *J Pediatric Sur* 2004;40:1681-90.
7. Stocker JT, Ishak KG. Mesenchymal hamartoma of the liver: report of 30 cases and review of the literature. *Pediatr Pathol* 1983;1:245-67.
8. Benya EC. Hepatobiliary System. In: John R. Haaga, Charles F. Lanzieri, Robert C. Gilkeson. *CT and MR Imaging of the Whole Body*. Fourth ed, 2003; 2: Mosby, Philadelphia. 2016.
9. Lee PI, Chang MH, Chen DS, Lee CY. Serum  $\alpha$ -fetoprotein levels in normal infants: A reappraisal of regression analysis and sex difference. *J Pediatr Gastroenterol Nutr* 1989;8:19-25.
10. De Maioribus CA, Lally KP, Kenneth S, Hart H, Hossein M. Mesenchymal hamartomas of the liver. A 35 years review. *Arch Surg* 1990;125:598-600.
11. Kim DY, Kim KH, Jung SE. Undifferentiated (embryonal) Sarcoma of the liver: combination treatment by surgery and chemotherapy. *J Pediatr Surg* 2002;37:1419-23.
12. Tsao K, Hirose S, Sydorak R. Fetal therapy for giant hepatic cysts. *J Pediatr Surg* 2002;37:E 31.
13. Kitano Y, Ruchelli E, Weiner S. Hepatic mesenchymal hamartoma associated with mesenchymal stem villous hyperplasia of the placenta. *Fetal Diagn Ther* 2000;15:134-8.
14. Ramanujam TM, Ramesh JC, Goh DW. Malignant transformation of mesenchymal hamartoma of the liver: Case report and review of the literature. *J Pediatr Surg* 1999;34:1684-6.