

HEART INVOLVEMENT IN KALAAZAR

Armin S¹, Gharib A², Khalaj E³

SUMMARY

Leishmaniasis is a vector-borne disease. About 30 species of sandflies are proven vectors of leishmania, the usual reservoir host includes human and domestic/wild animals. In addition, acquisition of visceral leishmaniasis as a result of blood transfusion has been documented. Visceral leishmaniasis presents in various forms. We report a three year old girl with visceral leishmaniasis and pericardial effusion. Meglumine antimoniate was prescribed for her and all her signs and symptoms plus her pericardial effusion were resolved.

KEY WORDS: Kala azar, Pericardial effusion, Childhood.

Pak J Med Sci October - December 2008 (Part-II) Vol. 24 No. 6 879-882

How to cite this article:

Armin SH, Gharib A, Khalaj E. A type of heart involvement in Kala Azar. Pak J Med Sci 2008;24(6): 879-82.

INTRODUCTION

Leishmaniasis is a vector-borne disease resulting from infection with one of 20 species of the protozoan parasite. Leishmania is transmitted by 30 Phlebotomies sand fly species.¹ Occasional nonvector transmissions have also been reported through blood transfusions, sexual intercourse, organ transplants, excrements of dogs, and sporadically outside endemic areas.² Clinically, leishmaniasis manifests itself in four main forms: cutaneous, mucocutaneous, diffuse cutaneous and visceral.³ The Visceral leishmaniasis is characterized by fever, weight loss, lassitude, pallor, hepatosplenomegaly, anemia, leucopenia and hypergamma-globulinaemia.⁴ The disease is endemic in 82 countries, with an estimated worldwide annual incidence of 600,000 cases.⁵ An increased incidence of the disease has been reported during the past decade in many Mediterranean countries where the disease is endemic like Iran.⁶

Young children and possibly malnourished populations seem to have a greater likelihood

-
1. Shahnaz Armin, MD, Assistant Professor, Sub Specialist in Pediatric, Infectious Diseases, Pediatric Infectious Research Center, Faculty of Medicine,
 2. Gharib A, MD, Assistant Professor, Pathologist, Mofid Children Hospital, Faculty of Medicine,
 3. Khalaj E, MD General Practitioner
- 1-3: Shaheed Beheshti University (Medical Sciences), Tehran, Iran.

Correspondence

Shahnaz Armin MD,
Assistant Professor,
Pediatric Infectious Research Center,
Mofid Children's Hospital,
Shariati St.,
Tehran,
Republic of Iran.
E-mail: pedircorg@yahoo.com

- * Received for Publication: December 19, 2007
- * Revision Received: September 12, 2008
- * Revision Accepted: September 15, 2008

of developing visceral disease.⁷ We report a 3-year old girl diagnosed with visceral leishmaniasis that also developed cardiac involvement, which is a very rare manifestation of the disease. Knowledge of the frequency of the disease and its variable clinical presentations, some of which are decidedly rare, will help us to better manage patients with visceral leishmaniasis.⁸

CASE REPORT

A three year old girl was taken to physician with fever from two weeks before admission. She suffered from prolonged fever without any other symptoms. So she was admitted to the hospital as a case of fever of unknown origin. Her general health and development had been normal on the physical examination. She was pale, her lung and heart sounds were normal, massive hepatosplenomegaly without lymphadenopathy was observed. (Fig-1)

Her complete blood count showed the following results: Hemoglobin: 7.5 gr/dl, total leukocyte count: 2600/mm³ with 20% polymorphonuclears, 75% mononuclear, 2% monocytes and 3% eosinophil. MCV: 76.2 fl, PLT =66000. ESR was 31/h. Reticulocyte count was 0.7%. Biochemical tests were normal.

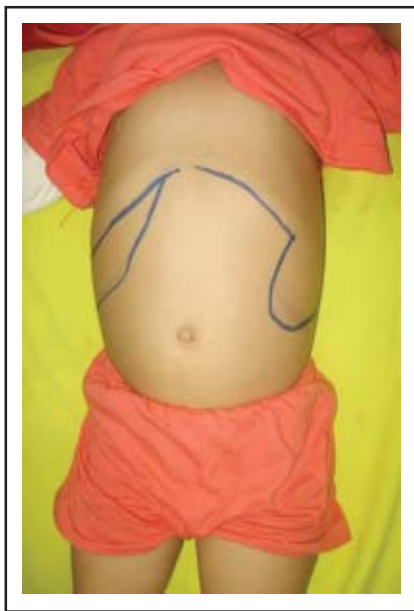

Figure-1: Massive hepatosplenomegaly.

Tuberculin test was negative. The results of three consecutive blood cultures were negative. Urine analysis and culture were normal. The chest X-ray showed a normal-sized heart and decreased bone density, echocardiography revealed mild pericardial effusion in the right side (20cc) and mild TR. Fig-2 shows her first echocardiograph.

Abdominal sonography revealed hepatosplenomegaly, peripheral blood smear was negative for malaria or borellia. Serologic studies showed no evidence of brucellosis, salmonellosis or EBV infection, serology test for leishmania (IFA) was reported positive with a titer of 1/320. Bone marrow biopsy was done, which revealed a cellular bone marrow containing plenty of Leishmania parasites.

The patient was treated with meglumine antimoniate 60 mg / kg /day for three weeks. Fever was relieved and her general condition improved. In the end of therapy blood cell counts revealed: hemoglobin: 12.2 g/dL; hematocrit: 34.2%; erythrocyte count: 4.34×10⁹ cells/mm³; WBC count, 10200 cells/mm³ and Platelet count of 225000/ ml. The child showed considerable improvement. The second echocardiogram at the end of therapy showed trivial pericardial effusion and TR, one month after the end of treatment, the third echocardiogram was completely normal.

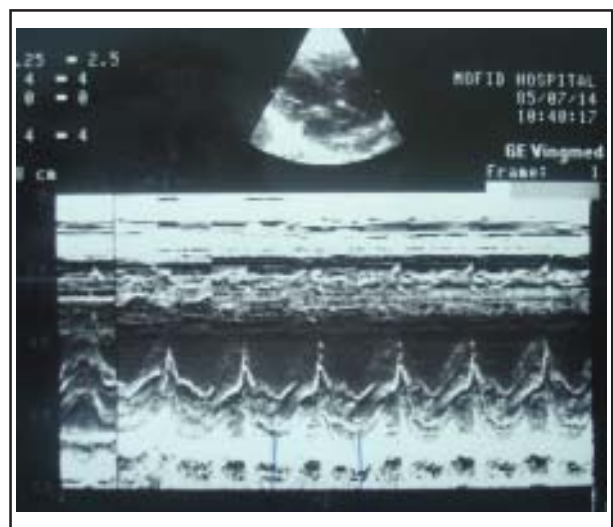


Figure-2: First echocardiograph.

DISCUSSION

Visceral leishmaniasis, also called kala azar, is usually caused by *L. donovani*, *L. infantum*, or *L. chagasi* and rarely by *L. tropica* or *L. mexicana*. These are parasites that are generally transmitted by sand flies and then disseminate in the body of their host by infecting macrophages in multiple organs, but particularly in the spleen, liver, bone marrow, and lymph nodes. It may begin either suddenly with high fevers, vomiting, diarrhea, and coughing, or insidiously with irregular daily increasing fever, poor appetite, weight loss, lassitude and pallor. Fever, hepatosplenomegaly and pancytopenia with a history of traveling or living in an endemic area are highly suggestive for visceral Leishmaniasis.

Diagnosis of leishmaniasis is complicated because of the various forms of the disease, variety of parasite species involved, geographic variations, and other clinically similar syndromes, for example visceral leishmaniasis may be confused with such diseases as malaria, typhoid fever, typhus, and schistosomiasis.⁹

Diagnosis should be confirmed either by microscopic identification of the parasite in liver, spleen, or bone marrow biopsy or by detection of DNA of *Leishmania* by PCR in blood or biopsy material.¹⁰ Untreated, the disease is fatal in 90% of cases after 1 to 3 years.¹⁰ The course of the disease is identical in children and adult. VL mostly involves children under two years of age in Iran. We couldn't determine the strain of leishmania in our patient but a study in southern Iran showed the dominant strain of leishmania to be *leishmania infantum*.¹¹ On admission to hospital our patient showed intermittent fever, hepatosplenomegaly and pancytopenia. In our investigation for cause of fever, echocardiography showed pericardial effusion. She also lived in an endemic region. A laboratory diagnosis of visceral leishmaniasis was made and confirmed by bone marrow aspiration. Although in leishmaniasis, parasites can involve all organs but cardiac involvement isn't common. On literature

review, two cases with leishmaniasis and heart involvement were reported, one of which was a case from Iran with leishmaniasis and heart failure, and the other was from India with heart failure and pericardial effusion. Heart failure can be the result of severe anemia seen in chronic diseases such as leishmaniasis but pericardial effusion without heart failure is very rare. In a study from India¹² researcher evaluated cardiac function before, during and at the end of therapy in fourteen new cases of visceral leishmaniasis. Pericardial effusion was detected on Day 0 in one patient, on Day seven in two patients and on Day 14 in another patient. It is hard to speculate as to the cause of pericardial effusion. It is possible that this may represent an exacerbation of inflammatory reaction during treatment, especially in patients with heavy parasitaemia. Although authors didn't find any difference in Pre-treatment serum albumin and hemoglobin levels in patients with and without pericardial effusion but they concluded that pericardial effusion is a rare finding in VL, which may occur in patients with heavy parasitaemia. However, unfortunately we didn't determine the level of parasitemia in our cases. It remains unclear whether it was because of cardiac involvement secondary to VL, anemia and/or hypoalbuminaemia related to VL. All patients who reported with pericardial effusion clinically improved and the pericardial effusion disappeared on continued antileishmanial therapy such as our patient. In our patient pericardial effusion responded to meglumine antimonate.

CONCLUSION

Protozoa can involve different organs, and the disease presents with many different features, even heart involvement. Although pericardial effusion was clinically not significant, it is not inconceivable that the pericardial involvement may contribute to unexpected cardiac deaths in untreated VL patient. This rare picture of VL may remain undetected due to lack of awareness. Because

of that, thorough work up should be considered in every patient with suspected visceral Leishmaniasis.

REFERENCES

1. www.warwick.ac.uk/fac/sci/bio/research/ee/ee/research/humans/leishmaniasis
2. www.pediatrics.aappublications.org/cgi/content/full/104/5/e65
3. Lane RP. Sandflies. In: Lane RP, Crosskey RW, eds. *Medical Insects and Arachnids*. London: Chapman and Hall; 1993;78-119.
4. Karimi A. Short course anti-leishmania therapy in children with visceral leishmaniasis. *Iran J Med Sci* 1998;23:6-9.
5. Magill AJ. Epidemiology of the leishmaniasis. *Dermatoepidemiology* 1995;13:505-23.
6. Desjeux P. Information on the epidemiology and control of the Leishmaniasis by country and territory. Report 27. Geneva: WHO, 1991.
7. Pearson RD, Sousa ADQ. Leishmania species: Visceral, cutaneous and mucosal leishmaniasis. In: Mandell GL, Bennett JE, Dolin R, eds. *Principles and Practice of Infectious Diseases*. 4th ed. New York: Churchill Livingstone 1995;2428-2.
8. Kadivar MR, Kajbaf TZ, Karimi A, Alborzi A. Childhood visceral leishmaniasis complicated by bacterial infections. *Eastern Mediterranean Health J* 2000;6(5-6):879-83.
9. www.medscape.com/viewarticle/417525_3
10. Bryceson ADM, Hay RJ. Parasitic worms and protozoa. *Textbook of Dermatology*. Oxford: Blackwell, 1991;1252-3.
11. Alborzi A, Rasouli M, Shamsizadeh A. Leishmania tropica isolated patient with visceral leishmaniasis in southern Iran. *Am J Trop Med Hyg* 2006;74(2):306-7.
12. Shrivastava R, Sinha PR, Singh VP, Sundar S. Echocardiographic evaluation of cardiac status in Indian visceral leishmaniasis patients. *Trans R Soc Trop Med Hyg* 2007;101(5):429-32.