

Chest wall radionecrosis and hyperbaric oxygen therapy

Yasemin Benderli Cihan¹, Senol Yildiz², Mehmet Sina Yilmaz³

ABSTRACT

Chest wall radionecrosis is one of the rare complications of radiotherapy. In this case report, the results that were obtained with hyperbaric oxygen treatment (HBOT) in a patient with chest wall radiation necrosis refractory to the conventional treatment method are reported. It was seen that HBOT could be used for chest wall radionecrosis as a safe and effective treatment method.

KEY WORDS: Radionecrosis, Hyperbaric oxygen therapy, Breast cancer.

Pak J Med Sci October - December 2012 Vol. 28 No. 5 959-961

How to cite this article:

Cihan YB, Yildiz S, Yilmaz MS. Chest wall radionecrosis and hyperbaric oxygen therapy. Pak J Med Sci 2012;28(5):959-961

INTRODUCTION

A multidisciplinary approach is essential in breast cancer management. Generally, it is used together with locoregional and systemic treatment.¹

It is possible to evaluate the changes that occur over time in injuries caused by the effect of radiation in three periods, namely acute, subacute, and chronic periods. The chronic complications have a slow course. The main pathological changes that emerge during this period include reduction in vascular and capillary density, cellular depression, fibrosis and atrophy. Permanent tissue hypoxia may also be seen due to all of these disorders.^{2,3}

Hyperbaric oxygen therapy is based on having the patient breath 100% oxygen with intervals at 2-3 absolute atmospheric pressure while the patient's whole body is under pressure in a closed pressure chamber.^{4,5} We report a case with chest wall radionecrosis who was treated using HBOT with a successful result.

CASE REPORT

A 31-year-old female patient admitted to the surgery outpatient clinic in 2000 was diagnosed with Stage 2B infiltrative ductal carcinoma after left modified mastectomy. The patient was treated with four courses of CA (Siklofosamid-Adriablastin) and two courses of Taxotere chemotherapy followed by application of radiotherapy at a dose of 50 Gy/25 fr with a Co⁶⁰ teletherapy device. The patient was followed by routine follow-ups after the treatment. No problems were observed during the routine follow-ups and a draining, odorous, infected, and ulcerated lesion of 1x0.5 cm in size was found at the incision line in January 2010.

Laboratory investigations revealed normal hemogram and biochemistry values except for the presence of anemia. The laboratory results were as follows: CRP: 12.2 mg/L (0-6), sedimentation: 43 mm/hour (0-20), CA 15-3: 13.5 U/mL (0-38.6) and CA 125: 13.93 U/ml. Growth of *Pseudomonas aeruginosa* and methicillin-sensitive *Staphylococcus*

1. Yasemin Benderli Cihan,
Kayseri Education and Research Hospital,
Department of Radiation Oncology,
Kayseri, Turkey.
2. Senol Yildiz,
Gulhane Military Medical Academy Haydarpasa Teaching Hospital,
Underwater and Hyperbaric Medicine, Ankara, Turkey.
3. Mehmet Sina Yilmaz,
Kayseri Education and Research Hospital,
Department of Radiology, Kayseri, Turkey.

Correspondence:

Yasemin Benderli Cihan,
Department of Radiation Oncology,
Kayseri Education and Research Hospital,
38010, Kocasinan, Kayseri,
Turkey.
E-mail: cihany@erciyes.edu.tr

* Received for Publication: May 27, 2012

* Accepted: July 15, 2012

aureus was observed in the culture material taken from the wound area. Antibiotic treatment and daily dressings were initiated based on the culture results. The patient received no benefit from this 6-month-long treatment and progression was observed in the wound area. In the reconstructive surgery consultation, surgery was not considered appropriate due to possible complications.

The patient was referred to the hyperbaric oxygen therapy center for hyperbaric oxygen therapy in July 2010 and the pre-treatment CT and MRI revealed a hyperintense fluid collection in the left breast area with a size of 47x17 mm at the widest area and osteomyelitis in the left anterior 3rd, 4th and 5th rib and fibrous tissue appearance in the skin and subcutaneous tissue was reported in the adjacent area (Fig. 1a and 1b). Upon the determination of the absence of any contraindications to HBOT, HBOT administration was initiated at a pressure of 2 ATA for 90 minutes daily for five days a week. Dressing changes were done once daily and samples for culture were taken once a week. The MRI taken three months after the end of the HBOT treatment showed that the infection in the ribs was totally cured (Fig.2). After the completion of the hyperbaric oxygen therapy, the patient started to be followed up in the outpatient clinic and the wound has completely closed after six months.

DISCUSSION

The incidence and the severity of the side effects associated with radiotherapy depend on dose, dose rate, the volume irradiated, the quality of radiation administered, age, gender, accompanying diseases, hormonotherapy, anemia and collagen vascular

diseases. Depending on these factors, injuries of various degrees ranging from minimal changes to total necrosis develop and repair occurs rapidly and totally or is not possible based on the degree of these injuries.^{1,3,4,6}

In tissues exposed to radiation, the problems that arise are not limited to cell death and also include formation of cells defective in terms of functions. The ability for restorative proliferation and the vascularization of the cells are impaired and late-stage reactions manifesting as fibrosis, atrophy, and tissue hypoxia occur. The clinical manifestation includes edema, ulceration, pigmentation, loss of tissue elasticity and local erythema. This tissue has a propensity to form a chronic wound and to rapidly progress to necrosis, spontaneously as a result of cell and matrix loss and due to the effects such as surgery and trauma.^{2,3,6,7} The reason why the patient admitted to our clinic was a chronic infected wound and she had no history of trauma.

The late complications may cause a hard to treat condition which sometimes follows a more destructive course than the malignancy itself due to the serious structural and functional impairments they cause.⁶ Pierce et al reported brachial plexopathy (2%), rib fracture (2%), secondary sarcoma (0.2%) and soft tissue necrosis requiring surgical intervention (0.2%) in their series of 1624 cases who received breast-conserving surgery and radiotherapy, where the surviving patients were followed for a median period of seven years. These serious complications were late complications and developed 10-100 months after the end of treatment.³ Spanos et al followed-up patients with late-stage breast cancer for post-radiotherapy side

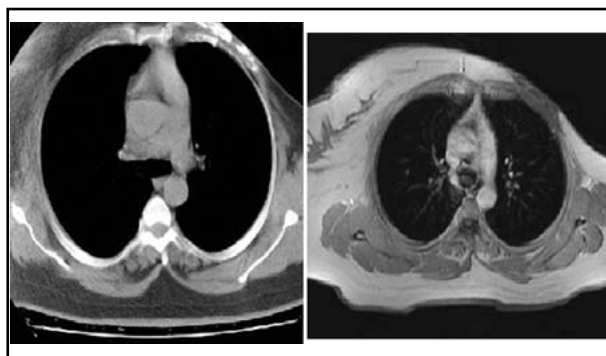


Fig. 1a and 1b: CT and MRI revealed a hyperintense fluid collection in the left breast area with a size of 47x17 mm at the widest area and osteomyelitis in the left anterior 3rd, 4th and 5th rib and fibrous tissue appearance in the skin and subcutaneous tissue was reported in the adjacent area.

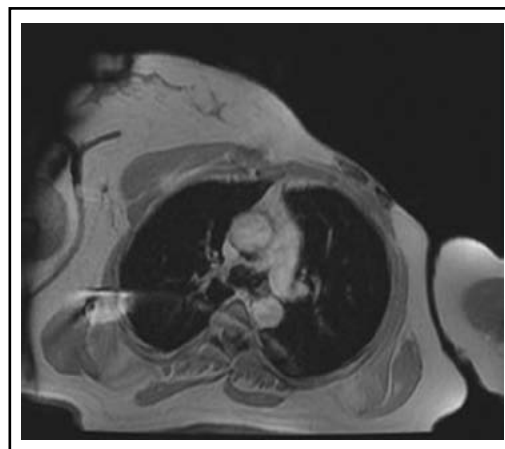


Fig.2: The MRI taken 3 months after the end of the HBOT treatment showed that the infection in the ribs was totally cured.

effects. They reported serious subcutaneous fibrosis in 20% and development of soft tissue, skin necrosis and ulceration in a low percentage of patients.²

There is currently no defined optimal treatment for chronic complications. The aim of the radionecrosis treatment is to provide revascularization in the injured tissue and to improve fibroblastic activity. This is also the aim of the HBOT treatment.^{6,7}

There are publications reporting the efficacy of HBOT in the prevention and treatment of side effects caused by radiotherapy. During HBOT, arterial partial oxygen pressure may increase up to 2000 mmHg in proportion to the pressure at which the treatment is administered. Hyperoxia exerts favorable effects in many stages of wound healing. HBOT improves the bactericidal capacity of leukocytes by increasing the amount of oxygen in tissues. Moreover, it causes an increase in the proliferation of fibroblasts, collagen synthesis, and maturation and angiogenesis.^{4,7} We think that all of these effects may explain the improvement observed in this case.

In a prospective study, Carl et al administered HBOT to patients with early-stage breast cancer with the complaints of post-lumpectomy, and post-radiotherapy pain, edema, erythema, fibrosis, and telangiectasia. They reported a marked improvement in 32 of 44 patients with a treatment performed with 25 sessions on average. Compared to the non-HBOT group, the HBOT group demonstrated significant results in the improvement of pain, erythema, and edema, while the results for fibrosis and telangiectasia were not significant.⁶ The decision for using HBOT was based on failure of response to the conventional treatment methods and the fact

that surgical intervention was not recommended due to possible complications. During the HBOT treatment of 40 sessions, no treatments other than daily dressings were administered. In our case, the efficacy of the treatment was monitored by MRI.

This case also shows that HBOT can be considered as a safe and effective treatment method as in other studies reporting the benefit of hyperbaric oxygenation in necrosis cases caused by radiation where no favorable results could be obtained with conventional treatment methods.

REFERENCES

1. Winer EP, Morrow M, Osborne CK. Malignant tumors of the breast. Devita VT, Hellman S, Rosenberg SA. Cancer Principles and Practice of Oncology. 6th ed. Philadelphia: Lippincott Williams and Wilkins pub.; 2001: 1651-1717.
2. Spanos WJ, Montague ED, Fletcher GH. Late complications of radiation only for advanced breast cancer. *Int J Radiat Oncol Biol Phys.* 1980;6(11):1473-1476.
3. Pierce SM, Rrecht A, Lignos TI, Abner A, Silver B, Harris JR, et al. Long term radiation complications following conservative surgery and radiation therapy in patients with early breast cancer. *Int J Radiat Oncol Biol Phys.* 1992;23(5):1111-1115.
4. Hart GB, Mainous EG. The treatment of radiation necrosis with hyperbaric oxygen. *Cancer.* 1976;37(6):2580.
5. Marx RE. Radiation injury to tissue. In: Kindwall EP, Whelan HT, editors. *Hyperbaric medicine practice.* 2nd ed. Flagstaff, AZ: Best Publishing; 2002: 665-724.
6. Carl UM, Feldmeier JJ, Schmitt G, Hartmann KA. Hyperbaric oxygen therapy for late sequelae in women receiving radiation after breast-conserving surgery. *Int J Radiat Oncol Biol Phys.* 2001;49(4):1029-1031.
7. Salner AL, Botnick LE, Herzog AG, Goldstein MA, Harris JR, Hellman S. Reversible brachial plexopathy following primary radiation therapy for breast cancer. *Cancer Treat Rep.* 1981;65(9-10):797-802.