

## Follow-up of small bowel autotransplantation combined with pancreatoduodenectomy and hemicolectomy

Yinglong Xu<sup>1</sup>, Shu Gong<sup>2</sup>, Hong Wu<sup>3</sup>

### ABSTRACT

Till now reports on intestinal autotransplantation for mesenteric pathologic lesions of small intestine were rare. Here we present a follow-up of a patient with pancreatoduodenectomy and small bowel autotransplantation for enormous mesenteric cavernous hemangioma of small intestine for 6 and a half years. He is now 27 years old, maintains a normal diet and lives a normal life with no sign of tumor recurrence. So we conclude that pancreatoduodenectomy, hemicolectomy and small bowel autotransplantation is a safe and effective operation.

**KEY WORDS:** Intestinal autotransplantation, Cavernous hemangioma, Short-bowel syndrome, Follow-up.

Pak J Med Sci October - December 2012 Vol. 28 No. 5 962-964

### How to cite this article:

Xu Y, Gong S, Wu H. Follow-up of small bowel autotransplantation combined with pancreatoduodenectomy and hemicolectomy. Pak J Med Sci 2012;28(5):962-964

### INTRODUCTION

Hemangioma is a congenital hamartomatous lesion that originates from embryonic sequestrations of mesodermal tissue. Generally, patients with hemangioma may have an excellent prognosis after complete resection of the lesion. Therefore, surgical resection is the main treatment for mesenteric hemangioma. But this resection is not effective for those patients in whom the angiocavernoma has infiltrated the mesenteric artery or pancreas, and these patients often give up operation. At present, several cases of small bowel autotransplantation combined with pancreatoduodenectomy for mesenteric pathologic lesions of small intestine have been reported.<sup>1-8</sup>

However, small bowel autotransplantation combined with pancreatoduodenectomy is one of the most sophisticated operations and requires perfect technique. Although this operation has been successfully performed, survival results and life quality of long-term patients have been reported rarely.<sup>9</sup>

In this report, we have followed up the patient for six and a half years after pancreatoduodenectomy, hemicolectomy and small bowel autotransplantation and we hope that the case could provide more direct evidence for the procedure to apply in clinical practice.

### CASE REPORT

A 21-year-old young man was admitted to our hospital because of an abdominal lump. He had an exploratory laparotomy in 2001 in another hospital but unfortunately that operation only made a biopsy instead of surgical resection because of the difficulty of removing the tumor adjacent closely to the mesentery. The patient later gave up further therapy although the biopsy showed mesenteric hemangioma which was a benign pathologic lesion. From then on the patient had suffered 5 years of abdominal distension, flank pain and increasing abdominal girth aggravated day by day. In order

1. Yinglong Xu,
2. Shu Gong,
3. Hong Wu,
- 1-3: Hepato-Bilio-Pancreatology Department,  
West China Hospital of Sichuan University,  
Chengdu 610041, China.

Correspondence:

Hong Wu,  
Hepato-Bilio-Pancreatology Department,  
West China Hospital of Sichuan University,  
Chengdu 610041, China.  
E-mail: wuhong\_scu@163.com

\* Received for Publication: July 2, 2012

\* Accepted for Publication: September 10, 2012

to relieve disorder, he was admitted to our hospital in 2006. He was 165 cm in height but only weighted 40 kg then. Enhanced CT scan showed there was a large abdominal lobulated lump, 22.5 cm × 28.0 cm × 38.0 cm in size<sup>5</sup>, which showed non-uniform enhancement in contrast scanning. The tumor occupied the majority of the abdominal cavity room so other adjacent organs had been pulled and displaced to the periphery.

Meanwhile ultrasonography showed that there was a lump around the small bowel mesenteric vessels, but fortunately none was around the renal arteries, abdominal aorta and the inferior vena cava. During operation, the mass was found to arise from the root of the small intestinal mesentery, and the superior mesenteric artery and vein, the lower segment of the choledochus, the uncinate process of the pancreas, the jejunum, and ileum were involved. The tumor had been completely removed by pancreatoduodenectomy, hemicolectomy and small bowel autotransplantation.<sup>5</sup> Histopathological

examination confirmed a diagnosis of cavernous hemangioma of the small intestine mesentery. The patient tolerated the procedure well and had an uneventful postoperative course.

Now, this patient has been followed up for six and a half years. He didn't feel abdominal distension and flank pain after operation. Now he works in a gas station. He is 169cm tall and 61kg heavy with five hundred gram food in every meal and stool twice or three times a day. The levels of tests on urine, hepatic and renal function and serum IgA, IgG, IgM, C3 and C4 were within normal limits. Dyspeptic food was sometimes found in his feces. Abdominal CT didn't show recurrence of tumor and normal mesentery artery (Fig.1A, B). Digestive tract barium meal showed that barium could enter into small intestine, and reached the rectum by about 3.5 hours (Fig.2).

He got a marked symptom of anemia and his the blood routine test showed a chronic iron-deficiency anemia, with the HGB 32g/L, mean corpuscular hemoglobin (MCH) 14.9pg, mean corpuscular hemoglobin concentration (MCHC) 227g/L, ferritin 2.38ng/ml. His intrinsic factor, folic acid was within normal level. There was no sign of blood loss in the digestive tract and no obvious change in his diet and his bowel evacuation habit. So we presumed the anemia had been caused by malabsorption of the intestinal graft. The anemia was relieved by supplement of iron later. Therefore, through the result of following the patient, we think that pancreatoduodenectomy, hemicolectomy and small bowel autotransplantation is a safe and effective operation.

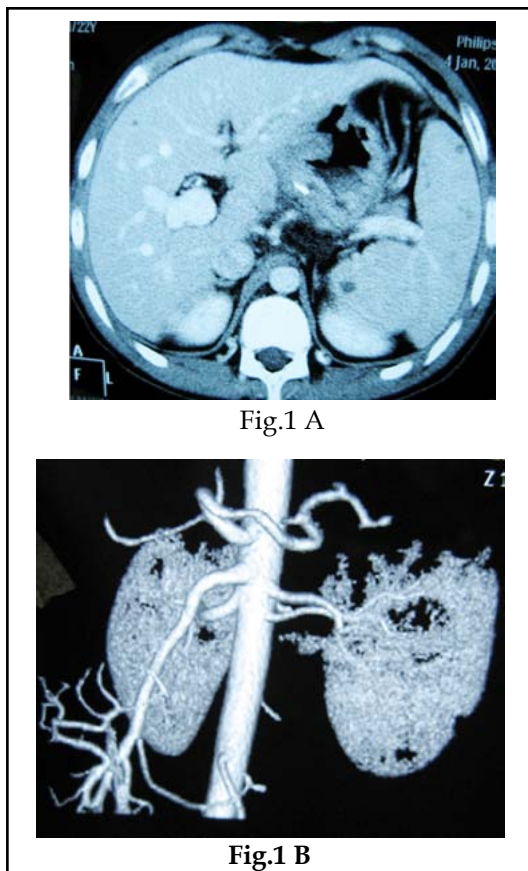


Fig.1: (A) The computed tomography (CT) scan suggested no recurrence of tumor.

(B) The CT three dimensional angiography suggested the superior mesenteric artery was normal in morphology and with no stenosis of the end-to-end anastomosis.

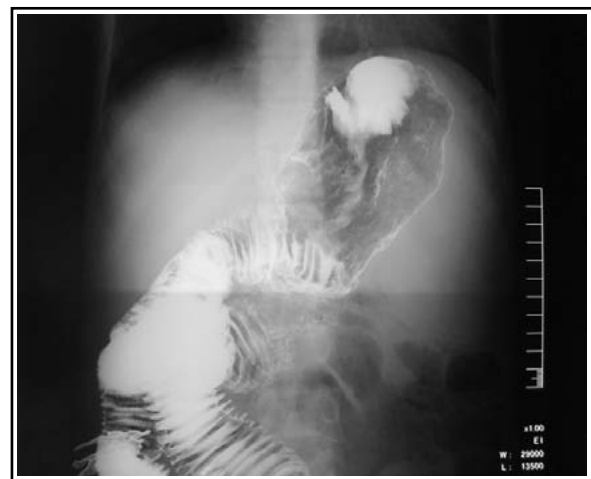


Fig.2: (A) The digestive tract barium meal suggested that the barium entered into the small intestine unobstructed.

(B) The digestive tract barium meal suggested that the barium reached the rectum by about 3.5 hours.

## DISCUSSION

Tumors which invaded the root of the mesentery are regarded as unresectable in general especially in malignant cases.<sup>6</sup> Reports of the partial abdominal evisceration and autotransplantation to resect a tumor infiltrated the mesentery were still rare. Till now there were less than twenty cases been reported have undergone intestinal autotransplantation with or/without other abdominal organ autotransplantation.<sup>1-9</sup> Most of the cases are malignant diseases such as pancreatic carcinoma or benign disease such as mesenteric fibroma and desmoids tumor, but no case of cavernous hemangioma. Tzakis AG et al reported the follow-up of 10 cases who underwent intestinal autotransplantation for various diseases; the result showed that all of the benign cases were alive and well with functional autografts.<sup>9</sup> The longest case which had been followed up for 138 months was a 4 years old child who suffered mesenteric fibroma. Long-term complications after intestinal autotransplantation such as short bowel syndrome (SBS) occurred occasionally in the cases with benign disease. Besides, long-term survival and normal life were achieved and when comparing to the complications of parenteral nutrition and intestine allotransplantation.

Due to the accumulation experience of intestine allotransplantation, advances in transplantation techniques and progress of reliable parenteral nutrition, the intestinal autotransplantation promotes quickly. But there still are some problems such as cold preservation, ischemic damage, reperfusion injury, denervation of the intestinal graft, lymphatic outflow disorder, malabsorption to be resolved which may raise adverse effects on the long-term survival cases. In present case, we have found enhanced peristalsis, malabsorption, anemia but no reverse flow of the bile or requirement of partial parenteral nutrition.

The diagnosis of cavernous hemangioma in the abdominal organs is difficult and not timely because these patients always developed an asymptomatic progress. For the case presented, it was a rare case of cavernous hemangioma which invaded the mesentery. The ever growing huge volume of the tumor and laparotomy 5 years before last operation have made the radical operation more difficult and sophisticated. According to the literature<sup>9</sup> and the case presented here, can be concluded like that

benign tumors such as cavernous hemangioma, desmoid tumors, pseudopapillary epithelial carcinoma of the pancreas, and leiomyosarcoma seem to be good indications for intestinal autotransplantation for the purpose of such tumor resection. Long-term survival and relatively high quality of life were achieved after resection of the tumor. In short, more research and experience are needed to conquer the postoperative complications in future.

## REFERENCES

1. Lai DT, Chu KM, Thompson JF, Gallagher JP, Wauqh R, Storey DW, et al. Islet cell carcinoma treated by induction regional chemotherapy and radical total pancreatectomy with liver revascularization and small bowel autotransplantation. *Surgery*. 1996;119(1):112-114.
2. Tzakis AG, De Faria W, Angelis M, Verzaro R, Pinna A. Partial abdominal exenteration, ex vivo resection of a large mesenteric fibroma, and successful orthotopic intestinal autotransplantation. *Surgery*. 2000;128(3):486-489.
3. Tzakis AG, Tryphonopoulos P, De Faria W, Kato T, Nishida S, Levi DM, et al. Partial abdominal evisceration, ex vivo resection, and intestinal autotransplantation for the treatment of pathologic lesions of the root of the mesentery. *J Am Coll Surg*. 2003;197(5):770-776.
4. Quintini C, Di Benedetto F, Diago T, Lauro A, Cautero N, De Ruvo N, et al. Intestinal autotransplantation for adenocarcinoma of pancreas involving the mesenteric root: our experience and literature review. *Pancreas*. 2007;34(2):266-268.
5. Zeng Y, Wu H, Yang JY. Small bowel autotransplantation combined with pancreatoduodenectomy for enormous cavernous hemangioma of the small intestine mesentery. *Chin Med J (Engl)*. 2008;121(20):2110-2112.
6. Amano H, Miura F, Toyota N, Wada K, Katoh K, Hayano K, et al. In situ surgical procedures for locally advanced pancreatic cancer partial abdominal evisceration and intestinal autotransplantation. *J Hepatobiliary Pancreat Surg*. 2009;16(6):771-776.
7. Tzvetanov IG, Bhati CS, Jeon H, Glover AE, Oberholzer J, Benedetti E. Segmental intestinal autotransplantation after extensive enterectomy for removal of large intra-abdominal desmoid tumors of the mesentery root: Initial experience. *Surgery*. 2012;151(4):621-624.
8. Kitchens WH, Elias N, Blaszkowsky LS, Cosimi AB, Hertl M. Partial abdominal evisceration and intestinal autotransplantation to resect a mesenteric carcinoid tumor. *World J Surg Oncol*. 2011;9:11.
9. Tzakis AG, Pararas NB, Tekin A, Gonzalez-Pinto I, Levi D, Nishida S, et al. Intestinal and multivisceral autotransplantation for tumors of the root of the mesentery Long-term follow-up. *Surgery*. 2012;152(1):82-89.

### Authors' contributions:

Yinglong Xu and Shu Gong collected research data and drafted the manuscript. Hong Wu reviewed the literature and revised the manuscript. All authors read and approved the final manuscript.