

Nephrotoxicity of hydroalcoholic extract of *Teucrium polium* in Wistar rats

Azar Baradaran¹, Yahya Madihi², Alireza Merrikhi³,
Mahmoud Rafieian-Kopaei⁴, Mehdi Nematbakhsh⁵, Azam Asgari⁶,
Zahra Khosravi⁷, Farshad Haghighian⁸, Hamid Nasri⁹

ABSTRACT

Background and Objectives: *Teucrium polium* L. (Calpoureh) is a wild-growing flowering plant, found abundantly in South-West of Asia, Europe and North Africa. Traditionally, *Teucrium polium* L. (Calpoureh) has been used for different pathological conditions. In traditional Iranian medicine, the tea of *Teucrium polium* L. is used for treating many diseases such as type 2 diabetes. It is believed that this plant has beneficial therapeutic properties. However, further studies are necessary to identify its toxic effects. The aim of this study was to evaluate the nephrotoxicity of hydroalcoholic extract of *T. polium* in male Wistar rats.

Methodology: In this experimental study, 100 rats were divided into 10 groups of ten each. Five groups were injected intraperitoneally (ip), 50, 100, 150, 200 mg/kg extracts or normal saline for 28 days and sacrificed to study the probable kidney damage. Five other groups were injected the same drug regimen, but they were sacrificed 28 days after cessation of drug injections to investigate the effect of possible complication or regeneration during recovery.

Results: Following 28 days of *T. Polium* consumption (phase I), kidney damages were not increased in comparison with control group ($P > 0.05$). However, following 28 days of drug cessation, kidney damages including degeneration, destruction and vacuolization, appeared in comparison with control group and with increasing the doses of TP.

Conclusion: Due to nephrotoxicity, *T. polium* should not be used or should be consumed with great caution.

KEY WORDS: Tubular cells, *Teucrium polium*, Nephrotoxicity, Tubular cell degeneration.

doi: [http://dx.doi.org/10.12669/pjms.291\(Suppl\).3527](http://dx.doi.org/10.12669/pjms.291(Suppl).3527)

How to cite this:

Baradaran A, Madihi Y, Merrikhi A, Rafieian-Kopaei M, Nematbakhsh M, Asgari A, et al. Nephrotoxicity of hydroalcoholic extract of *Teucrium polium* in Wistar rats. *Pak J Med Sci* 2013;29(1)Suppl:329-333. doi: [http://dx.doi.org/10.12669/pjms.291\(Suppl\).3527](http://dx.doi.org/10.12669/pjms.291(Suppl).3527)

This is an Open Access article distributed under the terms of the Creative Commons Attribution License (<http://creativecommons.org/licenses/by/3.0>), which permits unrestricted use, distribution, and reproduction in any medium, provided the original work is properly cited.

1. Azar Baradaran, Department of Pathology,
 2. Yahya Madihi, Child Growth and Development Research Center, Isfahan University of Medical Sciences, Isfahan, Iran
 3. Alireza Merrikhi, Child Growth and Development Research Center, Isfahan University of Medical Sciences, Isfahan, Iran
 4. Mahmoud Rafieian-Kopaei,
 5. Mehdi Nematbakhsh, Department of Physiology, Water & Electrolytes Research Center, Isfahan University of Medical Sciences, Isfahan, Iran
 6. Azam Asgari,
 7. Zahra Khosravi,
 8. Farshad Haghighian,
 9. Hamid Nasri,
 - 2,3: Child Growth and Development Research Center,
 - 1-3,5: Isfahan University of Medical Sciences, Isfahan, Iran.
 - 4,6-9: Medical Plants Research Center, Shahrekord University of Medical Sciences, Shahrekord, Iran.
- Correspondence:
Hamid Nasri,
Professor, Water & Electrolytes Research Center, Isfahan University of Medical Sciences, Isfahan, Iran and Medical Plants Research Center, Faculty of Medicine, Shahrekord University of Medical Sciences, Shahrekord, Iran.
E-mail: hamidnasri@yahoo.com

INTRODUCTION

Lamiaceae family comprises of about 210 genera and 3,500 species.¹ One of the most popular species of this family, native to the Mediterranean region and the Middle East, is *Teucrium polium* L (TP), commonly known as golden germander. This medicinal plant and other species belonging to the genus *Teucrium* have been used for over 2000 years in traditional and herbal medicine for its anti-diabetic, anti-inflammatory and antispasmodic properties.¹⁻⁷ TP contains chemical compositions such as salvigenin, cirsiliol,¹ α - and β -pinen, sabinene, myrcene, germacrene D, limonene, β -caryophyllene and spathulenol.²⁻⁴ Previous studies have demonstrated some of the pharmacological effects of TP such as

antibacterial, anti-inflammatory, antioxidant,⁷⁻¹⁸ anti-ulcerogenic,¹⁵⁻²⁰ anti-diabetic²⁰⁻²⁴ and anti-spasmodic¹⁷⁻²³ effects.

In addition, lowering blood lipids,²⁰⁻²⁰ induction of vascular relaxation),²⁵ positive inotropic and chronotropic²⁶ and decreasing of blood pressure²⁷ has been reported by this plant. The use of herbal remedies containing *T. polium* extracts without any scientific guidance has resulted in several cases of hepatotoxicity.²⁷⁻²⁹ Other *Teucrium* species including other plants widely used in folk medicine have been demonstrated to be responsible for liver injuries.^{28,29} In France, all preparations containing germander as an herbal medicine were prohibited.^{28,29}

On the other hand, the number of the reports concerned with the toxicity potential of *T. polium* are not adequate. Therefore, the present study was conducted to investigate the nephrotoxicity of the hydroalcoholic extract of TP on Wistar rats.

METHODOLOGY

Plant Material: Aerial parts of TP were collected from mountains around Chaharmahal and Bakhtiyari Province, Iran, in July 2010 and the plant was authenticated at the Medical Plants Research Center of Shahrekord University of Medical Sciences. A voucher specimen was deposited there (voucher 298).

Extraction Preparation: The *T. polium* leaves were dried in a ventilated room at 45 °C for 48 h and powdered. 300 grams of aerial parts of TP were macerated with ethanol (70%) at 30°C for 24 hours and was shaken intermittently. The extraction procedure was repeated two times and then was concentrated in a rotary evaporator under low pressure to give one third of the primary volume. The solution was then dried by oven at 40°C. The dried extract was reconstructed with distilled water to prepare suitable concentrations.

Animal Studies: In this experimental study, 100 adult male Wistar rats (150-200 g) were used. The animals were divided randomly into 10 groups of 10, including, 2 control and 8 case groups. Animals of five groups received normal saline, 50, 100, 150

or 200 mg/kg extract, respectively, for 28 days, and then were killed (Phase 1). The animals of other five groups received the same drug regimen; however, they were kept for 28 days, without drug injection, and then were killed (Phase 2). Animals in control groups received the same volume of distilled water (1ml/kg). After collecting the blood samples, they were left for half an hour, to be coagulated. Then, blood serum was separated by centrifugation for 10 minutes at 4000 rpm.

Histopathology Study: After the rats were anesthetized with ether, systematic method of dissection was done. Sterile incision was made in the specific location. The kidneys were removed and examined. Then, a longitudinal incision was made on kidneys. One half of the kidney was placed in 10% buffered formalin solution for 24 hours for staining with Hematoxylin and Eosin (H&E)(31-33). The staining routine method with H&E was done and histopathology slides were prepared. Using optical microscopy, the microscopic evaluations were done based on the following criteria. The lesion were classified scoring 1 to 4, based on tubular dilatation, degeneration of cells, the percentage of vacuolization tubular cells, hyaline cast and debris tubule cells (Table-I)³⁰⁻³⁵

Statistical Analysis: Data were expressed as mean ± SEM. To compare the percentage of hyaline cast, debris, vacuolization, flattening of tubular cells, degeneration of tubular cells and dilatation of tubular lumen of kidney tissue between and within the groups and between each phase of study, Mann-Whitney or Kruskal-Wallis were applied. Values of $P < 0.05$ were considered statistically significant.

RESULTS

The percentage of vacuolization, flattening, degeneration and destruction in tubular cells and in kidney tissue is demonstrated in Fig. 1-4. (The concentration of 200 mg /kg, group 5; 150, group 4; 100 group 3, 50 group 2 and control, group 1). The

Table-I: Qualitative criteria evaluation (score 1 - 4) on microscopic based study.

0	Absent	
1	Mild	involving ≤25% of each microscopic field
2	Moderate	>26% and ≤ 50%
3	Severe	>51% and ≤ 75%
4	Very Severe	>76%

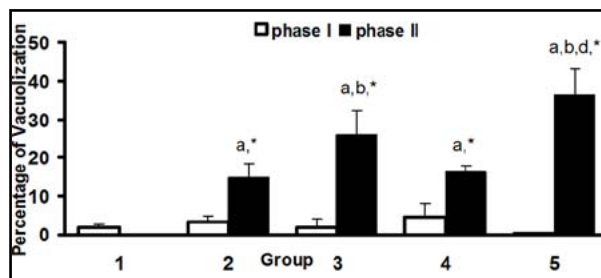


Fig. 1: Vacuolization percentage (%) in kidney tissue from five groups of experiment. Significant difference was detected in (a) group1, (b) group 2, (d) group 4 and (*) phase I ($P < 0.05$).

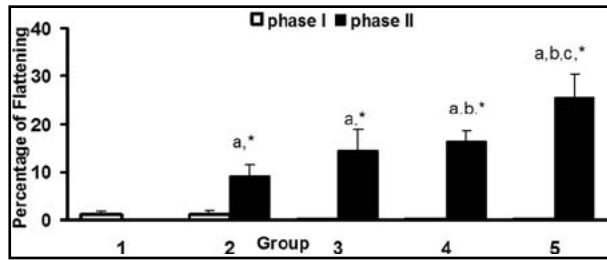


Fig. 2: Flattening percentage (%) of tubular cells in kidney tissue from five groups of the experiment. Significant difference was detected from (a) group1, (b) group 2, (c) group 3 and (*) phase I (P<0.05).

results indicate significant differences between two phases and between each group as demonstrated in the Fig.1. Comparison between groups showed that, vacuolization was increased with increasing TP dose.

In phase one of the study, no significant difference of mentioned morphologic lesions of the tubules was found between cases and control groups. However, after a period of 28 days (Phase 2), morphologic lesions regarding the effect of drug on tubular cells were appeared. The percentage of debris and dilatation in kidney tissue in group one of phase one was 0.4 ± 0.266 and 0.5 ± 0.5 respectively. In phase II, the percentage of dilatation of tubular lumen in groups 3 and 5 were 1.5 ± 1.067 and 3.5 ± 2.134 respectively. These parameters (debris of tubular cells and dilatation of tubular lumen) as well as hyaline cast in both phases of each group were zero.

There were not significant differences of flattening between the groups in phase one and control group; however after a period of 28 days of drug cessation, flattening was appeared. Also comparison between groups showed that flattening was increased by increasing the drug dosage. Degeneration occurred even with low doses of TP. Also according to the ascending curve, degeneration was also increased with increasing the dose of TP. Comparing the groups in phase one and two, the injuries were increased after 28days in phase 2 (P <0.05). Fig.3.

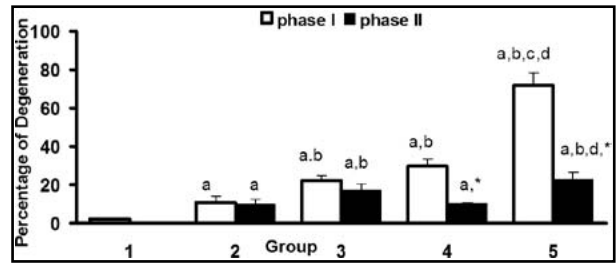


Fig. 3: Degeneration percentage (%) of tubular cells in kidney tissue from five groups of experiment. Significant difference was detected from (a) group1, (b) group 2, (c) group 3, (d) group 4 and (*) phase I (P<0.05).

showed that degeneration occurred even with low doses of TP. Figure also showed that degeneration of tubular cells was dose dependent.

There were no significant differences of tubular cell destruction between the cases groups of phase 1 and control group; however increased destruction of tubular cells could be seen by increasing the doses of the herb in phase 2. The serological results are shown in Table-II. The results showed that only in group 5, blood urea nitrogen (BUN) was increased. Higher doses of TP could increase BUN. Furthermore, based on Table-II, taking low doses of TP has not had significant effect on creatinine but 200 mg/kg dose had significant effect. The results showed that only in group 5 blood urea nitrogen was increased, while applying low doses of the herb, was not accompanied by changes in renal

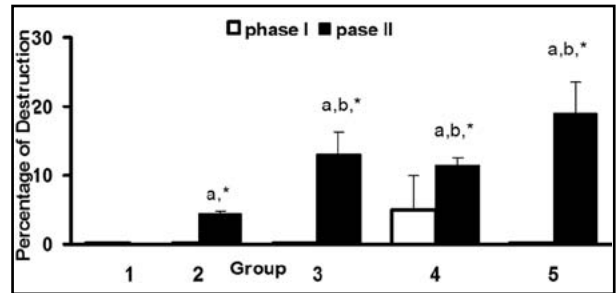


Fig. 4: Destruction percentage (%) in kidney tissue from five groups of experiment. Significant difference was detected from (a) group1, (b) group 2 and (*) phase I (P<0.05).

Table-II: Serological results of the study groups.

Variables	BUN				cr			
	Minimum	Maximum	Median	(Mean ± SD)	Minimum	Maximum	Median	(Mean ± SD)
1	31.0	91.0	37.5	43.0±17.5	0.2	1.0	0.8	0.8±0.2
2	23.0	35.0	26	27.3±3.7	0.2	1.0	0.8	0.8±0.2
3	21.0	33.0	28	26.9±3.9	0.6	1.0	0.8	0.8±0.1
4	18.0	41.0	31.5	31.1±6.6	0.6	1.0	0.9	0.9±0.2
5	18.0	104.0	65	60.43±0.9	0.7	13.0	1	2.2±3.8
Total	18.0	104.0	30.5	37.7±20.3	0.2	13.0	0.8	1.7±1.1

function test. This study also showed that using 200mg/kg of this herb raised the serum creatinine.

DISCUSSION

The results showed that injection of TP with different doses had toxic effects on renal tubule cells; however, the toxicity was significant after cessation of drug administration for 28 days. It can be concluded that TP injections did not show its effects immediately following drug injection, but after a period of 28 days, it has shown its effectiveness. The results also showed that destruction percentage was dose dependent. The plant *teucrium polium* is used worldwide in traditional and herbal medicine.³⁶⁻³⁷ However, it has been found to cause hepatotoxicity in humans.³⁷⁻⁴¹ Although the mechanism of *Teucrium polium* hepatotoxicity is unclear, teucrin A and several neoclerodan diterpenoids, present in the aerial parts of the plant, have been reported as the probable hepatotoxic precursors of this herb.⁴¹ In some reports, the liver injury has been associated with the presence of autoantibodies in the serum.⁴¹

Studies concerning renal side effects of *Teucrium polium* are quite scarce. The study conducted by Khleiefat et al., showed that chronic use of the T. polium extract for six weeks increased blood urea, which is consistent with our results.⁴² Also Khleiefat et al showed that the kidney was markedly damaged, consequently an increase in cytoplasmic vacuolation of the kidney cells after chronic treatment with 50 mg/kg of the plant was observed under the conditions of prolonged herb administration.⁴² In the study conducted by Khleiefat et al an increase in blood urea was observed, after six weeks treatment with this herb. In conclusion, the results of the present study demonstrates phytotoxic effect of the medicinal plant T. polium on the tubular cells of the kidney. To the best of our knowledge, this is the first report on the nephrotoxicity of this herb.⁴³⁻⁴⁸

Indeed, some of the medicinal plant can be a common source of kidney damage.⁴⁸⁻⁵¹ Drugs found to cause renal toxicity exert their toxic effects by one or more common mechanism.⁴⁶⁻⁵¹ This toxicity tends to be more common among certain patients and in specific clinical situations. Hence, successful prevention requires knowledge of pathogenic mechanisms of renal injury, related risk factors and preemptive measures, coupled with vigilance and early intervention.⁴⁶⁻⁵⁷

CONCLUSION

In this study we concluded that T. polium extract has renal tubular toxicity. The results suggest that

the consumption of TP for different conditions be carried out carefully because the renal injury in rats is significant and in humans can also have similar effects. Given that increasing the dose of TP, increased injury, we suggest that taking high doses of T. polium should be strictly avoided.

Conflict of Interest: The author declared no competing interests.

ACKNOWLEDGMENTS

The authors wish to thank, staffs of Medical Planets Research Center of Shahrekord University of Medical Sciences. This paper has been derived from an MD dissertation.

Funding/Support: This study is based on an M.D thesis and was supported by the research deputy of Shahrekord University of Medical Sciences (grant # 737).

REFERENCES

1. Rizk AM, Hammouda FM, Rimpler H, Kamel A. Iridoids and flavonoids of *Teucrium polium* herb. *Planta Med.* 1986;52:87-88.
2. Khajehdehi P. Turmeric: Reemerging of a neglected Asian traditional remedy. *J Nephropathology.* 2012;1(1):17-22.
3. Rahimi Z. ACE insertion/deletion (I/D) polymorphism and diabetic nephropathy. *J Nephropathology.* 2012;1(3):143-151.
4. Ljubuncic P, Dakwar S, Portnaya I, Cogan U, Azaizeh H, Bomzon A. Aqueous extracts of *Teucrium polium* possess remarkable antioxidant activity in vitro. *Evid Based Complement Alternat Med.* 2006;3(3):329-338.
5. Solati M, Mahboobi HR. Paraoxonase enzyme activity and dyslipidemia in chronic renal failure patients. *J Nephropathology.* 2012;1(3):123-125.
6. Baradaran A. Lipoprotein (a), type 2 diabetes and nephropathy; the mystery continues. *J Nephropathology.* 2012;1(3):126-129.
7. Ardestani A, Yazdanparast R, Jamshidi SH. Therapeutic effects of *Teucrium polium* extract on oxidative stress in pancreas of streptozotocin-induced diabetic rats. *J Med Food.* 2008;11(3):525-532.
8. Kari J. Epidemiology of chronic renal failure in children. *J Nephropathology.* 2012;1(3):162-163.
9. Talal A, Mohammad H, Vanni C. Composition of the Essential Oil from Jordanian Germander (*Teucrium polium* L.). *J Essent Oil Res.* 2006;8:97-99.
10. Cakir A, Emin Dum M, Harmandar M. Volatile constituents of *Teucrium polium* L. from Turkey. *J Essent Oil Res.* 1998;10:113-155.
11. Vokou D, Bessiere JM. Volatile constituents of *Teucrium polium*. *J Nat Prod.* 1985;48:498-499.
12. Autore G, Capasso F, De Fusco R, Fasulo MP, Lembo M, Mascolo N. Antipyretic and antibacterial actions of *Teucrium polium*. *Pharmacol. Res Commun.* 1984;16:21-29.
13. Tariq M, Ageel AM, Al-Yahya MA, Mossa JS, Al-Said MS. Anti-inflammatory activity of *Teucrium polium*. *Int J Tissue React.* 1986;11:185-188.
14. Kadifkova Panovska T, Kulevanov S, Stefov M. In vitro antioxidant activity of some *Teucrium* species (Lamiaceae). *Acta Pharm.* 2005;55:207-214.
15. Ljubuncic P, Dakwar S, Portnaya I, Cogan U, Azaizeh H, Bomzon A. Aqueous Extracts of *Teucrium polium* Possess Remarkable Antioxidant Activity in Vitro. *Evid Based Complement Alternat Med.* 2006;3:329-338.

16. Alkofahi A, Atta AH. Pharmacological screening of the anti-ulcerogenic effects of some Jordanian medicinal plants in rats. *J Ethnopharmacol.* 1999;67:341-345.
17. Galati EM, Mondello MR, D'Aquino A, Miceli N, Sanogo R, Tzakou O. Effects of *Teucrium divaricatum* Heldr. ssp. *divaricatum* decoction on experimental ulcer in rats. *J Ethnopharmacol.* 2000;72:337-342.
18. Abdollahi M, Karimpour H, Monsef-Esfehani HR. Antinociceptive effects of *Teucrium polium* L. total extract and essential oil in mouse writhing test. *Pharmacol Res.* 2003;48:31.
19. Baluch nejad mojarad T, Roghani M, Roghani-Dehkordi F. Antinociceptive effects of *Teucrium polium* leaf extract in the diabetic rat formalin test. *J Ethnopharmacol.* 2005;97:207-210.
20. Gharabeh NMN, Elayan HE, Salhab AS. Hypoglycemic effects of *Teucriumpolium*. *J Ethnopharmacol.* 1988;24:93-99.
21. Yazdanparast R, Esmaili MA, Ashrafi J. *Teucrium polium* extract effects pancreatic function of streptozotocin diabetic rats: A histopathological examination. *Iran Biomed J.* 2005;9:81-85.
22. Parsaee H, Shafiee-Nick R. Anti-Spasmic and Anti-nociceptive effects of *Teucrium polium* aqueous extract. *Iran Biomed J.* 2006;10:145-149.
23. Suleiman MS, Abdul-Ghani AS, Al-Khalil S, Amir R. Effect of *Teucrium polium* boiled leaf extract on intestinal motility and blood pressure. *J Ethnopharmacol.* 1988;22:111-116.
24. Sadraei H, Hajhashemi V, Ghannad A, Mohseni M. Antispasmodic effect of aerial part of *Teucrium polium* L. essential oil on rat isolated ileum in vitro. *Med J Islam Rep Iran.* 2001;14:355-358.
25. Rasekh HR, Khoshnood-Mansourkhani MJ, Kamalinejad M. Hypolipidemic effects of *Teucrium polium* in rats. *Fitoherapia.* 2001;72:937-939.
26. Shahraki MR, Arab MR, Mirimokaddam E, Palan MJ. The effect of *Teucrium polium* (Calpoureh) on liver function, serum lipids and glucose in diabetic male rats. *Iran Biomed J.* 2007;11:65-68.
27. Niazmand S, Erfanian Ahmadpoor M, Moosavian M, Derakhshan M. The positive inotropic and chronotropic effects of *Teucrium polium* L. extract on Guinea pig isolated heart. *Pharmacol online.* 2008;2:588-594. Dup on Ref. 28
28. Abu Sitta KH, Shomah MS, Salhab AS. Hepatotoxicity of *Teucrium polium* L. tea: supporting evidence in mice models. *Aust J Med Herbal.* 2009;21:106-109.
29. Rasekh HR, Khoshnood-Mansourkhani MJ, Kamalinejad M. Hypolipidemic effects of *Teucrium polium* in rats. *Fitoterapia.* 2001;72:937-939.
30. Rafieian-Kopaei M, Nasri H, Nematbakhsh M, Baradaran A, Gheissari A, Rouhi H. Erythropoietin ameliorates gentamicin-induced renal toxicity: A biochemical and histopathological study. *J Nephropathology.* 2012;1(2):109-116.
31. Amini FG, Rafieian-Kopaei M, Nematbakhsh M, Baradaran A, Nasri H. Ameliorative effects of metformin on renal histologic and biochemical alterations of gentamicin-induced renal toxicity in Wistar rats. *J Res Med Sci.* 2012;17:621-625.
32. Nematbakhsh M, Ashrafi F, Pezeshki Z, Fatahi Z, Kianpoor F, Sanei MH. A histopathological study of nephrotoxicity, hepatotoxicity or testicular toxicity: Which one is the first observation as side effect of Cisplatin induced toxicity in animal model. *J Nephropathology.* 2012;1(3):190-193.
33. Tavafi M. Inhibition of gentamicin-induced renal tubular cell necrosis. *J Nephropathology.* 2012;1(2):83-86.
34. Kadkhodae M. Erythropoietin; bright future and new hopes for an old drug. *J Nephropathology.* 2012;(2):81-82.
35. Ardalan MR, Samadifar Z, Vahedi A. Creatine monohydrate supplement induced interstitial nephritis. *J Nephropathology.* 2012;1(2):117-120.
36. Mattei A, Rucay P, Samuel D, Feray C, Reynes M, Bismuth H. Liver transplantation for severe acute liver failure after herbal medicine (*Teucriumpolium*) administration. *J Hepatol.* 1995;22:597.
37. Polymeros D, Kamberoglou D, Tzias V Acute cholestatic hepatitis caused by *Teucrium polium* (golden germander) with transient appearance of anti mitochondrial antibody. *J Clin Gastroenterol.* 2002;34:100-101.
38. Larrey D, Vial T, Pauwels A, Castot A, Biour M, David M, et al. Hepatitis after germander (*Teucriumchamaedrys*) administration: another instance of herbal medicine hepatotoxicity. *Ann Intern Med.* 1992;117:129-132.
39. Ben Yahia M, Mavier P, Metreau JM, Zafrani ES, Fabre M, Gatineau-Saillant G, et al. Chronic active hepatitis chronic active hepatitis. *Gastroenterol Clin Biol.* 1993;17:956-962.
40. Perez Alvarez J, Saez-Royuela F, Gento Pena E, Lopez Morante A, Velasco Oses A, Martin Lorente. J Acute hepatitis due to ingestion of *Teucriumchamaedrys* infusions. *Gastroenterol Hepatol.* 2001;24:240-243.
41. De Berardinis V, Moulis C, Maurice M, Beaune P, Pessayre D, Pompon D, et al. Human microsomal pertaining to or emanating from microsome. *Mol Pharmacol.* 2000;58:542-551.
42. Khleiefat K, Shakhanbeh J, Trawneh K. The chronic effect of *Teucrium polium* on some blood parameters and histopathology of liver and kidney in rat. *Turk J Biol.* 2002;26:65-71.
43. Gheissari A, Hemmatzadeh S, Merrikhi A, Fadaei Tehrani S, Madihi Y. chronic kidney disease in children: A report from a tertiary care center over 11 years. *J Nephropathology.* 2012;1(3):177-182.
44. Markowitz GS, Perazella MA. Drug-induced renal failure: a focus on tubule interstitial disease. *Clin Chim Acta.* 2005;351:31-47.
45. Gheissari A, Mehrasa P, Merrikhi A, Madihi Y. Acute kidney injury: A pediatric experience over 10 years at a tertiary care center. *J Nephropathology.* 2012;1(2):101-108.
46. Steele MR, Belostotsky V, Lau KK. The dangers of substance abuse in adolescents with chronic kidney disease: a review of the literature. *Cannt J.* 2012;22(1):15-22.
47. Assadi F. The epidemic of pediatric chronic kidney disease the danger of skepticism. *J Nephropathology.* 2012;1(2):61-64.
48. Yoshitomi T, Hirayama A, Nagasaki Y. The ROS scavenging and renal protective effects of pH-responsive nitroxide radical-containing nanoparticles. *Biomaterials.* 2011;32(31):8021-8028.
49. Gheshlaghi F. Malignant drug-induced rhabdomyolysis. *J Nephropathology.* 2012;1(1):59-60.
50. Nasri H. Sudden onset of acute renal failure requiring dialysis associated with large B-cell lymphoma of colon. *J Nephropathology.* 2012;1(3):202-206.
51. Tolouian R, Hernandez GT. Prediction of Diabetic Nephropathy: The need for a sweet biomarker. *J Nephropathology.* 2013;2(1):4-5.
52. Rouhi H, Ganji F. Effect of N-acetyl cysteine on serum Lipoprotein (a) and proteinuria in type 2 diabetic patients. *J Nephropathology.* 2013;2(1):61-66.
53. Tavafi M. Diabetic nephropathy and antioxidants. *J Nephropathology.* 2013;2(1):20-27.
54. Craig W, Beck L. Phytochemicals: Health Protective Effects. *Can J Diet Pract Res.* 1999;60:78-84.
55. Ashrafi F, Haghshenas S, Nematbakhsh M, Nasri H, Talebi A, Eshraghi-Jazi F. The Role of Magnesium Supplementation in Cisplatin-induced Nephrotoxicity in a Rat Model: No Nephroprotectant Effect. *Int J Prev Med.* 2012;3(9):637-643.
56. Eshraghi-Jazi F, Nematbakhsh M, Nasri H, Talebi A, Haghghi M, Pezeshki Z. The protective role of endogenous nitric oxide donor (L-arginine) in cisplatin-induced nephrotoxicity: Gender related differences in rat model. *J Res Med Sci.* 2011;16(11):1389-1396.
57. Hemati S, Arbab Jolfaie N, Gookizadeh A, Rafienia M, Ghavamnasiri M. The effects of vitamin E and selenium on cisplatin-induced nephrotoxicity in cancer patients treated with cisplatin-based chemotherapy: A randomized, placebo-controlled study. *J Res Med Sci.* 2012;17(Spec 1):S49-S58.