

Goblet cell carcinoid of the vermiform appendix

Shah Md. Badruddoza¹, Rukhshana Akhter Jahan²

ABSTRACT

A 38 years old female was admitted in a private hospital with history of abnormal uterine bleeding. Total abdominal hysterectomy (TAH) with unilateral salpingo-oophorectomy was performed. On request of the patient and their attendants, appendisectomy was done. Histopathology of the Vermiform appendix confirmed it was a goblet cell carcinoid.

KEY WORDS: Goblet cell carcinoid, Adenocarcinoid, Small-bowel neoplasms, Vermiform Appendix.

Pak J Med Sci July - September 2011 Vol. 27 No. 4 920-921

How to cite this article:

Badruddoza SMD, Jahan RA. Goblet cell carcinoid of the vermiform appendix. Pak J Med Sci 2011;27(4):920-921

INTRODUCTION

Goblet cell carcinoid, also variably known as adenocarcinoid, mucinous carcinoid, and crypt cell carcinoma, is a rare neoplasm with distinct histological and clinical features. It has histological features of carcinoid as well as adenocarcinoma and was initially described in a large series by Subbuswamy et al¹ in 1974. It is believed to arise from crypt base stem cells.² Generally it stains positive for synaptophysin, neuron-specific enolase, cytokeratin, chromogranin, and bioamines, which are characteristic of carcinoid lineage.^{3,4} However, it does not secrete the active hormones, i.e., serotonin and its by products, typically seen in carcinoid, at least not to the extent to be detectable in systemic circulation or enough to produce carcinoid symptoms. Goblet cell carcinoid produces mucin, a feature consistent with adenocarcinoma cell line.³

1. Shah Md. Badruddoza, MBBS, FCPS, Professor,
2. Rukhshana Akhter Jahan, MBBS, MD, Lecturer,
- 1, 2: Department of Pathology, Rajshahi Medical College, Bangladesh.

Correspondence:

Shah Md. Badruddoza, MBBS, FCPS (Histopathology), Professor, Department of Pathology, Rajshahi Medical College BANGLADESH.
E-mail: smdbd22@gmail.com

* Received for Publication: November 10, 2010

* Accepted: May 28, 2011

CASE REPORT

A 38 years old female was admitted in a private hospital with history of abnormal uterine bleeding for two years. On examination she was afebrile. Blood investigations revealed a high white cell count. Abdominal Ultrasonography was performed which showed bulky uterus. TAH with unilateral salpingo-oophorectomy was performed. On request of the patient and their attendants, appendisectomy was done.

Histopathology of the uterus with ovary revealed chronic cervicitis, leiomyoma and benign cystic lesion of ovary. Histopathology of Vermiform appendix showed a tumor at the tip of the appendix with clear margins of 6mm, composed of small glandular acini and individual cells with eosinophilic and focally granular cytoplasm occupying the submucosa (Figure-1 and 2). Overall the histological features were those of a goblet cell carcinoid tumor of the Vermiform appendix.

Post-operative recovery was uneventful and the patient was discharged on the tenth post-operative day. The patient was advised for follow up.

DISCUSSION

The diagnosis of goblet cell carcinoid of the appendix is essentially made on histological examination after surgery. This neoplasm has also been described as an adenocarcinoid, crypt cell carcinoma and goblet cell carcinoma. The preferred term, goblet cell carcinoma, was first coined in 1974 by

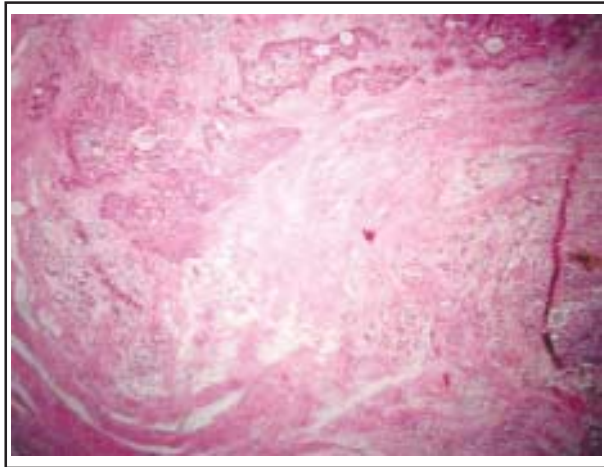


Fig-1: Goblet cell carcinoid of the vermiform appendix showing cells arranged in solid masses.

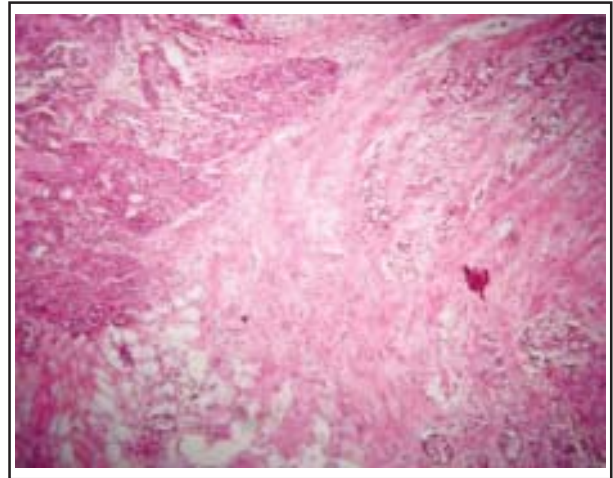


Fig-2: Goblet cell carcinoid of the vermiform appendix showing islands of cells distended with mucin.

Subbuswamy et al.¹ As the nomenclature implies, these tumors possess morphological features suggestive of both carcinoid and glandular differentiation. Reports from the medical literature on goblet cell carcinoid are sparse; however, the general consensus is that the clinical behaviour of goblet cell carcinoid is intermediate between carcinoid and adenocarcinoma.^{5,6} It is a more aggressive neoplasm compared with appendiceal carcinoid but is more indolent compared with adenocarcinoma.⁷ Most tumors are confined to the appendix at the time of diagnosis and the prognosis is good.⁸

They are characterized histologically by wide invasion of the mesoappendix, and clinically by delayed local recurrence and distant metastases. As the vast majority of these tumors are detected post-operatively, management centres on the need for re-operation and a right hemicolectomy is often curative.⁹ In patients with goblet cell carcinoids relative indications that may favour further surgery are:

- (A) Angioinvasion as an isolated finding.
- (B) Tumors with clear margins less than 2cm.
- (C) Mucin-producing tumors.¹⁰

Goblet cell carcinoid is a rare malignancy that arises mostly from the Vermiform appendix but can also occur in other parts of the small bowel. Its prognosis is intermediate between classic carcinoid and adenocarcinoma of the Vermiform appendix. Goblet cell carcinoid has a propensity for peritoneal seeding that leads to peritoneal carcinomatosis. These tumours are usually incidentally detected and though it is rare, prior knowledge about the tumour will help

preventing a diagnosis of a more aggressive neoplasm thereby hopefully improving the diagnosis, management and prognosis in patients with this rare entity.

REFERENCES

1. Subbuswamy SG, Gibbs NM, Ross CF, Morson BC. Goblet cell carcinoid of the appendix. *Cancer* 1974;34:338-44.
2. Warner TF, Seo IS. Goblet cell carcinoid of appendix: Ultrastructural features and histogenetic aspects. *Cancer* 1979;44:1700-6.
3. Hoffer H, Kloppel G, Heitz PU. Combined production of mucus, amines and peptides by goblet-cell carcinoids of the appendix and ileum. *Pathol Res Pract* 1984;178:555-61.
4. Burke AP, Sobin LH, Federspiel BH, Shekitka KM. Appendiceal carcinoids: Correlation of histology and immunohistochemistry. *Mod Pathol* 1989;2:630-7.
5. Anderson NH, Somerville JE, Johnston CF, Hayes DM, Buchanan KD, Sloan JM. Appendiceal goblet cell carcinoids: A clinicopathological and immunohistochemical study. *Histopathology* 1991;18:61-5.
6. Butler JA, Houshiar A, Lin F, Wilson SE. Goblet cell carcinoid of the appendix. *Am J Surg* 1994;168:685-7.
7. McCusker ME, Cote TR, Clegg LX, Sobin LH. Primary malignant neoplasms of the appendix: A population-based study from the surveillance, epidemiology and end-results program, 1973-1998. *Cancer* 2002;94:3307-12.
8. Jass JR. Tumors of the small and large intestines (including the anal region), in Christopher D. M. Fletcher, *Diagnostic Histopathology of Tumors*, Churchill Livingstone, Philadelphia, 3rd ed, 2007;1:391.
9. Kanthan R, Saxena A, Kanthan SC. Goblet cell carcinoids of the appendix: Immunophenotype and ultrastructural study. *Arch Pathol Lab Med* 2001;125:386-390.
10. Goede AC, Caplin ME, Winslet MC. Carcinoid tumor of the appendix. *Br J Surg* 2003;90:1317-1322.