

Mastoid subperiosteal abscess with osteolytic intracranial extension: A rare complication of mastoiditis in a young patient

Mohamad Irfan¹, Mohd Ibrahim Fairuz², Sidek Dinsuhaimi³

ABSTRACT

Acute mastoiditis complicated with subperiosteal abscess is a rare clinical entity in adult population. It is however a recognized risk in diabetes patient. We report a case of a young lady who was newly diagnosed as diabetes at presentation, presented with features of mastoiditis with subperiosteal abscess and adjacent intracranial abscess extension.

KEY WORDS: Mastoiditis, Subperiosteal abscess, Intracranial, Osteolytic.

Pak J Med Sci October - December 2011 Vol. 27 No. 5 1184-1186

How to cite this article:

Irfan M, Fairuz MI, Dinsuhaimi S. Mastoid subperiosteal abscess with osteolytic intracranial extension: A rare complication of mastoiditis in a young patient. Pak J Med Sci 2011;27(5):1184-1186

INTRODUCTION

Acute mastoiditis is a complication of acute otitis media. Hematogenous spread of infection through the vascular channels in the suprameatal (MacEwan's) triangle can induce erosion of the outer cortex of the mastoid process and cause postauricular subperiosteal abscess.

CASE SUMMARY

A 21 year old lady presented with history of right temporal region swelling and ipsilateral headache for two weeks duration which was progressively worsened. It was associated with fever, right sided otalgia and reduced hearing for one week duration prior to admission. She denied any history of ear

discharge, vertigo, history of trauma to the head and denied any orbital symptom. A week prior to hospitalization she did experience symptoms of hyperglycaemia like worsening of lethargic, nausea, extreme hunger and thirst.

Clinical examination revealed a fluctuant swelling measuring 8x5 cm at right temporoparietal region (Fig.1). Her right pinna was pushed inferiorly with postauricular fluctuant erythema. Otoscopic examination revealed a stenotic external auditory canal which was due to the inflammatory oedema with posterosuperior sagging of the canal wall. Part of the tympanic membrane visualized was bulging. Her leukocyte count was 11000/mm³ and she was febrile. The blood glucose was 23mmol/L and urine ketone was 2+. Urgent computed tomography of temporal bone that was performed demonstrated abscess formation within the right temporoparietal scalp region. It was associated with osteolytic changes of the adjacent right temporoparietal bone. The abscess has extended into the extradural area of right temporoparietal region corresponding to the bone defect site (Fig.2).

A diagnosis of right acute mastoiditis with subperiosteal abscess and extradural extension in a newly diagnosed diabetes mellitus was made. She was started on intravenous ceftriaxone. Neurosurgery consultation was made with regards to the temporoparietal extradural abscess. Insulin infusion was also commenced to optimize the blood glucose level.

1. Mohamad Irfan,
Senior Lecturer,
2. Mohd Ibrahim Fairuz,
Resident,
3. Sidek Dinsuhaimi
Professor & Consultant Otolologist,
- 1-3: Department of Otorhinolaryngology-Head & Neck Surgery,
School of Medical Sciences, University Sains Malaysia,
16150 Kota Bharu, Kelantan, Malaysia.

Correspondence:

Mohamad Irfan,
Department of Otorhinolaryngology-Head & Neck Surgery,
School of Medical Sciences, University Sains Malaysia,
16150 Kota Bharu, Kelantan, Malaysia.
E-mail: irfan@kb.usm.my

- * Received for Publication: February 5, 2011
- * Revision Received: August 6, 2011
- * Revision Accepted: August 15, 2011

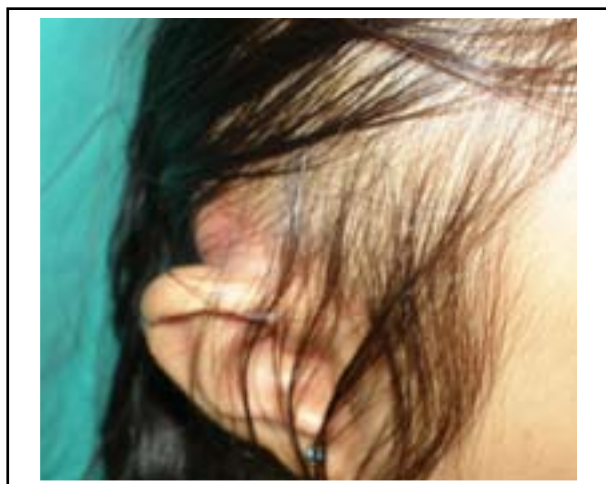

Fig.1: Fluctuant, erythematous and tender swelling at the right postauricular region pushing the helical pinna down facing.

The patient was planned for evacuation of abscess urgently. Although mastoidectomy was initially planned, we have opted to limit the operation for drainage of the subperiosteal abscess together with insertion of tympanostomy tube. This was in view of the presence of adjacent skull defect which might jeopardize the brain vital structure if mastoidectomy is undertaken. A postauricular incision was made to evacuate the abscess. It was few centimeters away from the area of skull defect site, following advice from the neurosurgical team. An attempt to insert tympanostomy tube failed due to the stenosed external auditory canal.

The surgical procedure went uneventfully. Intraoperatively 20 cc pus was drained out. After five days of wet dressing and intravenous antibiotics, the wound was relatively clean, the postauricular swelling and the stenotic external auditory canal had subsided. Operative wound managed to be closed five days later. Her blood glucose normalized and she was discharged on day eight of hospitalization. Pus culture grew *Klebsiella pneumoniae*. She was continued with oral ciprofloxacin for another two weeks after discharge. She was also prescribed with subcutaneous insulin. A repeat CT scan was obtained 2 weeks after discharge from ward, about a month after initial presentation, to assess the possibility of residual or recollection of abscess and future planning for mastoidectomy if needed. It showed the destruction of the underlying right temporoparietal bone appeared to be same. The initial abscess collection site at the adjacent extradural region was clear. Neurosurgically, she was under conservative management. During the last follow-

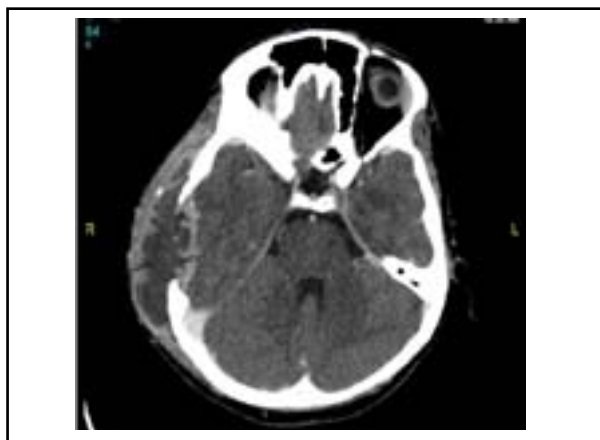

Fig.2: Axial CT scan of the temporal bone at initial presentation demonstrates scalp abscess formation at the right temporoparietal area (white arrow), with destruction of right temporoparietal bone and extension of abscess into adjacent extradural region.

up before she defaulted, the post auricular incision was completely healed. There was no ear discharge with normal external ear canal and tympanic membrane appearance. Mastoidectomy was reserved.

DISCUSSION

Mastoid abscess, a destructive bacterial infection of the mastoid bone and air cell system, is relatively uncommon today since the advent of modern antibiotic. However, it remains a potentially serious condition because of the complications that can lead to intracranial sequelae. Even though subperiosteal abscess is the most frequent complication of acute mastoiditis, it is a rare complication in adults.¹ Most mastoid abscess patients are afebrile and lack

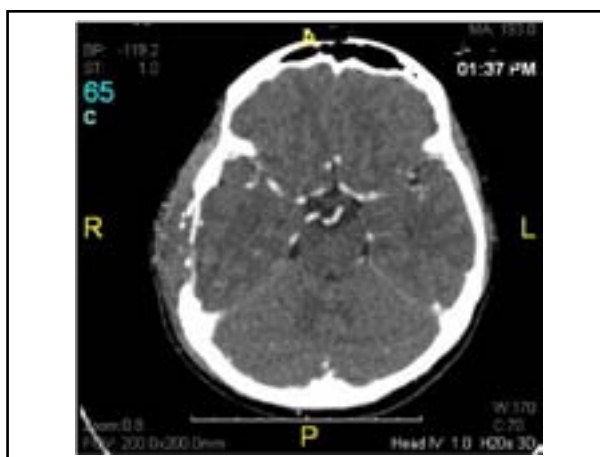


Fig.3: Axial CT scan of the temporal bone two weeks after incision and drainage and antibiotic administration demonstrates resolving abscess at both subperiosteal and adjacent extradural of right temporoparietal area. Bony destruction was the same.

systemic complaint.² Commonly, patient developed otalgia or evidence of acute otitis media. Clinically, the retroauricular sulcus is obliterated, downward and outward protrusion of the auricle and postauricular swelling can be appreciated. The periosteum in this area is easily separated, and when mucopus extends to this region, a subperiosteal abscess develops. Retroauricular fluctuance is indicating a subperiosteal abscess. These features are present in our patient. Laboratory evaluation is usually not helpful.² Diagnosis is mainly by keeping a high index of suspicion, and urgent CT scan of the temporal bone is mandatory.

Acute mastoiditis was considered to be a surgical disease, necessitating a mastoidectomy.³ Migirov proposed mastoidectomy should be performed within 48 hour of hospitalization.¹ A study by Hawkins and Dru (1983) found out the management could be limited to simple initial incision and drainage of the abscess with supportive antibiotic. He reported a response to conservative treatment in 57% of his cases (including five patients with subperiosteal abscess).⁴ Another study by Lahav concluded that postauricular pus aspiration of subperiosteal abscess in acute mastoiditis is an effective yet minimally invasive procedure. Mastoidectomy was said to be reserved for nonresponsive cases. They found out that the length of hospital stay reduced significantly.⁵

Our patient was not subjected for mastoidectomy and intracranial surgery intervention because we considered the potential morbidity and other

postoperative sequelae. While it appears that intravenous antibiotics and postauricular drainage is an effective technique for managing our patient, we would not neglect a close serial follow-up and neurosurgical consultation. A repeated CT scan was performed to exclude recurrence and to appreciate the efficacy of the treatment offered. This patient responded well with the treatment.

CONCLUSION

Acute mastoiditis with subperiosteal abscess and intracranial extension makes this case unusual, especially in a young previously healthy lady. It warrants a rapid but precise decision. Intravenous administration of antibiotic, tympanostomy tube and immediate evacuation of abscess avoids morbidity and potential complications of mastoid and intracranial surgery.

REFERENCES

1. Migirov L, Yakirevitch A, Kronenberg J. Mastoid subperiosteal abscess: A review of 51 cases. *Int J Pediatr Otorhinol.* 2005;69(11):1529-1533.
2. Tsai CJ, Guo YC, Tsai TL, Shiao AS. Zygomatic abscess complicating a huge mastoid cholesteatoma with intact eardrum. *Otolaryngol Head Neck Surg.* 2003;128(3):436-438.
3. Bauer PW, Brown KR, Jones DT. Mastoid subperiosteal abscess management in children. *Int J Pediatr Otorhinolaryngol.* 2002;63(3):185-188.
4. Hawkins DB, Dru D. Mastoid subperiosteal abscess. *Arch Otolaryngol.* 1983;109(6):369-371.
5. Lahav J, Handzel O, Gertler R, Yehuda M, Halperin D. Postauricular needle aspiration of subperiosteal abscess in acute mastoiditis. *Ann Otol Rhinol Laryngol.* 2005;114(4):323-327.