

HUMAN DIROFILARIASIS DUE TO *DIROFILARIA REPENS* IN AHVAZ - IRAN: A report of three cases

S. Maraghi¹, M. Rahdar², H. Akbari³, M. Radmanesh⁴, A.A. Saberi⁵,

ABSTRACT

Zoonotic filariasis due to *Dirofilaria repens* is prevalent in several regions of the world and because of recent rise in the number of human infections in countries of Europe, Africa and Asia, it is considered an emerging zoonoses in these continents. In 2002 three cases of *dirofilariasis* were diagnosed. The first case was a 34 year old man from Ahvaz referred to dermatologist with a nodule on the right cheek. During the excisional biopsy an adult dirofilaria measured 120 mm in length with white color was removed. The second case was a 37 year old man from a village around Ahvaz city who noticed a single moveable nodule with itching, irritation and swelling, 1.5 cm in diameter on his chest. The patient pressed the nodule and a white worm with 130 mm in length was revealed. The third case was a 35 year old man from Ahvaz presented at Imam Khomeini hospital because of eye irritation with symptoms and signs of itching, swelling and redness of the right eye. Examination noticed a living worm with the length of 110 mm which removed from the subconjunctival space. The worms were examined in parasitology department and based on morphological characters and microscopical identified as *Dirofilaria repens*. This is the second report of subcutaneous and the first report of subconjunctival dirofilariasis from Iran.

KEY WORDS : Dirofilariasis, *Dirofilaria Repens*.

Pak J Med Sci April - June 2006 Vol. 22 No. 2 211 - 213

INTRODUCTION

Dirofilaria (Noctiella) repens is a subcutaneous zoonotic parasite of domestic and wild carnivores, transmitted by zooanthrophilic mosquito vectors including species belong to *Aopheles*, *Culex* & *Aedes*.^{1,2} *Dirofilaria repens*

infection rarely seen in human. Humans get infection through blood sucking mosquitoes.^{3,4} Zoonotic subcutaneous filarial infection due to *Dirofilaria repens* are reported from human in various parts of the world.⁵⁻¹⁰ The first human dirofilariasis in Iran was reported from north part of the country⁴ and this is the second report of human cutaneous dirofilariasis due to *Dirofilaria repens* from Ahvaz city, the capital of Khouzestan Province, a tropical region in Southwestern part of Iran.

PATIENTS AND METHODS

The first case was a 34 year old man from Ahvaz referred to a dermatologist with a nodule on the right cheek. Physical examination revealed a single, firm and moveable nodule. During the excisional biopsy an adult white worm 120 mm in length was seen and identified as *Dirofilaria N. repens* (Fig – 1A).

Histopathology of nodule revealed an intense inflammatory cell reaction. The second case was a 37 year old man from a village around

1. Prof. S. Maraghi,
 2. Dr. M. Rahdar
 3. Dr. H. Akbari,
Department of Ophthalmology
 4. Dr. M. Radmanesh
Department of Dermatology
 5. Dr. A.A. Saberi,
General Practitioner
- 1-2: Department of Mycoparasitology,
School of Medicine,
Jundi-Shapour University of Medical Sciences,
Ahvaz, Iran.
- 3-5: Imam Khomeini Hospital,
Jundi-Shapour University of Medical Sciences,
Ahvaz, Iran.

Correspondence:
Professor S.Maraghi
E - Mail: maraghi_s@yahoo.com

- * Received for Publication April 27, 2005
Accepted December 24, 2005

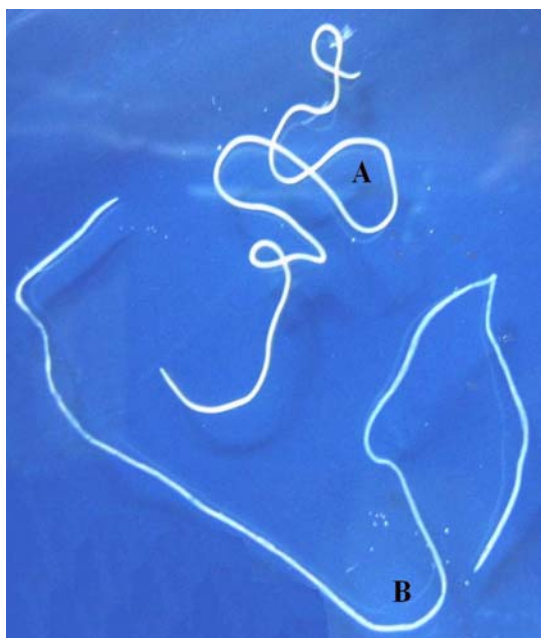

Fig-1: *Dirofilaria repens* isolated from the cheek A and chest B

Ahvaz city who noticed a single and moveable nodule measuring 15 mm in diameter on his chest. The patient pressed the nodule and a white worm 130 mm in length was observed and identified as *D(N) repens* (Fig-1B). No microfilaria were observed in peripheral blood and in the nodule or inside the worms. The third case was a 35 year old man from Ahvaz city who presented at Imam Khomeini Hospital because of itching, swelling and redness of the right eye. Examination showed a living white worm 110 mm in length which was removed from the subconjunctival space (Fig-2).

DISCUSSION

Inoculation of infective larvae of *D. repens* to human hosts during the bite of an infected insect results in invading of a variety of tissues and lead to formation of nodules.¹¹ The development of parasites in the unnatural human host is difficult and only rarely subcutaneous containing gravid female worms have been described.^{12,13} Infection in humans are usually asymptomatic and acute symptoms are noted only when living worms enter the

conjunctiva.^{14,15} Our patients complained of itching, swelling and local tenderness. This parasite can be located anywhere in the body,¹⁴⁻¹⁶ as in our patients were noted in face, chest and eye respectively. The diagnosis of human subcutaneous dirofilariasis can be made with certainty only after biopsy. Eosinophil count and measurement of Ig E levels are of limited value in screening of dirofilariasis in patients with subcutaneous lumps. Infection with *D. repens* induces high levels of specific IgG in humans.¹¹⁻¹⁷ However, serological tests contribute very little in detecting or identifying infections in human.¹⁷ The incidence of Human dirofilariasis has gradually increased within the last 30 years¹⁴ and more than 700 cases of *D. repens* were reported worldwide of over 300 were new cases reported between 1995 to 2000. The majority of cases were detected in Italy (66%) France (21.7%) Greece (8%) and Spain (4%).^{1,6-8} At least 22 cases of subcutaneous or subconjunctival human dirofilariasis and one case of pulmonary dirofilariasis have been reported in Greece.^{5,8-10}

CONCLUSIONS

Increasing of human dirofilariasis may be attributed to a change in social conditions, traveling and outdoor living, environmental changes with global warming, humidity and increase of mosquito vectors and breeding. The present cases were diagnosed in 2003 and suggests that human dirofilariasis should be considered in patients living in endemic areas.

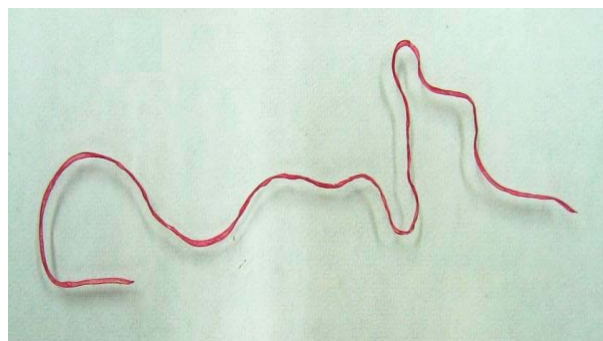


Fig-2: *Dirofilaria repens* isolated from subconjunctiva carmin staining

REFERENCES

1. Harrus S, Harmelin A, Rodrig S, Favia G. *Dirofilaria repens* infection in a dog in Israel. *Am J Trop Med Hyg* 1996; 15: 386-9.
2. Pampiglione S, Canstri-Trotti G, Rivas F. Human dirofilariasis due to *Dirofilaria Noctiella repens*: A review of world literature. *Parasitologia* 1995; 37:149-3.
3. Payan H M. Human infection with *Dirofilaria*. *Arch Dermatol* 1978; 114: 593-4.
4. Siavashi MR, Masoud J. Human cataneous dirofilariasis in Iran: A report of two cases. *Iran J Med Sci* 1995; 20: 85-6.
5. Marty P. Human dirofilariasis due to *Dirofilaria repens* in France. A review of reported cases. *Parasitologia* 1997: 383-6.
6. Muro A, Genchi C, Cordero M, Simon F. Human dirofilariasis in the European Union. *Parasitol Today* 1999; 15: 386-9.
7. Pampiglione S, Rivas F. Human dirofilariasis due to *Dirofilaria Noctiella repens*. An update of world literature from 1999 to 2000. *Parasitologia* 2000; 42: 231-54.
8. Pampiglione S, Rivas F, Angelic G, et al. Dirofilariasis due to *Dirofilaria repens* in Italy: An emergent zoonosis: Report of 60 new cases. *Histopathology* 2001; 38: 344-54.
9. Raccurt CP. Dirofilariasis, an emergency and underestimated zoonosis in France. *Med Trop Mais* 1999; 59: 389-400.
10. Vakialis N, Himonas CA. Human and canine dirofilariasis in Greece. *Parasitologia* 1997; 39: 389-91.
11. Santamaria B D, Sacco B, Muro A, Genchi C, Simon F, Cordero M. Serological diagnosis of subcutaneous dirofilariasis. *Clin Exp Dermatol* 1995; 20: 19-21.
12. Pampiglione S, Schmid C, Montaperto C. Human dirofilariasis: Discovery of a gravid female of *Dirofilaria repens* in a subcutaneous nodule. *Pathologica* 1992; 84: 77-81.
13. Pampiglione S, Canestri-Trotti G, Rivas F, Vakalis N. Human dirofilariasis in Greece. A review of reported cases and a description of a new subcutaneous case. *Ann Trop Med Parasitol* 1996; 90: 319-28.
14. Koltas IS, Orcan K, Duran N. Subconjunctival infection with *Dirofilaria repens*. *Annals of Saudi Medicine* 2002; 22: 75-7.
15. Ratnatung N, Wijesundera M S. Histopathological diagnosis of subcutaneous *Dirofilaria repens* infected in humans. *Southeast Asian J Trop Med Pub Health* 1990; 30: 375-8.
16. Macdougall LT, Magoon CC, Fritshe TR. *Dirofilaria repens* manifesting as a breast nodule. *Clini Pathol* 1992; 97: 625-30.
17. Simon F, Prieto G, Muro A, Canerini G, Cordero M, Genchi C. Human humoral immune response to *Dirofilaria Species*. *Parasitologia* 1997; 39: 397-400.