

GORLIN-GOLTZ SYNDROME

Atessa Pakfetrat¹, Farnaz Falaki²,
Reza Zare Mahmoodabadi³, Shadi Saghafi⁴

ABSTRACT

We report a case of Gorlin-Goltz syndrome in a 21-year-old man. Gorlin-Goltz syndrome (basal cell nevus syndrome) is an infrequent hereditary disease with its prevalence varying from 1/57,000 to 1/250,000. It is principally characterized by a wide range of developmental abnormalities. Main clinical manifestations include multiple odontogenic keratocysts of the jaws, facial basal cell carcinomas and skeletal anomalies. The prevalence varies from 1/57,000 to 1/250,000.

KEY WORDS: Gorlin-Goltz Syndrome, Nevoid Basal Cell Carcinoma Syndrome (NBCCS), Basal Cell Nevus Syndrome, Odontogenic Keratocyst, Basal Cell Carcinoma.

Pak J Med Sci January - March 2010 Vol. 26 No. 1 235-238

How to cite this article:

Pakfetrat A, Falaki F, Mahmoodabadi RZ, Saghafi S. Gorlin-Goltz Syndrome. Pak J Med Sci 2010;26(1):235-238

INTRODUCTION

Gorlin-Goltz syndrome was first reported by Binkley and Johnson in 1951. However, in 1960, Gorlin-Goltz defined the association of basal cell carcinoma, jaw cyst and bifid ribs, a combination which is now frequently known as Gorlin-Goltz syndrome or Nevoid Basal Cell Carcinoma Syndrome (NBCCS).¹ NBCCS is uncom-

mon with an annual incidence of one per 1 600 000 live births. The syndrome affects both sexes equally, and has both a sporadic and a familial incidence.² Its etiology is unknown, although the genetic studies relate this syndrome to a disturbance at gene level of chromosome 9 (9q22.3-q31). Sporadic cases appear due to spontaneous mutation.³

Individuals with no known affected family members may comprise up to 60% of all affected patients.⁴ Clinical features present in first to third decade of life.⁵ The diagnosis is based on the presence of two major or one major and two minor criteria.^{5,6} (Table-I)

CASE REPORT

A 21-year-old male patient presented at the Department of Oral Medicine, Mashhad Dental Faculty in October of 2008 with a chief complaint of pus discharge from the right mandibular posterior gingiva over the past four months. He hadn't felt any abnormal sensation and his dentist had extracted his second molar teeth of both jaws on the right side four months ago, but there was no sign of improvement of his

1. Atessa Pakfetrat, Assistant Professor, Department of Oral Medicine
2. Farnaz Falaki, Assistant Professor, Department of Oral Medicine
3. Reza Zare Mahmoodabadi, Assistant Professor, Department of Oral and Maxillofacial Pathology
4. Shadi Saghafi, Assistant Professor, Department of Oral and Maxillofacial Pathology
- 1-4: Faculty of Dentistry and Dental Research Center, Mashhad University of Medical Sciences, Iran

Correspondence:

Farnaz Falaki,
E mail: falakif@mums.ac.ir
farnazfalaki@yahoo.com

* Received for Publication: November 17, 2009

* Accepted: January 2, 2010

Table-I: The diagnostic criteria of Nevroid Basal Cell Carcinoma Syndrome

The diagnosis of NBCCS requires the presence of two major, or one major and two minor criteria:

Major criteria:

1. More than two basal cell carcinomas (BCC) or one BCC under the age of 20 years
2. Histologically-proven odontogenic keratocysts of the jaw
3. Three or more cutaneous palmar or plantar pits
4. Bifid, fused or markedly splayed ribs
5. First degree relative with NBCCS

Minor criteria:

Any one of the following features:

1. Proven macrocephaly, after adjustment for height
2. One of several orofacial congenital malformations: cleft lip or palate, frontal bossing, 'coarse face', moderate or severe hypertelorism
3. Other skeletal abnormalities: Sprengel deformity, marked pectus deformity, marked syndactyly of the digits
4. Radiological abnormalities: Bridging of the sella turcica, vertebral anomalies such as hemivertebrae, fusion or elongation of the vertebral bodies, modelling defects of the hands and feet, or flame shaped lucencies or the hands or feet
5. Ovarian fibroma
6. Medulloblastoma

condition.

There were also swellings on both sides of mandible and maxilla which started two years ago. In addition to these there were the extra-oral features of prominent forehead and frontal bossing, mild ocular hypertelorism and mild mandibular prognatism (Fig.1). There were also multiple dermoid cysts in the left hand (Fig.2).

Intra oral examination revealed a slight bilateral bucco-lingual expansion in posterior parts of both jaws. There was no tenderness and white creamy exudate oozed out of the area distal to tooth 47 by applying pressure. Missing of 8 teeth was also observed.

A panoramic radiographic view showed multiple well-defined, well-corticated radiolucencies in all four quadrants. Impacted teeth were observed in ramus of mandible bilaterally and right side of maxilla. Displacement of impacted teeth was also observed (Fig.3).

Diagnosis of multiple OKCs was made clinically & radiographically. The patient's chest and skull radiography were unremarkable (Fig.4).

The father of the patient had had similar clinical picture and history of multiple jaw surgeries for cysts (OKCs) years ago but complete details of these surgeries were not available, as they were performed in another hospital more than 10 years ago. He died as a result of osteomyelitis of the jaw bones because of inadequate treatment.

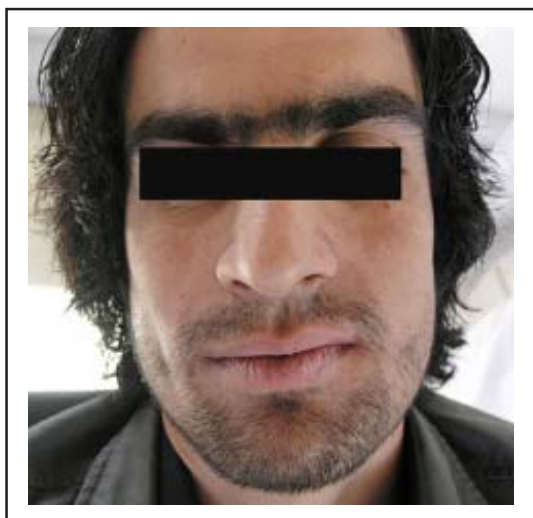

Figure-1: Prominent forehead, frontal bossing and mild mandibular prognatism.

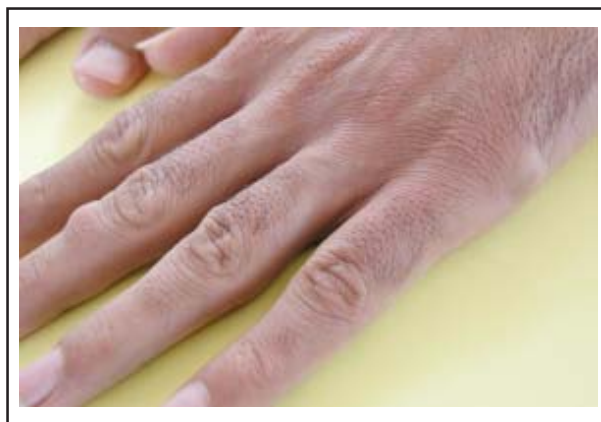

Figure-2: Epidermoid cysts on the hands of the patient.

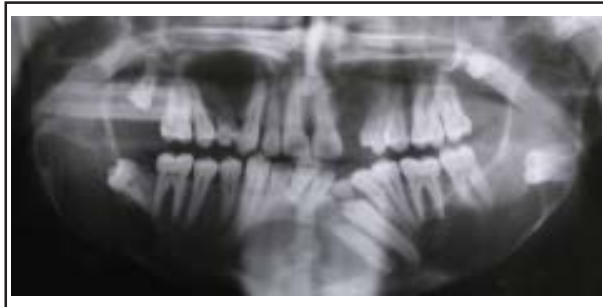

Figure-3: Panoramic radiography showed multiple well-defined, radiolucencies in all four quadrants and impacted teeth.

Diagnosis of multiple OKCs or Gorlin-Goltz syndrome was made for the patients based on clinical findings. Incisional biopsy from the left side of the mandible was performed under general anesthesia and the cutaneous lesion was removed by excisional biopsy. Histopathology revealed a thin, uniform layer of parakeratinized stratified squamous epithelium with a corrugated surface and a prominent palisaded basal cell layer of the jaw cyst. The epithelial lining was supported by a thin, fibrous connective tissue wall containing a mild chronic inflammatory cell infiltrate. The cysts were filled with eosinophilic flakes composed of keratin (Fig.5). Histopathological examination of the cutaneous lesion revealed orthokeratinized stratified squamous epithelium in the lining of a cyst with a granular cell layer. The wall of the cyst was composed of fibrous connective tissue and the lumen was filled with keratin. The diagnosis of epidermal cysts was confirmed

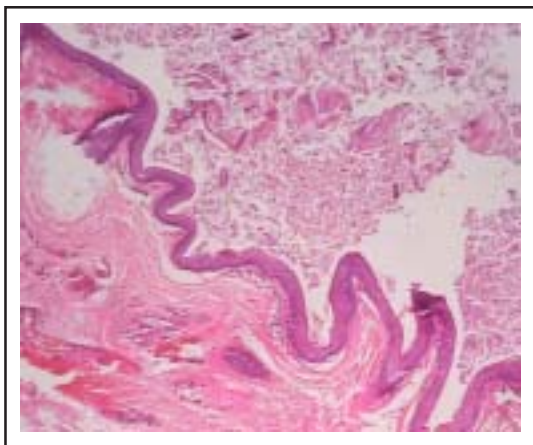


Figure-5: Histopathological picture of the biopsy specimen.

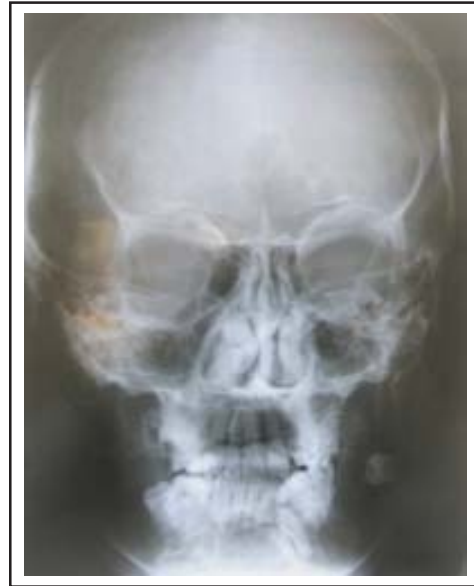

Figure-4: Skull radiography was normal.

(Fig-6). The patient was referred to the Department of Head & Neck Surgery for further treatments.

DISCUSSION

Multiple odontogenic keratocysts are often among the first signs of NBCCS.⁷ As they are locally destructive and cause little lateral expansion, they are always incidentally found in radiography, although they may present clinically if become infected or symptoms like swelling or infection happened.⁸ The cysts can also cause displacement of the developing teeth, impacted

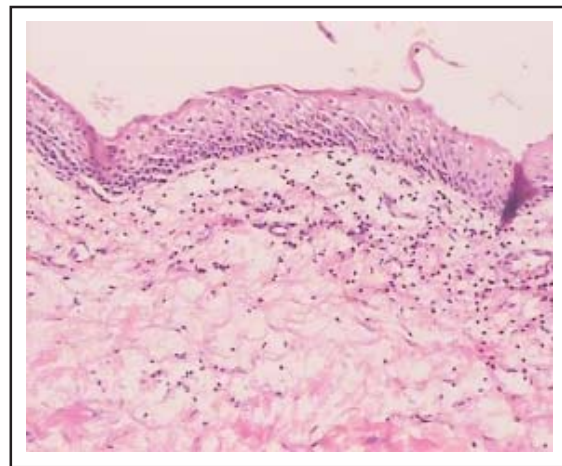


Figure-6: Epidermoid cyst, Lumen with keratin inside, Stratified squamous epithelium and fibrous wall. (H&E ×40)

teeth and sometimes root resorption. OKCs have more predilections for mandible especially molar ramus region. As previously mentioned, our patient presented with the main complaint of mild expansion and in radiography several radiolucent lesions were observed in both jaws.

Although Multiple OKCs can occur as a part of some rare dermatological syndromes, such as Bazex syndrome, trichoepithelioma papulosum multiplex or Torre's syndrome, Noonan syndrome, Ehler-Danlos syndrome or other syndromes⁹, but this patient was apparently healthy and had no features suggestive of these syndromes.

The OKCs associated with NBCCS are more aggressive and these cysts have higher recurrence rates (82%) compared with solitary keratocysts (61%), it is believed that this biologic behavior is due to a higher rate of proliferation of the epithelial lining.⁹ Histopathologically parakeratinization are more frequent among OKCs associated with NBCCS than in solitary keratocysts⁸, as observed in our patient. The present case also exhibited the typical feature of temporo - parietal bossing with skull having pagetoid appearance, prominent supra-orbital ridge giving the eye a sunken appearance, broad nasal root, hypertelorism which are minor criteria for NBCCS.

Despite the name of the syndrome, multiple basal cell carcinomas occur only in 50% of cases.¹⁰ BCC most often proliferate between puberty and 35 years of age. Other skin signs are benign dermal cysts. Small keratin-filled cysts (milia) can be found on the face in 30% of cases. In our patient several dermal cysts were observed on the skin of hands which were confirmed by histopathologically.

The treatment of this syndrome is multidisciplinary, in its clinical management and follow up, the odonto-stomatologist, the maxillofacial surgeon and several other medical specialists are involved.³ A complete

clinical examination and histopathologic analysis must be performed to detect any features associated with this syndrome.¹⁰

The possibility, in this young patient, of developing other features of NBCCS in the future cannot be excluded. So in any patient with multiple OKCs, the possibility of NBCCS must be considered. Since regular and close follow-up of NBCCS patients can allow early diagnosis of new OKCs, an annual dental panoramic radiograph is suggested between the ages of 8 and 40 years.²

REFERENCES

1. Karthiga KS, Sivapatha Sundharam B, Manikandan R. Nevoid basal cell carcinoma syndrome. *Indian J Dent Res* 2006;17(1):50-3.
2. Bakaen G, Rajab LD, Sawair FA, Hamdan MA, Dallal ND Nevoid basal cell carcinoma syndrome: a review of the literature and a report of a case. *Int J Paediatr Dent* 2004;14(4):279-87
3. Diaz-Fernandez JM, Infante-Cossio P, Belmonte-Caro R, Ruiz-Laza L, Garcia-Perla-Garcia A, Gutierrez-Perez JL. Basal cell nevus syndrome. Presentation of six cases and literature review. *Med Oral Patol Oral Cir Bucal* 2005;10(1):E57-66.
4. Bonifas JM, Bare JW, Kerschmann RL, Master SP, Epstein EH. Parental origin of chromosome 9q22.3-q31 lost in basal cell carcinomas from basal cell nevus syndrome patients. *Hum Mol Genet* 1994;3:447-448.
5. Evans DGR, Farndon LA, Burnell LD, Rao Gattamaneni H, Birch JM. The incidence of Gorlin syndrome in 173 consecutive cases of medulloblastoma. *British J Cancer* 1999;64(5):959-61.
6. Ortega Garcia de Amezaga A, Garcia Arregui O, Zepeda Nuño S, Acha Sagredo A, Aguirre Urizar JM. Gorlin-Goltz syndrome: clinicopathologic aspects. *Med Oral Patol Oral Cir Bucal*. 2008;13(6):E338-43.
7. Blanchard SB. Odontogenic keratocysts: review of the literature and report of a case. *J Periodontol* 1997;68:306-311.
8. Muzzio LL. Nevoid basal cell carcinoma syndrome (Gorlin syndrome). *Orphanet J Rare Dis* 2008;3:32.
9. Lo Muzio L, Nocini P, Bucci P. Early diagnosis of nevoid basal cell carcinoma syndrome. *J Ameri Dental Assoc* 1999;130:669-674.
10. Greenberg MS, Glick M. *Burket's Oral Medicine*. 10th ed. BC Decker Inc; 2008:149-50.