

SHORT TERM RESULTS OF CONCOMITANT INTRANASAL ADMINISTRATION OF SALMON CALCITONIN IN INTERTROCHANTERIC FEMUR FRACTURES OPERATED UPON USING DYNAMIC HIP SCREW

Nasser Sarrafan¹, Seyed Abdolhossein Mehdinasab², Ahmad Dashtbozorg³,
Mohammad Reza Pipelzadeh⁴, Hooman Pedram⁵

ABSTRACT

Objectives: To evaluate the effect of nasal calcitonin spray in union of the intertrochanteric fractures of elderly female patients.

Methodology: Fifty female patients aged above 60 years (mean age = 73.9 years) old with Intertrochanteric fracture were operated from Sept 2005 to August 2006 by dynamic hip screw. In a randomized controlled trial, patients were divided into two groups A and B. Each group had 25 patients. After hospitalization 200 IU of salmon calcitonin as a single dose nasal spray was administered to patients of group A, daily for 3 months and a placebo spray was used in patients of group B. serum level of alkaline phosphatase and time of appearance of a bone callus in a plain radiograph were compared in the two groups twice weekly for 8 weeks.

Results: About 72% of patients in group A showed signs of union as the appearing of bone callus in radiograph in the 3rd week, compared to 40% in group B. Twenty of patients in group A (80 %) and 20% of the group B had an increase in serum alkaline phosphatase from the 15th day after injury ($P < 0.005$). Meanwhile alkaline phosphatase levels in group A was 185 IU on 15 the day compared to 140 IU on group B. and values were 443 IU and 210 IU on 90th day respectively. As regards the time of appearance of the union signs in a plain bone radiograph, 72% of patients in group A have shown signs of appearance of a bone callus in the 3rd week after surgery, while the rate has been 40 % in group B.

Conclusion: Using nasal spray of calcitonin in old females with intertrochanteric fracture is effective for earlier and increased rate of bone union.

KEY WORDS: Calcitonin, Intertrochanteric fractures, Alkaline phosphatase, Fracture union.

Pak J Med Sci January - March 2010 Vol. 26 No. 1 54-58

How to cite this article:

Sarrafan N, Mehdinasab SA, Dashtbozorg A, Pipelzadeh MR, Pedram H. Short term results of concomitant intranasal administration of Salmon Calcitonin in Intertrochanteric femur fractures operated upon using dynamic hip screw. Pak J Med Sci 2010;26(1):54-58

Correspondence

Dr. Seyed Abdolhossein Mehdinasab
Associated Professor of Orthopedic Surgery,
Emam Khomeini Hospital,
Ahvaz, Iran.
E-mail: hmehdinasab@yahoo.com

- * Received for Publication: April 10, 2009
- * Revision Received: December 21, 2009
- * Revision Accepted: December 22nd 2009

INTRODUCTION

Hip fracture is common in elderly people. The existence of osteoporosis in patients with intertrochanteric fracture had more effects particularly on the outcome of treatment after internal fixation because there is a direct relationship between the rate of osteoporosis and quality of fixation. Therefore the bone content will affect the outcome of treatment.

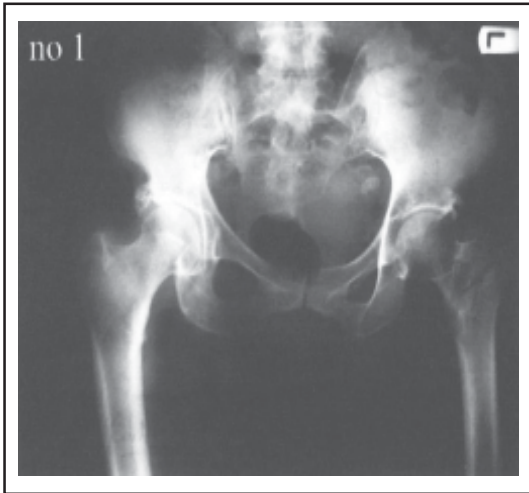

Fig-1: Radiography of a patient before treatment.

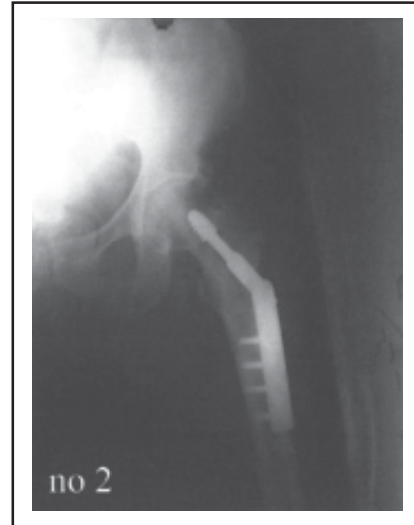

Fig-2: After treatment.

Singh et al considered his criteria in diagnosis of type and the rate of osteoporosis based on the bone trabeculae mass that is seen in radiography of the proximal femur.¹ the increased rate of osteoporosis will increase the risk of bone fracture, the 90% of, intertrochanteric fracture are just due to falling down.²

Complications of intertrochanteric fractures include failure of device nonunion, malunion, femoral head osteonecrosis, thromboembolic events and mortality. It is well proven that the bone content is directly associated with the risk of fracture in the hip region. Reduction of strength and the rate of bone content increase the risk of fracture in aging people.³

Therefore a general accepted approach to prevent the appearance of hip fractures and its post-complications is to reduce the rate and the

speed of bone content loss using substances like progesterone, calcium, Vitamin D and its metabolites, and calcitonin.⁴ calcitonin is a peptide composed of 32 amino acids which binds to osteoclasts and inhibits bone resorption.⁵⁻⁶ Postmenopausal female patients are especially at risk of bone fracture.

We evaluated the efficacy of intra nasally administered calcitonin on speed of bone healing in elderly female patients.

METHODOLOGY

All the patients with intertrochanteric fracture of the hip aged 60 to 80, (mean 73.9 years) who were referred to our hospital from 30.9.2005 through 30.9.2006 treated by D.H.S fixation, entered the study.

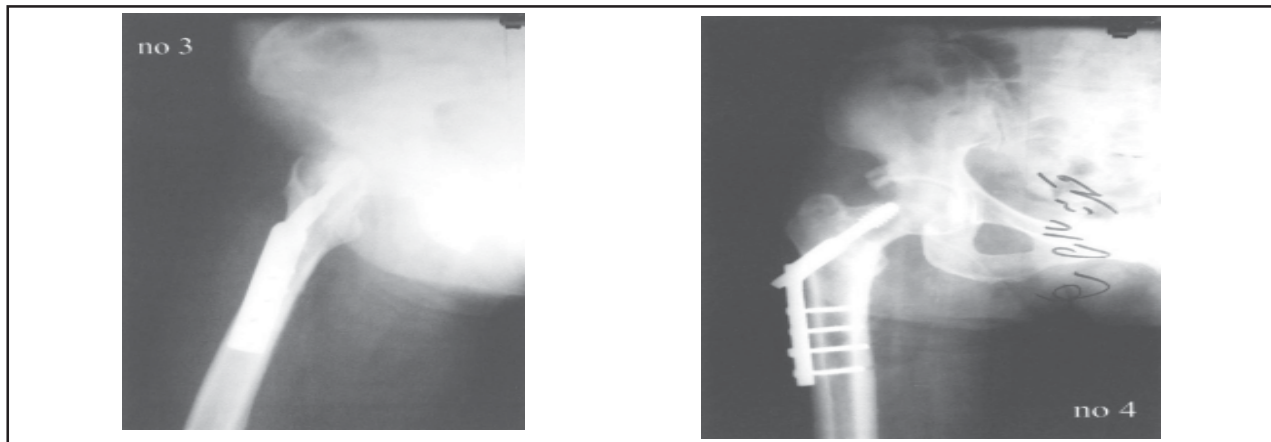


Fig-3 & 4: Radiography showing callus formation (4 weeks after surgery)

Table-I: The average changes in serum alkaline Phosphatase before and after treatment with calcitonin.

<i>Alkaline. Phosphates IU/Liter</i>	<i>Group A Treatment (mean ±SD)</i>	<i>Group B Control (mean ±SD)</i>
Before treatment	95 (±19)	101 (± 21)
15 Days after treatment	185 (±45)	140 (±51)
90 Days after treatment	443 (± 89)	210 (± 78)

The inclusion criteria were as follows:

1. Lack of localized or systemic metabolic disorder. Not taking drugs that affect bone metabolism.
2. Having minimal daily activity
3. Not taking alcohol, narcotics or smoking
4. No known malignancy, liver or gastrointestinal diseases
5. No obstructive biliary disorder

This is a randomized clinical controlled study. Fifty consecutive patients were divided into two groups A and B, each group included 25 patients. patients were randomly chosen according to odd or even file number. After hospitalization 200 IU of salmon calcitonin daily as a single dose by nasal spray, was used in patients of group A and continued for three month. Patients of group B used an ineffective spray (distilled water) in the same way. The obtained outcomes of each patient were recorded and completed as a check list and a statistical analysis was done.

1. The alkaline phosphatase level in the serum in both groups of patients was measured in the 1st, 15th, and 90th days.
2. The mean time of observing the bone radiologic union signs as the onset of appearance of the bone callus was recorded in two

groups between the 1st to the 8th weeks after surgery based on the simple hip radiography taken every two weeks. T- Test was used to compare the alkaline phosphatase activities in case group (A) and control group (B). Patients were informed of the plan of treatment and a written consent was taken from them.

The ethical review committees of the hospital approved the study procedures. No conflict of interest needs to be declared in respect of this study. The authors did not receive grants or funding in support of their study. The study was approved by Ethics committee of our university.

RESULTS

The average values of alkaline phosphatase before and after treatment are shown in. Table-I. In patients of group (A) treated with calcitonin, higher activity of Serum alkaline Phosphates was noted on 15th and 90th day after injury ($p^* < 0.005$).

Findings in Table-I reveal the mean measured quantities for alkaline phosphatase in the 1st, 15th and the 90th days after injury. According to the observed changes in alkaline phosphatase in both case and control groups on the 90th day of treatment 20 (80%) of patients in group A showed an increase in alkaline phosphatase since 15th day after injury compared to only 5 (20%) in control group.

As shown in Table-II, 72% of patients in group A have shown signs of union as the appearing of bone callus in a plain hip radiograph in the 3rd week, while the rate has been 40% in group B following same period. Average time of appearing bone callus in a simple hip radiography in patients of groups A and B had been equal to 3.12 and 3.72 weeks respectively < 0.001

Table-II: Appearance of callus formation in both groups.

<i>Week</i>	<i>No. of patients in Group A</i>	<i>Group A (%)</i>	<i>No. of patients in Group B</i>	<i>Group B (%)</i>
Second	2	8%	-	0%
Third	18	72%	10	40%
Fourth	5	20%	12	48%
Fifth	-	-	3	12%

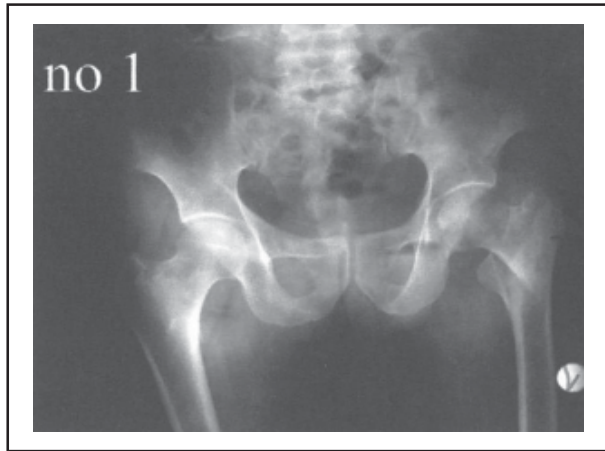


Fig-5: Radiography before treatment.

Sample radiographs of patients in control group B: A 75 years old patient with intertrochanteric fracture of left hip, (Fig-5-6 Type II who was hospitalized on and underwent D.H.S surgery. There was no sign of union in the fracture area after second follow up on (4 weeks after surgery).

There was a significant difference between these two groups. Signs of union have been seen earlier in the radiography of patients in group A compared with group B .Rehabilitation program and weight bearing for both groups was similar.

DISCUSSION

Hip fracture is a common debilitating pathology in old people. Intertrochanteric fractures included 30% of all admitted patients in US and

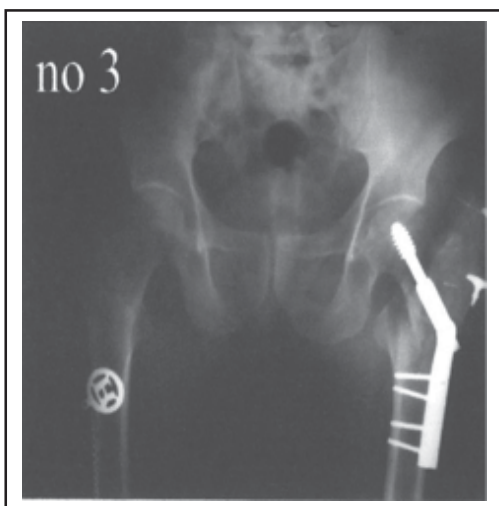


Fig-7: Four weeks after surgery, no callus formation is seen

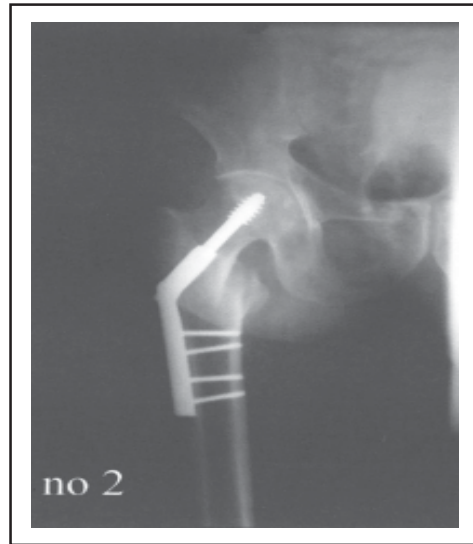

Fig-6: Post operative radiography.

250,000 hip fractures occur annually, and it is estimated that the rate would be increased to two times by the year 2050.⁷ Intertrochanteric fracture occurs more frequently in female population (63/100,000 compared to 34/100,000 in male).⁸

This fracture has a major impact on general health, with morbidity and mortality rate of 7% to 27% within 3 months.⁹ Epidemiologic studies have shown that intertrochanteric fractures has increased due to the improved life expectancy.²

In order to decrease the complications and morbidity, calcitonin may be effective. Ellerington MC. et al reported a nasal calcitonin at a dosage of 200 units per day appears to increase bone mass in the spine and decrease spinal fractures by 37 %.¹⁰

Lyritys G concluded that the calcitonin can stimulate end ossification during fracture healing, causing an increase in callus maturation.¹¹ Alkaline phosphatase increases in several disease entities including Paget disease of bone, osteoblastic metastatic carcinoma of bone and in liver diseases.¹² We excluded patients with liver disease or bone malignancy from study. Alkaline phosphatase rose significantly more in calcitonin group $p < 0.005$.

There are numerous experimental studies in the literature investigating the action of calcitonin on fracture healing.¹³ In a study carried out

by T. Karachalioss et al. on 50 patients similar results were achieved.¹⁴

Our data show that 72% of patients in group A had signs of union on the 3rd week after surgery, whereas the rate was 40% in control group $p < 0.001$. Mean time of appearance of the bone callus in case group was 3.12 weeks. While the rate was 3.72 weeks in control group. We selected female gender because this fracture is a more frequent post menopausal osteoporotic problem in our population.

Limitations of the Study: We could not control plain X-ray with CT scans due to economic reasons. a larger sample would have been more conclusive. In a similar study performed by Hausko TM et al on 260 patients with mean age of 65 years with hip fracture, 84% of patients in case group showed signs of union in a plain radiography during 3 month, while the signs of fractures union was seen in 63% of patients in control group.¹⁵

CONCLUSIONS

Results of this study using nasal spray of calcitonin as an adjuvant in elderly intertrochanteric fractures can increase serum alkaline phosphatase and induce earlier fracture union. Calcitonin has a high safety index, we recommend it in elderly patients with intertrochanteric fracture in addition to routine internal fixation. However more studies are probably required for routine use in all ages. Sample radiographies of patients in case group A: A 65 year old woman with intertrochanteric fracture of left hip, (Fig-1-4). The signs of union as the appearance of bone callus were seen in the radiography at 4 weeks after surgery.

REFERENCES

1. AR. Maini PS. Changes in trabecular pattern of upper end of the femur as an index of Singh Monarch osteoporosis. J Bone Joints Surgery Am 1970;52:457-67.
2. WC Hayes. Biomechanics of falls and hip fracture prevention in the elderly: Proc. AAOS workshop on prevention of falls and hip fractures in elderly, Chicago IL, 1994;41-65.
3. Cummings S, Black D, Nevitt M Bone. Density at various sites for prediction of hip fractures. Lancet 1993;341:72-5.

4. Laros GS. The role of osteoporosis in intertrochanteric fracture. Clin Orthop 1980;101:110.
5. Carsten TH Jr, Feinblatt JD. Future horizons for calcitonin: A US perspective. Calcif Tissue Int 1991;49(2):52.
6. Eastell R. Treatment of post menopausal osteoporosis: N Eng J Med 1998;338:736.
7. Rogrse FB, Shocklord SR, Keller MS. Early fixation reduces morbidity and mortality in elderly patients with hip fractures from low impact falls. J Trauma. 1995;39:261-5.
8. Koval KJ, Aharonoff GB, Rokito AS, Lyon T, Zuckerman JD. Patients with femoral neck and intertrochanteric fractures. Are they the same?. Clin Orthopaedic 1996;330:166-172.
9. White, B.L; Fisher, W.D; Laurin. C.A. Rate of mortality for elderly patients after fracture of the hip in the 1980s. J Bone Joint Surg. Am 69: 1335-1340,
10. Ellerington, MC, hillard , T.C; Whitcroft, S.I.J. Intranasal salmon calcitonin for prevention and treatment of postmenopausal. Osteoporosis. (calcify tissue int 59.6, 1996)
11. Lyritis G, Manolakis H, Bitounins B, Badras L, Ioannidis Th. Mitsou A. The effect of salmon calcitonin on fracture healing in rats. Proceedings 7th International Congress of Orthopaedics. Rome 1982;313-314.
12. Wikinson JH. The use of enzymes in osteogenesis. British Journal of Hospital Medicine 1997.18,343-351
13. Paavolainen P, Taivainen T, Michelsson JE, Lalla M, Penttinen R. Calcitonin and fracture healing. An experimental study on rats. J Orthop Res 1989;100-106.
14. Karachalioss T, Lyritis GP, Kaloudis, Roidis N, Ktsiri M. The effects of Calcitonin on acute bone loss after peritrochanteric Fractures. A prospective randomized trial. J Bone Joints Surgery 2003;12:352.
15. Huusko TM, Karppi P, Kautiainen H, Suominen H, Avikainen V, Sulkava R. Intranasal Calcitonin treatment in patients with hip fractures, randomised, double - blind, clinically-controlled trial, Department of Public Health General Practice, Finland 13.02.2007

Authors:

1. Nasser Sarrafan, Associated Professor of Orthopedic Surgery
 2. Seyed Abdolhossein Mehdinasab, Associated Professor of Orthopedic Surgery
 3. Ahmad Dashtbozorg, Assistant Professor of Orthopedic Surgery
 4. Mohammad Reza Pipelzadeh, Associated Professor of anesthesiology
 5. Hooman Pedram, Orthopedic Surgeon
- 1-5: Emam Khomeini Hospital, Jundishapur University of Medical Sciences, Ahvaz, Iran.