

GRAY SCALE AND DOPPLER ULTRA-SOUND IN THE DIAGNOSIS OF PAINLESS SCROTAL MASSES

Zahoor Ahmed Khatri¹, Saba Sohail²

ABSTRACT

Objective: To determine the role of gray scale and Doppler Ultrasound in the diagnosis of painless scrotal masses.

Methodology: It was a descriptive study conducted at Department of radiology, Dow University of Health Science (DUHS) and Civil Hospital Karachi (CHK) from June 2006 to June 2007. Adult patients with painless scrotal mass referred for ultrasound examination, were included in the study. All subjects were scanned with 11 MHz linear transducer on NEMIO 17 scanner in supine position and erect posture as and when needed. Gray scale ultrasound was first conducted to determine the size, location and echogenicity of the lesion. Doppler ultrasound was done to assess and document the blood flow, spectrum, and velocity of flow and indices in the epididymis, as well as in the lesion. Accuracy of Doppler scan was determined against histopathology of the respected specimen in case of tumors and against surgical findings in the benign lesions.

Results: The average age of the patients was 38.51 ± 9.4 years. The most common scrotal mass was hydrocele (n=24, 34.29%) followed by varicocele (n=13, 18.57%), testicular tumors (n= 12, 17.14%), spermatocele (n = 11, 15.71%) and epididymal cyst (n=10, 14.29%). Out of 12 testicular tumors, there were 05 cases of seminoma (41.7%), 02 of cases of embryonal cell carcinomas (16.7%), two epidermoid cysts (16.7%) and 01(8.3%)each of teratoma, choriocarcinoma with metastasis and testicular lymphoma Sensitivity and positive predictive value of the ultrasound were 66.7% and 100%.

Conclusion: Gray scale ultrasound in combination with Doppler ultra sound is a good imaging technique in patients presenting with painless scrotal masses. Benign masses are more accurately diagnosed than tumors that require histopathology for exact tissue characterization.

KEY WORDS: Ultrasound, Painless scrotal mass, Testicular tumor, Doppler scan.

Pak J Med Sci January - March 2010 Vol. 26 No. 1 178-182

How to cite this article:

Khatri ZA, Sohail S. Gray scale and doppler ultra-sound in the diagnosis of painless scrotal masses. Pak J Med Sci 2010;26(1):178-182

1. Dr. Zahoor Ahmed Khatri, MBBS,
 2. Dr. Saba Sohail, MCPS, FCPS
- 1-2: Department of radiology
Dow University of Health Sciences &
Civil Hospital, Karachi - Pakistan.

Correspondence

Dr. Saba Sohail,
4/ II, Creek lane 8 Phase VII, DHA, Karachi - Pakistan.
E-mail: drsabasohail@hotmail.com

- * Received for Publication: July 15, 2009
- * Revision Received: July 18, 2009
- * Revision Accepted: December 3, 2009

INTRODUCTION

Painless scrotal masses are common clinical presentation requiring imaging evaluation. Testicular and scrotal related disorders account for 3.7% of surgical operations in a tertiary care hospital.¹ Patients presenting with painless scrotal or testicular masses, therefore, require diagnostic imaging to obtain information that may not be ascertained from clinical examination alone.² Most frequent conditions causing

painless scrotal masses include hydrocele, spermatocele, epididymal cyst, and malignant or benign tumors including metastasis.^{3,4} Even among these, conditions mimic each other. Cystic lymphangioma is a congenital lymphatic malformation and a rare cause of extra testicular mass in children needs to differentiate from hydrocele.⁵ Chlamydia trachomatis, an infectious disease of scrotum may represent as painless scrotal mass in young adult and can be mistaken for a testicular cancer.⁶ Ultrasound (U/S) with high frequency transducer (7.5- 11 MHz) has become the modality of choice for examination of scrotum.⁷ Ultrasonography permits assessment of testicular and extra-testicular masses with high sensitivity and can differentiate a variety of conditions involving the scrotum, testicles, and epididymis with similar clinical manifestations.⁸ Ultrasound in conjunction with color flow mapping and pulsed spectral Doppler techniques has supplanted other imaging modalities in evaluating scrotal diseases.⁹

Ultrasound is useful tool to differentiate extra testicular lesions, which are mostly benign from intra testicular lesions, which are mostly malignant.¹⁰ It can also differentiate cystic lesion from solid or complex lesions for management purpose.

Most of the available local data on scrotal imaging pertains to the painful scrotum, or the general gray scale and Doppler findings of the scrotal disorders. The painless scrotal mass, as a distinct clinical presentation in adults, has not been studied. The rationale of this study was to obtain data regarding ultrasound finding of painless scrotal masses and finding the accuracy of gray scale and Doppler ultrasound in this particular regard. This noninvasive and widely available diagnostic technique can help in early diagnosis and prompt management.

The objective of this study was to determine the role of gray scale and Doppler Ultrasound in the diagnosis of painless scrotal masses taking histopathology as gold standard for tumors and surgical findings for the benign tumors.

METHODOLOGY

It was a descriptive study conducted at the Radiology department of Civil Hospital Karachi and Dow University of Health Sciences from June 2006 to June 2007. Patients included after informed verbal consent were those above 10 years of age, with painless scrotal mass referred to Radiology Department Civil Hospital Karachi for Ultrasound evaluation and whose follow up was available later. Exclusion criteria were patients with provisional diagnosis of inguino-scrotal swelling (practically synonymous with hernia) and follow up cases of already diagnosed scrotal masses.

The studied variables included patients' demographics, ultrasound findings and histopathology/ surgical findings. Ultrasound findings included the exact anatomical location, shape, size and echogenic characteristics of the lesion on gray scale ultrasound and the vascularity patterns on color and spectral Doppler ultrasound. All subjects were scanned on NEMIO 17 Color Doppler scanner equipped with 11 MHz biconvex and linear transducers. Patients were first scanned in supine position. The scrotal contents were elevated by folded towel positioned between the patients' legs. Penis was positioned over the supra pubic region draped with second towel. Some patients were later scanned in erect posture as per need. Serial transverse and sagittal images of both testes and epididymis were taken for comparison of testicular size, echogenicity and echo texture. Doppler ultrasound was done to assess and document the blood flow and spectrum, in the epididymis, as well as in the lesion. SPSS version 14 was used to analyze data. Mean and standard deviation were calculated for the age of patients. Frequency and percentages will be calculated for age groups and sonographic scrotal abnormalities. Sensitivity and positive predictive value were computed for gray scale and Doppler findings. Histopathology was the gold standard for tumors. For the benign conditions, concordance with surgical findings was sought.

RESULTS

A total of 70 patients with painless scrotal mass were included in this study. The average age of the patients was 38.51 ± 9.4 years. Maximum age of the patients was 75 years and minimum age was 11 years. Age distribution of different pathologies is given in Table-I.

The most common scrotal mass was hydrocele observed in 24 (34.29%) patients followed by varicocele in 13 (18.57%) patients, testicular tumors in 12 (17.14%), spermatocele in 11 (15.71%) and epididymal cyst observed in 10 (14.29%) patients (Table-I).

Out of the 24 hydrocele cases, 11 (45.83%) were right sided, 07(29.16%) were left sided and 06(25%) were bilateral. In about 30% cases, assessment of testis by clinical methods was equivocal and required ultrasound differentiation from testicular tumors. One case of renal carcinoma was detected leading to hydrocele. The mass was invading the left renal vein whereas the testes were normal.

Out of the 13 varicocele cases, 10 (76.92%) were left sided, 01 (7.6%) was right sided and 02 (15.38%) were bilateral. Grey-scale sonography showed epididymis, testes and overlying skin to be normal while varicocele was seen serpiginous anechoic tubular channels in the peri-testicular tissue with more than 2 mm diameter. They were located lateral, superior and/ or posterior to the testis. During the Valsalva maneuver, these enlarged by more than 0.5 mm in diameter and the incompetent valve in the testicular vein allowed rapid retrograde flow into the pampiniform plexus.

Of the eleven out of 70 cases of spermatocele, 6(54.54%) were found on the right side and five(45.45%) were found on the left side. Lesion was seen in the head of epididymis as well defined anechoic mass with some internal low level echoes generated by spermatic debris (Fig-1). Out of 10 cases of epididymal cyst, six (60%) were right sided and 04 were left sided (40%). Epididymal cysts were asymptomatic, varying in size, most commonly seen in the head of epididymis but also in the body and tail. They contained anechoic fluid only.

Twelve cases were of testicular tumors in which 07 cases involved right hemi-scrotum (58.3%) and 05 cases involved left side (41.7%). Age ranged from 13 to 45 years. There were 05 cases of seminoma (41.7%) with 03 cases seen in un-descended testis and 02 involving the normally descended testes (Fig-2). Embryonal cell carcinomas were detected in 02 (16.7%) patients. Two cases were of epidermoid cyst (16.7%) and 01 (8.3%) case each of teratoma, choriocarcinoma with metastasis and testicular lymphoma. In 08 cases clinical diagnosis based on history, physical examination and testicular tumor marker levels in serum was that of testicular tumors confirmed on ultrasound and then by histopathology. In the rest the diagnosis was suggestive but confirmed on histopathology only. Sensitivity and positive predictive value of the gray scale and Doppler Ultrasound were 66.7% and 100%. All the benign lesions diagnosed on ultrasound were in concordance with surgical findings giving 100% agreement between the sonographic diagnosis and the surgical pathology.

Table-I: Scrotal abnormalities according to age and side (n=70)

Scrotal Abnormalities	N(70)	Age Categories (Years)						sidedness		
		11-20	21-30	31-40	41-50	51-60	>60	right	left	bilateral
Hydrocele	24	2	2	5	4	7	4	11(45.83%)	7(29.16%)	6(25%)
Varicocele	13	1	2	5	5	0	0	1(7.6%)	10(76.92%)	2(15.38%)
Spermatocele	11	0	5	6	0	0	0	6(54.54%)	5(45.45%)	0(0%)
Epididymal cyst	10	1	4	5	0	0	0	6(60%)	4(40%)	0(0%)
Testicular tumor	12	1	2	4	5	0	0	7(58.3%)	5(41.7%)	0(0%)

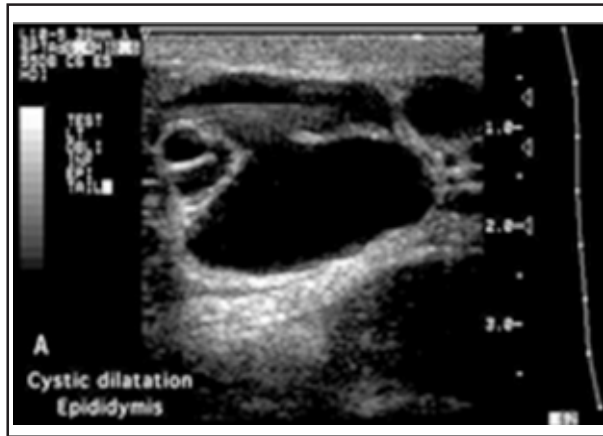


Fig-1: Septate epididymal head cyst.

DISCUSSION

The primary reason for scanning a patient with painless scrotal mass is to determine if the mass is a testicular tumor.¹¹

However scrotal ultrasound is limited in determining whether a focal testicular lesion is benign or malignant.¹² The limitation of gray scale ultrasound in the assessment of blood flow in the lesions has now been overcome by color coded duplex sonography (CDUS) and power Doppler.¹² CDUS demonstrates testicular perfusion which aid to reach the specific diagnosis.¹³ Most extra-testicular masses are benign and only rarely malignant whereas intra-testicular masses must be considered malignant and unless proven otherwise.⁴ The varicocele, hydrocele, spermatocele, epididymal cyst and inguinal hernia are the commonly encountered extra-testicular masses which explains why most extra-testicular masses are benign regardless of age.

Twenty four cases of hydrocele were found in this study out of 70 patients making about 34.29% of cases which is the major proportion. At an incidence of 1% in adult male population, hydrocele is considered to be the most common cause of painless scrotal swelling as found in this study. Majority of hydrocele are asymptomatic or subclinical. About 7 to 10% of hydrocele may be bilateral. Majority are right sided as seen in this study. Secondary hydrocele are usually seen in the males over 40 years in age.¹⁴

There were 13 cases of varicocele (18.57%)



Fig-2: Testicular tumor. Longitudinal CDS image of the lower half of the testis shows a hypoechoic poorly marginated hyper vascular mass.

with preponderance of left sided involvement as reported previously. Gray scale ultrasound aided by color Doppler correctly diagnosed all cases. Most of these were inconclusive clinically therefore ultrasound in conjunction with color Doppler proved its value in detection of clinically inconclusive varicocele. In most cases decreased echogenicity and altered texture of the affected testis was observed. Preuthipan and Niculus also performed a comparative study between scrotal clinical examination and sonographic findings in detection of varicocele in infertile men with similar results.¹⁵

In this study 12 cases of testicular tumors were found in total 70 patients so that seminoma was 42% of all testicular tumors all had painless scrotal masses with disruption of echo texture of testis. The testicular tumors are otherwise an uncommon entity as the reported frequency is about 1 to 2 %.^{14,15} Data from Pakistan suggest a prevalence of 1.8-4.2%.² One study has reported that testicular tumors comprise 3.8% of all malignancy in Pakistan.¹⁶ The proportion of tumors was 17.14 % in this study which is higher due to the main selection criteria i.e. the painless mass. Again seminoma was the commonest tumor which is a well known fact.¹⁸ Most patients in this study were below 45 years of age confirming the age incidence of testicular tumors in between 15 and 35 years.¹⁹ Gray scale Ultrasonography is extremely sensitive in describ-

ing scrotal masses but unable to distinguish malignant lesions from benign so it is helpful for identifying the location of lesion but not the nature of lesions unless characteristic cystic, calcified or fatty densities are seen.²⁰

Addition of Doppler gives added information about the vascularity which then provides valuable information about the intrinsically vascular lesions such as varicoceles and the tumoral neovascularity. This was the main reason behind the increased sensitivity and positive predictive value of the Doppler ultrasound. Using Doppler ultrasound also differentiates an intratesticular vessel from an intra-testicular hypoechoic mass. So the findings of this study suggest an important role of Doppler in scanning patients with painless scrotal masses. The use of ultrasound in the evaluation of the scrotum benefits from understanding of scrotal anatomy and familiarity with potential pitfalls of color and pulsed Doppler evaluation.

CONCLUSION

Gray scale ultrasound in combination with color Doppler ultrasound is an effective and noninvasive technique of diagnosis in patients presenting with painless scrotal masses. It can detect sub clinical and indeterminate scrotal mass lesions. The performance of detection is better for benign than tumoral masses.

REFERENCES

- 1- Jawaid M, Masood Z, Iqbal SA, Sultan T. The pattern of diseases in surgical unit at a tertiary care public hospital of Karachi. *Pak J Med Sci* 2004;20:311-4.
- 2- Hakim T, Qureshi IA, Qureshi PS, Tarin BA, Nadeem SF, Shah G. Evaluation of scrotal swellings with high resolution grayscale ultrasonography. *J Coll Physicians Surg Pak* 1999;9:311-7.
- 3- Qayyum A, Ilyas M, Adil R. Testicular tumour- an unusual presentation. *Pak Armed Forces Med J* 2005;55:167-69.
- 4- Muttarak M, Chaiwun B. Painless scrotal swelling: ultrasonographic features with pathological correlation. *Singapore Med J* 2005;46:196-201.
- 5- Loberant N, Chernihovski A, Goldfeld M, Sweed Y, Vais M, Tzilman B, et al. Role of Doppler sonography in the diagnosis of cystic lymphangioma of the scrotum. *J Clin Ultrasound* 2002;30:384-7.
- 6- Benilevi D, Madeb R, Glazer O, Mogilner G, Surgo I. Chlamydia trachomatis disguised as an asymptomatic scrotal mass in adolescents. *Pediatr Infect Dis J* 2001;20:722-3.
- 7- Dogra VS, Gottlieb RH, Oka M, Rubens DJ. Sonography of the scrotum. *Radiology* 2003;227:18-36.
- 8- De Cassio SO, De Barros N, Chammass MC, Oliveira IR, Cerri GG. Ultrasound of tropical and infectious diseases that affect the scrotum. *Ultrasound Q* 2004;20:12-8.
- 9- Ragheb D, Higgins JL Jr. Ultrasonography of the scrotum: technique, anatomy, and pathologic entities. *J Ultrasound Med* 2002;21:171-85.
- 10- Woodward PJ, Schwab CM, Sesterhenn IA. From the archives of the AFIP: extratesticular scrotal masses: radiologic-pathologic correlation. *Radiographics* 2003;23:215-40.
- 11- Middleton WD, Kurtz AB, Hertzberg BS. Lower genitourinary. In: *the Requisites; Ultrasound*. 2nd ed. Philadelphia: Mosby 2004;152-75.
- 12- Hamm B. Differential diagnosis of scrotal masses by ultrasound. *Europ J Radiol* 2004;19:668-79.
- 13- Muttarak M, Lojanapiwat B. The painful scrotum: an ultrasonographical approach to diagnosis. *Singapore Med J* 2005;46:352-8.
- 14- Skoog SJ, Colin MJ. Pediatric hernias and hydroceles. *Urologic Clin N Am* 1995;22:119-30.
- 15- Preuthipan S, Ncolas OA. Comparative study between scrotal physical examination and scrotal ultrasonography in the detection of varicocele in men with infertility. *J Med Assoc Thai* 1995;78:135-9.
- 16- Jafarey NA, Zaidi SHM. Cancer in Pakistan. *J Pak Med Assoc* 1987;37:178-83.
- 17- Dodds LJ, Murphy D, Neerhut G, Leggat R. Fifteen years experience of testicular neoplasm in a regional centre. *Aust N Z Surg* 1997;67:857- 9.
- 18- Howelt DC, Marchbank ND, Sallomi DF. Ultrasound of testis. *Clin Radiol* 2000;55:595-601
- 19- Comiters CV, Benson CJ, Capolouto CC et al. Nonpalpable intratesticular masses detected at sonography. *J Urol* 1995;154:1367-9.
- 20- Frates MC, Benson CB, DiSalvo DN, Brown DL, Laing FC, Doublet PM. Solid extratesticular masses evaluated with sonography: pathologic correlation. *Radiology* 1997;204:43-6.

Authors Contribution:

ZAK – data collection literature search statistical analysis and drafting of the manuscript.
SS – Study concept, design, supervision of data and literature search and final write up for publication.