

Original Article

MIDSAGITTAL DIAMETER OF CERVICAL SPINAL CANAL AND TORG'S RATIO OF THE CERVICAL SPINE IN PAKISTANIS

Athar Maqbool¹, Zubia Athar² & Laiq Hussain³

ABSTRACT

Objectives: (1) To determine the midsagittal diameter of cervical spinal canal in normal Pakistani population, (2) to set the normal range of cervical spinal canal/vertebral body ratio (Torg's ratio) in the Pakistanis, and (3) to know whether there are any differences in the cervical spinal canal size and the Torg's ratio of the cervical vertebrae between Pakistani and other populations.

Design: Measurement of midsagittal diameter of the spinal canal and anteroposterior diameter of the vertebral body in cervical vertebrae of 100 dried human spinal columns of Pakistani origin.

Setting: Anatomy department, Nishtar Medical College, Multan, Pakistan.

Results: Mean midsagittal diameter of the cervical spinal canal in Pakistani males was found to be 15.1 ± 1.6 mm, while in the females it was 14.5 ± 2.07 mm. The mean Torg's ratio for the Pakistani males was 0.95 and for the females it was 1.08.

Conclusions: (1) There is no significant difference in the anteroposterior diameter of cervical spinal canal in the American and Pakistani population. (2) Mean midsagittal diameter of cervical spinal canal in normal Pakistanis is larger than that of the normal Japanese. (3) The Torg's ratio in the male Pakistani and Korean subjects is nearly similar but is less than that reported for male Americans. However, the Torg's ratio for the Pakistani, Korean and American females is nearly similar.

KEY WORDS: Cervical spinal canal stenosis, Midsagittal Diameter of cervical spinal canal, Torg's Ratio

Pak J Med Sci July - September 2003 Vol. 19 No. 3 203-210

1. Athar Maqbool M. Phil.
Assistant Professor of Anatomy,
Nishtar Medical College, Multan, Pakistan
2. Zubia Athar M. Phil.
Assistant Professor of Anatomy,
Nishtar Medical College, Multan, Pakistan
3. Laiq Hussain M. Phil.
Professor of Anatomy,
Nishtar Medical College, Multan, Pakistan

Correspondence:

Dr. Laiq Hussain,
E-mail: laiqs@hotmail.com

* Received for publication: March 15, 2003

Accepted: June 3, 2003

INTRODUCTION

Cervical spondylosis is an age-related abnormality of the cervical spine affecting the vertebral bodies and the intervertebral discs. Changes are most common in the lower segments of the cervical spine. The intervertebral discs degenerate, flatten and become less elastic. Herniation of the disc material through tears in the annulus fibrosus is commonly associated with these changes. Osteophytes in the form of bony spurs, ridges or bars appear at the anterior and posterior margins of the vertebral bodies; those that develop posteriorly may encroach upon the spinal canal or the intervertebral foramina¹. Cervical spondylosis

is the commonest abnormality of the cervical spine and it has been reported that 82% of the people aged 54 years or more have radiographic evidence of degenerative changes in the cervical spine².

The importance of size and shape of the spinal canal in connection with the occurrence of symptoms of spinal cord or nerve root compression has long been recognized. While Elsberg and Dyke³ determined the range of variation in the interpeduncular width of the cervical spinal canal, it was Lindgren⁴ who first pointed out the importance of anteroposterior (sagittal) diameter in the cervical region. Payne and Spillane⁵ measured the anteroposterior diameter of the cervical spinal canal of 90 adults on the lateral radiographs of the cervical spine. They found that the spinal canal was narrower in cases of cervical spondylosis. Wolf et al⁶ measured the canals of 200 random cases and established the currently accepted normal values for the sagittal diameter of the cervical spinal canal from C1 to C7. Burrows⁷ measured the sagittal diameter of the cervical canal upon lateral radiographs of 300 normal adults and compared this standard with the sizes of the spinal canals of 24 patients of cervical spondylosis on whom cervical laminectomy was performed because of severity of their symptoms. He concluded that the sagittal diameter of the spinal canal is of definite diagnostic significance in cervical spondylosis. Similar findings were also reported by Hinck and Sachdev⁸.

Later on, other workers reported that many young athletes giving history of neurapraxia of the cervical spinal cord were found to have developmental narrowing (stenosis) of the cervical spinal canal⁹⁻¹¹.

More recently, many workers have produced evidence that incidence of "stingers" or "burners" (traumatic upper extremity paresthesias) in athletes is associated with developmental spinal stenosis¹²⁻¹⁵.

It is a known fact that the vertebral column morphology is influenced externally by mechanical and environmental factors and internally by genetic, metabolic and hormonal

factors¹⁶. Different authors have reported different measurements of the normal range of the anteroposterior diameter of the spinal canal at each cervical level^{5-7,17,18}. These measurements, obtained from lateral radiographs of the cervical spine show certain amount of discrepancy. As pointed out by Boijesen¹⁷, these discrepancies are due to variable enlargement factors, mainly the object-film distance which depends upon individual shoulder widths. To overcome this difficulty Torg, Pavlov and co-workers¹⁹ devised a ratio method to determine cervical spinal stenosis. This ratio (titled since then as Torg's ratio or Pavlov's ratio) compares the sagittal diameter of the spinal canal with the anteroposterior width of the vertebral body. Pavlov et al²⁰ reported that the ratio method for determining cervical spinal stenosis is more sensitive and more specific than the conventional method in which only the sagittal diameter of the spinal canal is measured.

Lee et al²¹ suggested that measurements on the radiographic films could not depict the exact and true dimensions of the vertebral body and spinal canal and, therefore, a study on anatomical specimens was indicated. They carried out their study on dried human spinal columns. Purposes of their study were to determine the normal midsagittal diameter of the cervical spinal canal of the Korean population by actual measurements on anatomical specimens, to set the normal range of Torg's ratio in Koreans, and to find out whether these measurements were subject to any racial differences.

The present study was carried out on dried human spinal columns with the following objectives:

1. to determine the midsagittal diameter of the cervical spinal canal in the normal Pakistani population.
2. to set the normal range of the Torg's ratio for the cervical spinal canal in the Pakistanis.
3. to know whether there are any differences in the cervical spinal canal size and the Torg's ratio of the cervical vertebrae between Pakistani and other populations.

MATERIALS AND METHODS

The cervical vertebrae of 100 dried human spinal columns stored in the department of Anatomy, Nishtar Medical College, Multan, were studied. Seventy five of these spinal columns were of male subjects, while the rest 25 belonged to female subjects. All subjects were adults, the age limit ranging between 25 and 60 years. Any spinal column showing osteophyte formation or any other vertebral abnormality was not included in this study. The vertebral levels examined included C3 to C7. The first and second cervical vertebrae were excluded as they have different shape as compared with other cervical vertebrae and, also because most cases of cervical spinal stenosis occur at the levels between C4 and C6²¹. Following two measurements were made in each vertebra included in this study: (Fig. 1)

1. midsagittal diameter of the spinal canal (i.e., vertebral foramen).
2. anteroposterior diameter of vertebral body at the midwaist level

Measurements were carried out by means of sliding Vernier calipers (Peacock Co., Tokyo, Japan). The accuracy was 0.1 mm. For consistency, all measurements were taken by one worker.

The Torg's ratio for each vertebra was calculated by dividing the midsagittal diameter of the spinal canal by the anteroposterior diameter of vertebral body as described by Torg et al¹⁹.

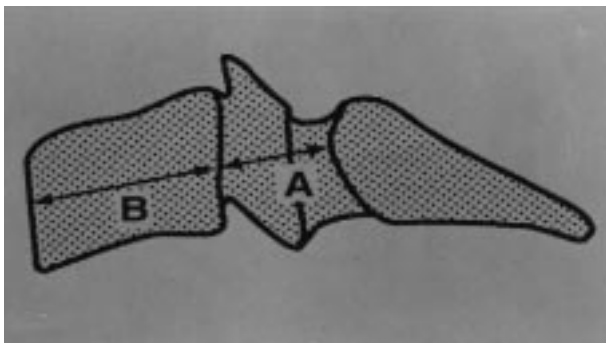


Fig. 1: The midsagittal diameter of the cervical spinal canal (A), & anteroposterior diameter of the vertebral body (B).

RESULTS

Midsagittal Diameter of the Cervical Spinal Canal

The results of measurement of the midsagittal diameter of the cervical spinal canal (from C3 to C7) both in males and females are presented in Table-I. The mean values and standard deviations have been calculated for both sexes. In males the mean midsagittal diameter at C4 level was less than that recorded for C3 level. However, below C4 level the diameter steadily increased upto the C7 level. In the females the midsagittal diameter of the cervical spinal canal became narrow at C4 level but widened again at C5 level. However, at C6 level the diameter again decreased slightly and then increased again at C7 level (Fig. 2).

Cervical Spinal Canal/Vertebral Body Ratio

Measurements of the midsagittal diameter of the cervical spinal canal and anteroposterior diameter of the vertebral body at different vertebral levels (from C3 to C7) for both sexes have been given in Table-II. The spinal canal/vertebral body ratio for each vertebral level has also been calculated. In the male the mean midsagittal canal diameter from C3 through C7 was 15.1 mm, while the mean anteroposterior diameter of the vertebral body was found to be 15.9 mm. In the female the mean canal diameter was 14.5 mm, while the mean diameter of the body was found to be 13.5 mm. In the male

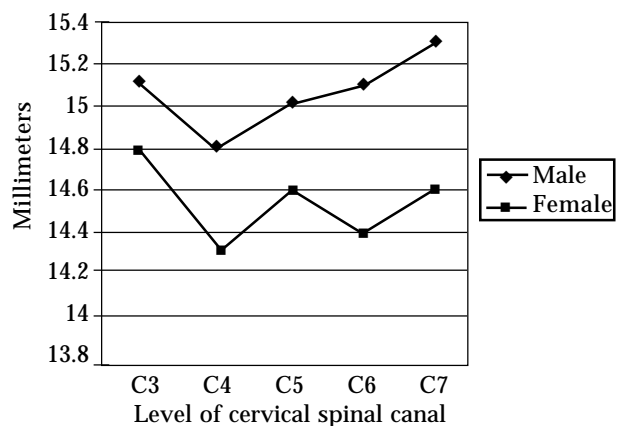


Fig. 2: Mean midsagittal diameter of the cervical spinal canal from C3 to C7 in male and female Pakistanis.

the mean canal/body ratio was 0.94, whereas in the female this ratio was 1.08.

Comparison with other Populations

In order to correlate the mean midsagittal diameter of the cervical spinal canal in

TABLE-I
Midsagittal diameter of cervical spinal canal in Pakistanis

Level	Male (mm)	Female (mm)
C3	15.1±1.2	14.8±2.1
C4	14.8±1.7	14.3±2.07
C5	15.0±1.8	14.6±2.09
C6	15.1±1.6	14.4±2.1
C7	15.3±1.6	14.6±2.06
Mean	15.1±1.6	14.5±2.07

Mean± standard deviation

TABLE-II
Mean midsagittal diameter of cervical spinal canal, mean anteroposterior diameter of vertebral bodies and canal/body ratio in male and female Pakistanis

Level	Male			Female		
	Canal (mm)	Body (mm)	Canal/Body Ratio	Canal (mm)	Body (mm)	Canal/Body Ratio
C3	15.1	16.0	0.94	14.8	13.9	1.06
C4	14.8	15.6	0.94	14.3	13.1	1.09
C5	15.0	15.8	0.94	14.6	13.3	1.09
C6	15.1	15.8	0.95	14.4	13.3	1.08
C7	15.3	16.1	0.96	14.6	13.6	1.07
Mean	15.1	15.9	0.95	14.5	13.4	1.08

TABLE-III
Midsagittal diameter of cervical spinal canal in American White & Negro (Francis, 1955)

Level	White		Negro	
	Male (mm)	Female (mm)	Male (mm)	Female (mm)
C3	16.5	15.5	15.2	15.1
C4	15.4	14.8	14.8	14.5
C5	15.4	14.4	15.1	14.6
C6	15.4	14.1	15.2	14.4
C7	15.5	14.4	15.5	14.3
Mean	15.6	14.6	15.2	14.6

Pakistani population with that of some other populations of the world, we compared our results with those which have been reported by other workers (Table-III, IV, V and VI).

Previously the workers considered that the measurement of the midsagittal diameter of the

TABLE-IV
Midsagittal diameter of cervical spinal canal in the Japanese

Level	Male (mm)	Female (mm)
C3	13.8	13.6
C4	13.3	12.9
C5	13.5	13.2
C6	13.9	13.5
C7	13.7	13.6
Mean	13.6	13.4

TABLE-V
Midsagittal diameter of cervical spinal canal in the Japanese (male and female combined) (Koyanagi et al. 2000)

Level	Diameter (mm)
C3	13.4
C4	12.8
C5	13.2
C6	13.4
C7	13.6
Mean	13.3

TABLE-VI
Midsagittal diameter of cervical spinal canal in Koreans

Level	Male (mm)	Female (mm)
C3	13.3	13.3
C4	12.8	12.9
C5	13.0	13.0
C6	13.2	12.9
C7	13.4	13.3
Mean	13.1	13.1

spinal canal was the only way to determine the adequateness of size or narrowing of the spinal canal. Lee et al²¹ were the first to calculate the cervical spinal canal/vertebral body ratio from dried bony specimens upon the basis of the ratio method devised by Torg et al¹⁹ for radiographic examination of the cervical spine. The canal/vertebral body ratios obtained in our study have been compared with those reported by Lee et al²¹ for Korean population (Table-VI).

DISCUSSION

Developmental stenosis of the cervical spinal canal is a neurologically significant anomaly which is more common than has been realized. Individuals with this anomaly tend to remain asymptomatic until the development of a complicating feature such as a spondylotic osteophyte or a herniated intervertebral disc. In athletes with developmentally narrow cervical canal the spinal cord can, on forced hyperextension or hyperflexion, be compressed causing transitory motor and sensory manifestations.

Several authors have reported that measurement of the sagittal diameter of the cervical canal in plain lateral radiography is a useful method for detecting cervical spinal stenosis^{6,8,22-24}. However, comparison of data published by different authors reveals that the range of variation in the reported sagittal diameter is considerable. Boijesen¹⁷ has pointed out that this diversity is due partly to the variation in the radiographic technique (focus-to-film distance), and partly to variation in the body build of subjects (affecting the object-to-film distance). In an attempt to find a solution to these discrepancies, Torg et al¹⁹ devised a "ratio method" that compares the sagittal diameter of the spinal canal with the anteroposterior width of the vertebral body (both of which are equally affected by radiological magnification factors). This ratio is obtained by dividing the midsagittal diameter (in mm) of the cervical spinal canal (at any particular cervical segment) by midsagittal diameter

(in mm) of the corresponding vertebral body. Torg et al¹⁹ have reported that, using the ratio method, a measurement of less than 0.80 indicated significant spinal stenosis. Usefulness of Torg's ratio in the diagnosis of cervical spinal canal stenosis has also been confirmed by several other workers^{20,25-31}.

Different researchers working in various parts of the world have been attempting to determine the mean anteroposterior diameter of the cervical spinal canal at different vertebral levels in normal subjects, so that the clinicians may be able to diagnose cervical spinal stenosis by consulting these reference values. These workers have employed different methods of investigation like plain radiography^{5,19,20,29,32}, CT scanning, MR imaging³³ on living subjects or cadavers, while still others have carried out actual measurements on dried bony specimens^{21,34,35}. Table-III shows the results obtained by Francis³⁴ by actual measurements on dried sets of cervical vertebrae belonging to White and Negro specimens. He found that there were no significant differences between the sizes of the vertebrae in the White and Negro males. He also reported that the vertebrae belonging to female subjects were smaller than those of the male subjects but no evidence of racial difference was found between the female White and Negro subjects. Analysis of the figures reported by Francis³⁴ reveals that the mean anteroposterior diameter for the males is 15.5 mm, while that for the females is 14.3 mm. Our study (Table-I) reveals that the mean midsagittal diameter of the cervical spinal canal in Pakistani males is 15.1 mm while that for the females is 14.5 mm. Comparison of our figures with those of Francis shows that there is no significant difference in the anteroposterior diameter of the cervical spinal canal in the American and Pakistani population. Working on lateral radiographs of the cervical spine Payne and Spillane⁵ have reported the normal mean midsagittal diameter of the cervical spinal canal (from C3 to C7 segments) in British population is 18.0 mm for males and 17.2 mm for females. These figures are much bigger than those obtained by

Francis³⁴ and by us. The probable reason for this discrepancy is magnification of the spinal canal dimensions due to the radiographic technique employed by these workers.

Many Japanese research workers have also carried out studies to determine the normal midsagittal diameter of the cervical spinal canal in Japanese people. Murone³⁶ measured the anteroposterior diameter of the cervical spinal canal in a group of 20 adult Japanese men with normal cervical spine. The mean midsagittal diameter of the cervical spinal canal from C3 to C7 segment as reported by him is 15.7 mm. Later, Hashimoto and Tak³² also determined the sagittal diameter of the cervical spinal canal on routine lateral radiograms in 92 healthy Japanese adults (48 men and 44 women). The results of Hashimoto and Tak³² are presented in Table-IV. Comparison of results of Murone³⁶ and Hashimoto reveals that the figures reported by Murone are much larger than reported by Hashimoto and Tak. Very recently Koyanagi et al³³ have measured the mean sagittal diameter of cervical spinal canal in 42 normal Japanese subjects (35 men and 7 women) by carrying out plain radiography as well as CT scanning and MR imaging of the cervical spine. Results of Koyanagi et al³³ are presented in Table-V. These results are in corroboration with those of Hashimoto and Tak³². It appears that the larger figures for the cervical spinal canal diameter as reported by Murone are erroneous and are affected by magnification factors due to the radiographic procedure employed by this worker. A comparison of our results with those of Hashimoto and Tak³² and Koyanagi et al³³ shows that the mean midsagittal diameter of cervical spinal canal in the normal Pakistanis is larger than that of the normal Japanese.

Lee et al²¹ performed studies on 90 dried human spinal columns of Korean subjects comprising 63 men and 27 women. The midsagittal diameter of cervical spinal canal in Koreans, as determined by these workers, is presented in Table-VI. A comparison of our results with those of Lee et al²¹ reveals that the midsagittal diameter of cervical spinal canal

of Pakistanis is larger than that of Koreans.

The fact that the Pakistanis have a larger midsagittal cervical spinal canal diameter than Koreans and Japanese appears to have a racial basis. These results indicate that the Mongoloid race has a smaller cervical spinal canal than the Caucasian race to which most of the Pakistanis belong. This inference is further confirmed by comparison of our results with those of Francis³⁴.

As already mentioned, our work shows that the midsagittal diameter of cervical spinal canal of Pakistanis is nearly similar to that of American Whites who also belong to the Caucasian race. However, here it is worth mentioning that the similarity in the midsagittal diameter of cervical spinal canal of the American Whites and Negroes, as reported by Francis³⁴, is rather surprising because these two samples belong to different races.

Torg's Ratio

Torg's ratio has been found to be of great value in diagnosing cervical spinal stenosis because it is independent of magnification factors caused by differences in target distance, object-to-film distance, or body type, because the midsagittal diameter of the spinal canal and that of the vertebral body are in the same anatomic plane and are similarly affected by magnification. Torg et al¹⁹ and Pavlov et al²⁰ have reported that in American subjects studied by them there is normally a one-to-one relationship between the sagittal diameter of the spinal canal and that of the vertebral body (i.e., Torg's ratio = 1.00), regardless of the sex of the individual under examination. A Torg's ratio of less than 0.80 indicates significant cervical spinal stenosis. These findings have also been confirmed by several research workers²⁵⁻³¹.

In our study the average Torg's ratio for the males was found to be 0.95 and that for the females was determined to be 1.08 (Table-II). These results indicate that the Torg's ratio for the normal male Pakistanis is less than that of normal American males, while the Torg's ratio for the Pakistani female is similar to

American female. However, our results corroborate with those of Lee et al²¹ who have reported that in normal Korean population the average Torg's ratio was found to be 0.93 for males and 1.02 for females.

It is concluded that the actual measurements of midsagittal diameter of the cervical spinal canal in Pakistanis are nearly similar to those of the American population but are significantly larger than those of Japanese and Korean population. The Torg's ratio in the male Pakistani and Korean subjects is nearly similar but is less than that reported for male Americans. However, the Torg's ratio for the Pakistani, Korean and American females is nearly similar.

REFERENCES

1. Solomon L, Warwick D, Nayagam S. Apley's System of Orthopaedics and Fractures. 8th Ed. Arnold, London, pp 363, 2001.
2. Jones ET, Mayer P. Turek's Orthopaedics, Principles and Their Application, 5th Ed. J.B. Lippincott Company Philadelphia. pp 345-6, 1994.
3. Elsberg CA, Dyke CG. The diagnosis and localization of tumors of the spinal cord by means of measurements made on the X-ray films of the vertebrae and the correlation of clinical and X-ray findings. Bull Neurol Inst New York 1934; 3: 359-394.
4. Lindgren E. The importance of the sagittal diameter of the spinal canal in the cervical region. Nervenartz 1937; 10: 240-252.
5. Payne EE, Spillane JD. The cervical spine: an anatomico-pathological study of 70 specimens (using a special technique) with particular reference to the problem of cervical spondylosis. Brain 1957; 80: 571-596.
6. Wolf BS, Khilani M, Malis L. The sagittal diameter of the bony cervical canal and its significance in cervical spondylosis. J Mount Sinai Hosp 1956; 23: 283-292.
7. Burrows EH. The sagittal diameter of the spinal canal in cervical spondylosis. Clin Radiol 1963; 14: 77-86.
8. Hinck VC, Sachdev NS. Developmental stenosis of the cervical spinal canal. Brain 1966; 89: 27-36.
9. Funk FJ Jr, Wells RE. Injuries of the cervical spine in football. Clin, Orthop 1975; 109: 50-8.
10. Grant TT, Puffer J. Cervical stenosis: a developmental anomaly with quadriplegia during football. Am J Sports Med 1976; 4: 219-221.
11. Stratford J. Congenital cervical spinal stenosis: a factor in myelopathy. Acta Neurochir 1978; 41: 101-106.
12. Kelly JD IV, Clancy M, Marchetto PA. The relationship of transient upper extremity paresthesias and cervical stenosis. Orthop Trans 1992; 16: 732-738.
13. Meyer SA, Schulte KR, Callaghan JJ, Albright JP, Powell JW, Crowley ET, et al. Cervical spinal stenosis and stingers in collegiate football players. Am J Sports Med 1994; 22: 158-166.
14. Levitz CL, Reilly PJ, Torg JS. The pathomechanics of chronic cervical nerve root neurapraxia: the chronic burner syndrome. Am J Sports Med 1997; 25: 73-6.
15. Kelly JD IV. Brachial plexus injuries: evaluating and treating "burners". J Musculoskel Med 1997; 14(9): 70-80.
16. Williams PL, Bannister LH, Berry MM, Collins P, Dyson, M, Dussek IE et al. Gray's Anatomy, 38th Ed. Churchill Livingstone, Edinburgh. pp 533, 1995.
17. Boijesen E. The cervical spinal canal in intraspinal expansive processes. Acta Radiol 1954; 42: 101-115.
18. Nagashima C. Cervical myelopathy due to developmental stenosis of the cervical spinal canal. Part 1. The sagittal diameter of the spinal canal. Neurol Surg (Tokyo) 1973; 1: 163-171.
19. Torg JS, Pavlov H, Genuario SE, Sennett B, Wisneski, RJ, Rabie BH et al. Neurapraxia of the cervical spinal cord with transient quadriplegia. J Bone Joint Surg 1986; 68-A: 1354-1370.
20. Pavlov, H.; Torg, J.S.; Robie, B. and Jahre C. Cervical spinal stenosis: Determination with vertebral body ratio method. Radiology 1987; 164: 771-775.
21. Lee, H.M.; Kim, N.H.; Kim, H.J. and Chung, I.H. Midsagittal canal diameter and vertebral body/canal ratio of the cervical spine in Koreans. Yonsei Med J 1994; 35(4): 446-452.
22. Hinck VC, Hopkins CE, Savara BS. Sagittal diameter of the cervical spinal canal in children. Radiology 1962; 79: 97-108.
23. Wilkinson HA, Le May ML, Ferris EJ. Roentgenographic correlation in cervical spondylosis. AJR, 1969; 105: 370-374.
24. Moiel RH, Raso E, Waltz TA. Central cord syndrome resulting from congenital narrowing of the cervical spinal canal. J Trauma 1970; 10: 502-510.
25. Linter DM, Knight RQ, Cullen JP. The neurologic sequelae of cervical spine facet injuries, the role of canal diameter. Spine 1993; 18(6): 725-729.
26. Meyer SA, Schulte KR, Callaghan JJ, Albright JP, Powell JW, Crowley ET, et al. Cervical spinal stenosis and stingers in collegiate football players. Am J Sports Med 1994; 22(2): 158-166.
27. Chen IH, Liao KK, Shen WY. Measurement of cervical canal sagittal diameter in Chinese males with cervical spondylotic myelopathy. Chung Hua I Hsueh Tsai Chih (Taipei) 1994; 54(2): 105-110.

28. Kang JD, Figgie MP, Bohlman HH. Sagittal measurements of the cervical spine in subaxial fractures and dislocations. An analysis of two hundred and eighty-eight patients with and without neurological deficits. *J Bone Joint Surg* 1994; 76(11): 1617-1628.
29. Torg JS, Naranja RJ Jr, Pavlov H, Galinat BJ, Warren R, Stine RA. The relationship of developmental narrowing of the cervical spinal canal to reversible and irreversible injury of the cervical spinal cord in football players. *J Bone Joint Surg Am.* 1996; 78(9): 1308-1314.
30. Torg JS, Corcoran TA, Thibault LE, Pavlov H, Sennett, BJ, Naranja RT Jr et al. Cervical cord neurapraxia: classification, pathomechanics, morbidity, and management guidelines. *J Neurosurg* 1997; 87(6): 843-850.
31. Kelly JD, Aliquo D, Sitler MR, Odgers C, Moyer RA. Association of burners with cervical canal and foraminal stenosis. *Am J Sports Med* 2000; 28(2): 214-217.
32. Hashimoto I, Tak YK. The true sagittal diameter of the cervical spinal canal and its diagnostic significance in cervical myelopathy. *J Neurosurg* 1977; 47(6): 912-916.
33. Koyanagi I, Iwasaki Y, Hida K, Akino M, Imamura H, Abe H. Acute cervical cord injury without fracture or dislocation of the spinal column. *J Neurosurg (Spine 1)* 2000; 93: 15-20.
34. Francis CC. Dimensions of the cervical vertebrae. *Anat Rec* 1955; 122: 603-609.
35. Senol U, Cubuk M, Sindel M, Yildirim F, Yilmaz S, Ozkaynak C, et al. Anteroposterior diameter of the vertebral canal in cervical region: comparison of anatomical, computed tomographic, and plain film measurements. *Clin Anat* 2001; 14(1): 15-8.
36. Murone I. The importance of the sagittal diameters of the cervical spinal canal in relation to spondylosis and myelopathy. *J Bone Joint Surg* 1974; 56-B: 30-36.