Correspondence

AMNIOTIC BANDS

I am presenting the rare pictures possibly of amniotic band seen after the delivery of placenta. The patient was a multipara who presented in third trimester to maternal day assessment unit with the complaint of fall over her abdomen in third trimester. She had a normal 20 week anomaly scan. After this event a thin line was picked up on ultrasound scan possibly raising the suspicion of amniotic band. However this patient was discharged home later as CTG ,fetal movements and other scan findings were normal . She had a spontaneous labour at term and she delivered a healthy normal baby without any fetal abnormalities. In figure-I a very thick band of amniotic band (black arrow) can be seen. In figure 1 (red arrow) and in figure 2 (Blue arrow) shows a sheet of amniotic membranes ''glued together'' toward the fetal side of cord. Placenta was complete and normal.

Amniotic bands are rare, affecting 1 in 1200 (0.08%) of all pregnancies[1] and there are very few case reports available in the English literature. Amniotic bands are fibrous strands of membrane stretching from the outer membrane surface into the amniotic cavity. There are different theories but according to Torpin et al , the primary event could be a rupture of the amniotic membrane and its detachment from the chorion with amniotic fluid leaking through the tear. As a result, the fetus can move digits or limbs through this tear and exit the amniotic cavity

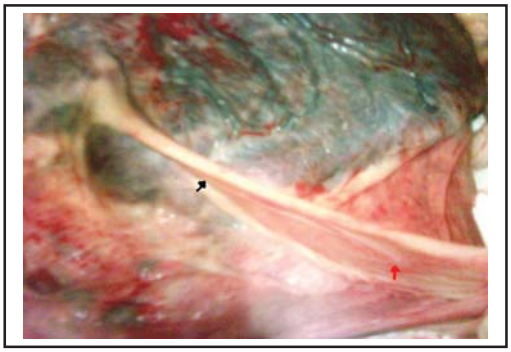

Fig 1: Amniotic band (black arrow); Fused membranes (red arrow)

Fig-2 : Thick fused / ''glued membranes'' toward fetal side (Blue arrow)

(partially or completely). The outer surface of the amnion, and to a lesser degree the naked chorion, produce mesodermic fibrous strings which may entangle and entrap different fetal organs, leading to constriction and amputation anomalies.[1]

On ultrasound the bands appear as thin, mobile lines, which may be seen attached to or around the baby. About 70% of amniotic bands disappear on follow-up ultrasound, presumably due to rupture or compression. Secondly if there is no evidence of any abnormality, other than the amniotic band, at the time of the scan then there appears to be little risk to the baby. Other reassuring factors are normal fetal movement and the band not being attached to the baby. In this case they are called 'innocent amniotic bands.[2] This explanation is consistent with the findings of our case where in spite of thick amniotic band neither there were any fetal deformities nor any complaints of decreased fetal movements .Fetal movements can be decreased if fetal parts are badly entangled in amniotic bands. These bands may constrict the base of the cord at the placental attachment which can be lethal.

Dr. Junaid Rafi
Registrar Obstetrics and Gynaecology
Scarborough General Hospital, Woodlands Drive,Scarborough
North Yorkshire.YO12 6QL,UK
E-mail: drjunaidrafi@hotmail.com

REFERENCES

1. Torpin R. Amniochorionic mesoblastic fibrous strings and amniotic bands:associated constricting fetal malformations or fetal death. Am J Obstet Gynecol. 1965 Jan 1;91:65-75
2: Women,s Health . Available online at http://www.womens-health.co.uk/amniotic.asp [Cited dated June ,14 , 2010]