Original Article

MANAGEMENT OF PENETRATING HEART AND ACCOMPANYING LUNG INJURIES

Hasan Ekim[1], Halil Basel[2], Dolunay Odabasi[3], Mustafa Tuncer[4], Hasan Ali Gumrukcuoglu[5]

ABSTRACT

Objective: Penetrating heart injury is potentially a life threatening condition due to cardiac tamponade or exsanguinating hemorrhage. The aim of this study was to evaluate victims who were referred to our hospital with penetrating heart and accompanying lung injuries and to review our overall outcome with this type of combined injuries.

Methodology: Twenty patients with combined penetrating heart and lung injuries were operated at Yuzuncu Yil University Research Hospital, between May 1999 and January 2010. The diagnosis of combined heart and lung injuries was proved by surgical exploration in all cases. The surgical procedures mainly included the relief of cardiac tamponade, control of bleeding, repair of cardiac and pulmonary lacerations, and coronary artery bypass grafting if required.

Results: In this series of 20 patients; there were 18 males and two females between the age of 14 to 60 years, with a mean age of 34.8±13.5 years. Seventeen victims sustained stab wounds, and the remaining three were injured by a gunshot wounds. In 20 patients there were 22 cardiac chamber injuries. The most commonly injured cardiac chamber was the right ventricle followed by the left ventricle. In addition to the injuries to heart muscle, injuries to the coronary arteries were found in two patients. The most commonly injured lung lobe was the left upper lobe.

Conclusion: Our experience shows that early diagnosis and immediate surgical intervention are the main factors affecting patient survival after penetrating heart and lung injuries. Therefore, heart injury should always be kept in mind in victims with penetrating thoracic injuries.

KEY WORDS: Cardiac Injury, Penetrating.

Pak J Med Sci July - September 2010 Vol. 26 No. 3 526-531

How to cite this article:

Ekim H, Basel H, Odabasi D, Tuncer M, Gumrukcuoglu HA. Management of penetrating heart and accompanying lung injuries. Pak J Med Sci 2010;26(3):526-531

INTRODUCTION

Penetrating heart injury is potentially a life threatening condition due to cardiac tamponade or exsanguinating hemorrhage.[1,2] This lethal outcome may be also increased by accompanying lung injury. Their management often requires immediate operation and excellent surgical technique.[3]

Cardiac injuries have been well described throughout the times. The first description of a heart injury is found in Homer's poetic description of the death of Sarpedon from the classical Greek epic The Iliad.[4] Other earlier descriptions of penetrating chest wounds can be found in the Edwin Smith Papyrus.[5]

Correspondence:

Dr. Hasan Ekim,
Yuzuncu Yil University,
Tip Fakultesi Hastanesi,
Maras Caddesi 65200 Van,
Turkey
E-Mail: drhasanekim@yahoo.com

* Received for Publication: February 7, 2010

* Accepted: April 8, 2010

The first attempt at repairing a cardiac injury was by Cappelen in 1896. He repaired a laceration of the left ventricle and ligated the distal LAD artery, but the patient died in the immediate postoperative period. The first successful attempt is credited to Rehn in same year that repaired a wound of the right ventricle.[4] From this moment on the era of cardiac surgery began.[3] Hill was the first to successfully repair a stab wound to the left ventricle in 1902. Pool in 1912 also collected additional cases and his own series and fully described surgical techniques in the management of heart injuries concluding that; the treatment of cardiac wounds should be surgical. Beck in 1942 pointed to the necessity of sparing ligation of proximal coronary arteries in wounds adjacent to these structures.[5] Considerable improvement in the management has been made since then, however these injuries are still challenging and demand prompt recognition and urgent operation.[6]

The aim of this study was to document victims who were referred to our hospital with penetrating heart and accompanying lung injuries and to document our overall outcome with this type of combined injuries.

METHODOLOGY

Twenty patients with combined penetrating heart and lung injuries were operated at Yuzuncu Yil University Research Hospital, between May 1999 and January 2010. The majority of patients were referred from surrounding hospitals with suspected cardiac injuries.

The diagnosis of combined heart and lung injuries was proved by surgical exploration in all cases. Since the majority of our patients were emergency cases, and required immediate surgical intervention, usually time consuming preoperative tests were not carried out. In hemodynamicaly relatively stable patients, preoperative diagnosis was established by electrocardiography, echocardiography and chest radiography. We have not used preoperative pericardiocentesis and subxiphoid pericardial window.

The patients were explored through median sternotomy or thoracotomy or both. The surgical procedures mainly included the relief of cardiac tamponade, control of bleeding, repair of cardiac and pulmonary wounds, and coronary artery bypass grafting (CABG) if required.

Repair of ventricular wounds was accomplished with mattress sutures of 3-0 polypropylene tied over Teflon or pericardial pledgets. The first mattress suture was placed in the middle of the wound in larger wounds (Figure-1). Atrial wounds were controlled by placing a finger into the defect. Subsequent repair was accomplished by a mattress suture of 5-0 polypropylene placed in a purse string manner. Larger atrial wounds were controlled by placing a Satinsky clamp. Subsequent repair was accomplished with running 5-0 polypropylene. Injuries in close proximity to a major coronary artery were repaired by means of a horizontal mattress suture under-running the artery. The pericardium was loosely closed with interrupted sutures spaced 1.5 to 2 cm from each other by allowing drainage to the pleural cavity and a posterior pericardial window was created to prevent postoperative tamponade. The patients were taken to the cardiac intensive care unit postoperatively. All survivors had a two-dimensional echocardiography before discharge and at follow-up two months after discharge.

RESULTS

In this series of 20 patients; there were 18 males and two females between the age of 14 to 60 years, with a mean age of 34.8±13.5 years. Seventeen victims sustained stab wounds, and the remaining three were injured by a gunshot. Two patients received cardiopulmonary resuscitation (including endothracheal intubation) during transport. Vital signs were detectable on arrival to the emergency room. Penetrating wounds on the body surface were situated on the left hemithorax in 14 patients, on the right hemithorax in three patients, and bilateral in three patients. Additionally, two patients had associated upper abdominal wounds.

Sixteen patients had an initial systolic blood pressure of less than 70 mmHg. These Hemodynamically unstable patients were taken to the operating room immediately without performing time-consuming procedures. Only electrocardiogram was obtained in the operating room in these patients and was helpful in one patient with left anterior descending artery (LAD) laceration. Besides physical examination, chest radiogram, electrocardiogram and echocardiogram were obtained in the remaining four relatively stable patients. Echocardiographic diagnosis of cardiac tamponade was made in these patients. They were taken to the operating room following tube thoracostomy. In these patients, pericardial tears were sealed by the pericardial fat and the formation of clot. In two of them, the heart wound was sealed by the clot formation as well, which started bleeding during suture repair.

Six patients were operated on by median sternotomy, 10 using left anterolateral thoracotomy, one using right anterolateral thoracotomy, two using both left anterior thoracotomy and median sternotomy, and the remaining one was required left and right anterior thoracotomies. Additionally, laparatomy was performed in two patients due to accompanying liver and spleen injuries, one of whom had splenectomy.

The locations of the cardiac wounds are shown in Table-I. In addition to the injuries to heart muscle, injuries to the coronary arteries were found in two patients. The length of cardiac wounds was 0.4-4 cm (average 2.1). Two patients had also diaphragmatic injuries. Diaphragmatic tears were primarily repaired with non-absorbable sutures. One patient had active bleeding from accompanying axillary artery injury. He was taken to the operating room after insertion of chest tube immediately. Left thoracotomy and left axillary incision were done. The left ventricle and left axillary artery injuries were repaired concomitantly. Then right thoracotomy was performed and injured lung segment was repaired.

Overall, cardiac tamponade was found in 16 patients. In these cases, there was a combination of tamponade and massive extravasation of blood into the affected hemi-thorax. The volume of hemopericardium was 150-450 ml; the average was 300 ml.

In 20 patients there were 22 cardiac chamber injuries. The most commonly injured cardiac chamber was the right ventricle (n=11) followed by the left ventricle (n=6), the right atrium (n=4), and the left atrium (n=1). Two patients had two separate cardiac injuries. In one patient cardiac injury was due to the inward displacement of broken rib fragments produced by bullet. The most commonly injured lung lobe was the left upper lobe (Table-II). All lung wounds were primarily repaired. In 18 patients, heart wounds were repaired without use of cardiopulmonary bypass (CPB). In the remaining two patients, CPB was required. One patient with transection in LAD in its proximal portion necessitated institution of CPB. Left ventricular wound was primarily repaired with mattress sutures reinforced with Teflon pledget. Proximal end of the severed LAD was ligated. A saphenous vein graft was performed between aorta and distal end of the severed LAD. Then, injured left upper lobe was primarily repaired. The remaining one who required CPB sustained cardiac arrest after entubation. A left anterior thoracotomy was performed in the fifth intercostals space immediately. Tamponade was released and cardiac massage was performed. The

Table-I: Locations of the cardiac injuries

Location	*No. of injured cardiac chamber*
Right ventricle	11
left ventricle	6
Right atrium	4
Left atrium	1

Table-II: Location of the pulmonary injuries

Location	*No. of injured pulmonary lobe*
Left upper lobe	13
Left lower lobe	4
Right upper lobe	3
Right lower lobe	2

hemodynamics was improved within few minutes. Additional median sternotomy was also performed immediately and CPB was established. The large left ventricular tear was successfully repaired. The stab wound had transected the second diagonal artery. The coronary bypass to the second diagonal artery was found unnecessary due to its small diameter and it was ligated.

Six complications were noted in our series. Two patients requiring CPB were re-explorated due to excessive bleeding. The most common postoperative complication was lung atelectasis in five patients, one of whom required bronchoscopy. Secondary Parkinsonism was developed in the remaining one patient.

We lost two patients, of whom one died during the operation as a result of exsanguination because of deep pulmonary injury and multiple cardiac chamber involvement. The remaining one died after 10 days due to associated abdominal injury rather than cardiac injury.

DISCUSSION

Cardiac injuries remain among the most challenging of all injuries in the field of trauma surgery.[3] Surgical exploration is highly advisable for any precordial wound with opened pleura, even in the absence of positive signs of heart injury.[7] Ultrasonography can be performed while resuscitation is ongoing, for the detection of tamponade, hemothorax and hemoperitoneum.[8] The most important tool in the rapid evaluation of cardiac injury is echocardiography or cardiac ultrasonography.[9] Even if the thoracic stab wound does not seem to be in close proximity to the heart, echocardiography must be performed to investigate heart injury since it determines the involvement of the cardiac structures as well as the success of the surgical intervention.[10]

In patients without hemopneumothorax, echocardiography is an acceptable diagnostic option for heart wound injuries. But, it has significant limitations identifying heart wounds associated with hemopneumothorax.[3] Some patients presenting with a penetrating heart injury may be completely stable and the diagnosis can be missed.[9] Also, echocardiography rarely may be non-diagnostic due to hemopneumothorax. In these circumstances, increased awareness of the possibility of heart injury may be important.

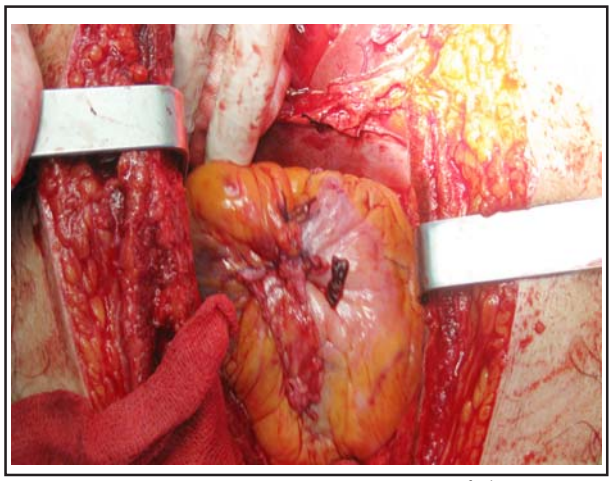

Figure-1: Intraoperative view of the repaired right ventricle.

Heart wounds result in death from cardiac tamponade or exsanguinations and, unlike other forms of trauma, preoperative resuscitation is of limited benefit. Survival therefore depends critically on access to immediate surgical management.[11] Cardiac tamponade has advantages and disadvantages. Initially it may prevent exsanguinations from free bleeding into the thoracic cavity thus providing chance for the victim to reach a cardiothoracic surgery center.[6] This protective effect is limited and time dependent.[12] After this undefined useful period of time, it produces profound shock which proves fatal unless promptly relieved.[5,13] In this condition, widespread reflex compensation mechanisms, peripheral arterial and venous vasoconstriction and prevention of intravascular volume, and increased chronotropism maintain the cardiovascular stability. General anesthesia can inhibate these reflexes and impending cardiac arrest can occur earlier.[14] Therefore, all patients were draped before intubation in this series.

Median sternotomy gives access to the heart and great vessels, to other structures in the mediastinum and to both pleural cavities.[15] Median sternotomy should be preferred except when

there is suspicion of severe coexisting thoracic extracardiac injury or the operation has to be expedited. It facilitates lifting the heart for repair of posterior wall injuries and is the best approach if injuries to mediastinal vessels are encountered.[12] In contrast, some authors advocate routine use of thoracotomy for knife injuries to the heart.[7] Left thoracotomy provides rapid access to the right and left ventricles and to the pulmonary artery. Although thoracotomy is a less satisfactory approach to the right atrium and superior or inferior caval vein and proximal aorta[15], it provides adequate exposure in victims with anterior heart wall injuries. Therefore; in China, surgeons have preferred thoracotomy in victims with anterior heart wall injuries.[7]

Thoracotomy can be extended across the sternum, if more exposure is required. It is important to note that upon transection of the sternum, both internal mammary arteries are sacrificed.[3] The internal mammary artery is the graft of choice for coronary artery bypass surgery. We suggest that internal mammary artery should be saved for possible future use. Therefore, we have avoided extension of the thoracotomy incision toward the other hemithorax (Clamshell incision). Also, additional median sternotomy may be easily performed instead of Clamshell incision, as was done in two of our patients.

Many simple heart wounds can be rapidly managed without CPB. Gentle surgical technique synchronizing with heartbeats is required and rough lifting of the heart should be avoided. However, in some cases, CPB may be life saving as it helps to reverse hypothermia, acidosis, and shock in the early phase while allowing more time to provide adequate exposure and make high quality repairs.[10,16] Additionally, Using CPB, the heart can be emptied and if necessary arrested, greatly optimizing condition for repair.[11]

Coronary artery injury can be treated with either ligation or revascularization. But, ligation of the proximal LAD injury may result in extensive myocardial infarction, which may be fatal or lead to subsequent significant impairment of ventricular function or aneurysm formation.[17] Therefore, in major proximal coronary artery laceration, surgical revascularization should be performed to avoid hemodynamic decompensation and aneurysm formation, as was done in one of our patient. Although recently off pump surgical revascularization has been successfully performed[18], CPB may be required due to accompanying ventricular injury, as seen in one of our case.

Pericardial window drainage is routinely done posterior to the phrenic nerve, and the pericardial incision is closed loosely[7], as was done in this series.

Air embolism may be a complication of a cardiac wound (air tends to be sucked into the low pressure cardiac chambers and in the presence of hypovolemia) or of a pulmonary injury. Often, air bubbles can be seen in the coronary vessels.[19] Therefore, coronary vessels should be carefully observed during the operation to avoid this fatal complication.

The right ventricle, comprising the majority of the anterior surface of the heart, is the most vulnerable chamber to penetrating trauma, whereas the left atrium, being a smaller and almost entirely posterior structure, is the least frequently injured[11], as seen in this series.

The main causes of hemothorax are laceration of the lung, intercostal artery, and internal mammary artery. Due to low-pressure vascular system and rich concentration of tissue thromboplastin in the lungs, any bleeding is usually self-controlled and the vast majority can safely be managed by tube thoracostomy.[20] Therefore, the possibility of accompanying cardiac injury should be kept in mind in patients with excessive or continued chest tube drainage.

The extent of a thoracic stab wound may not always seem to be in close proximity to the heart. It is emphasized that heart injury may result even after right thoracic paravertebral penetration.[10] Therefore, every case with penetrating thoracic injury should be seen as a cardiac injury until proven otherwise.[19] The penetrating tool must never be pulled out but should be stabilized until preoperative cardiac examination and the surgical team must be ready to perform a CPB if required.[10]

CONCLUSION

Our experience shows that, early diagnosis and immediate surgical intervention are the main factors affecting patient survival after penetrating heart and lung injuries. Therefore, heart injury should always be kept in mind in victims with penetrating thoracic and upper abdominal injuries.

REFERENCES

1. Kurimoto Y, Kano H, Yama N, Nara S, Hase M, Asai Y. Out of hospital cardiopulmonary arrest due to penetrating cardiac injury treated by percutaneous cardiopulmonary support in the emergency room: A Case Report Surg Today 2007;37:240-242.
2. Aksoyek A, Tutun U, Babaroglu S, Parlar AI, Ulus AT, Katircioglu SF. Penetrating cardiac injuries. Ulus Travma Acil Cerrahi Derg 2007;13:135-141.
3. Asensio JA, Soto SN, Forno W, Roldan G, Petrone P, Gambaro E, et al. Penetrating cardiac injuries: A complex challenge. Surg Today 2001;31:1041-1053.
4. Asensio JA, Soto SN, Forno W, Roldan G, Petrone P, Salim A, et al. Penetrating cardiac injuries: A complex challenge. Injury 2001;32:533-543.
5. Asensio JA, Petrone P, Karsidag T, Ramos-Kelly R, Demiray S, Roldan G, et al. Penetrating cardiac injuries. Complex injuries and difficult challenges. Ulus Travma Derg 2003;9:1-16.
6. Mardan MAA, Alshaeb A, Haddad OCM, Nafea AMS. Gomal J Med Sci 2008;6:120-123.
7. Gao JM, Gao YH, Wei GB, Liu GL, Tian XY, Hu P, et al. Penetrating cardiac wounds: Principles for surgical management. World J Surg 2004;28:1025-1029.
8. Menaker J, Cushman J, Vermillion JM, Rosenthal RE, Scalea TM. Ultrasound diagnosed cardiac tampon after blunt abdominal trauma-treated with emergency thoracotomy. J Emerg Med 2007;32:99-103.
9. Chang WY, Hsu JY, Chang YP, Chao CS, Chang KJ. The successful management of a penetrating cardiac injury in a regional hospital: A Case Report. J Emerg Crit Care Med 2008;19:160-165.
10. Topcuoglu MS, Poyrazoglu HH, Yaliniz H. A unusual case of right lung and right atrio-inferocaval injury caused by stabbing. Thorac Cardiovasc Surg 2009;57:243-249.
11. Kang N, Hsee L, Rizoli S, Alison P. Penetrating cardiac injury: Overcoming the limits set by nature. Injury 2009;40:919-927.
12. Degiannis E, Loogna P, Doll D, Bonanno F, Bowley DM, Smith MD. Penetrating cardiac injuries: Recent experience in South Africa. World J Surg 2006;30:1258-1264.
13. Tokcan A, Kisacikoglu B, Salih OK, Ulus T, Tansal S, Oskay MK. Penetrating cardiac injuries: an analysis of 66 cases. J Islamic Academy Sci 1990;3:62-65.
14. Yillik L, Ergunes K, Yetkin U, Yasa H, Gurbuz A. Current evaluation of penetrating cardiac injuries. T Klin J Cardiovascular Surgery 2003;4:121-125.
15. Degiannis E, Bowley DM, Westaby S. Technical tutorial, notes and tips. Ann R Coll Surg Eng 2005;87:61-63.
16. Dauphine C, Mckay C, De Virgilio C, OMari B. Selective use of cardiopulmonary bypass in trauma patients. Am Surg 2005;71:46-50.
17. Narayan P, Caputo M, Roidl M, Casula R. The use of off pump surgery for management of penetrating coronary artery injury. Eur J Cardio-Thorac Surg 2002;21:361-362.
18. Vasquez JC, Baciewicz FA. Late onset angina after penetrating cardiac injury adjacent to a coronary artery. J Trauma 2006;60:1344-1346.
19. Demetriades D. Cardiac wounds. Ann Surg 1986;203:315-317.
20. Velmahos GC, Butt MU. Cardiac and pulmonary injury. Eur J Trauma Emerg Surg 2008;4:327-337.

Authors:

1. Hasan Ekim, MD,
2. Halil Basel, MD,
3. Dolunay Odabasi, MD,
4. Mustafa Tuncer, MD,
   Department of Cardiology,
   Yuzuncu Yil University,
   Van, Turkey
5. Hasan Ali Gumrukcuoglu, MD,
   Department of Cardiology,
   Van Yuksek Ihtisas Hastanesi,
   Van, Turkey

1-3: Department of Cardiovascular Surgery,
Yuzuncu Yil University,
Van, Turkey.