Original Article

THE DETECTION OF EAGLE'S SYNDROME WITH THREE-DIMENSIONAL MULTIDETECTOR COMPUTERIZED TOMOGRAPHY (CT)

Koksal Yuca[1], Serhat Avcu[2], A Faruk Kiroglu[3], Omer Etlik[4], Hakan Cankaya[5], Muzaffer Kiris[6]

ABSTRACT

Objective: Eagle's Syndrome is caused by elongation of the styloid process or ossification of the stylohyoid ligament. We aimed to evaluate the contribution of 3-Dimensional Multidetector CT findings on Eagle's syndrome.

***Methodology*:** Three-Dimensional Multidetector CT were performed on 13 patients with Eagle's syndrome. Maximum intensity projection (MIP) and volume rendering (VR) images having optimal resolution in all patients were obtained using 3D reconstructions on work-station. Styloid process and its extension, and stylohyoid ligament were evaluated. A styloid processes e"3cm were accepted to be longer than normal. We also had a control group of patients which consisted of ten patients who had no complaints of dysphagia, throat pain, or foreign body sensation in the throat.

Results: Elongation of the styloid process was revealed by 3D VR imaging in all patients. We found elongated styloid process bilaterally in two patients. Elongation of the styloid process was clearly revealed by 3D VR imaging in high contrast and spatial resolution under the anatomic orientation like conventional X-ray in all patients. The diagnosis of Eagle's syndrome was confirmed surgically in four of 13 patients.

Conclusion: We conclude that 3D VR imaging is a valuable diagnostic method in detecting elongated styloid process.

KEY WORDS: Computed tomography, Eagle's syndrome, styloid process, three-dimensional CT.

Pak J Med Sci July - September 2010 Vol. 26 No. 3 634-639

How to cite this article:

Yuca K, Avcu S, Kiroglu AF, Etlik O, Cankaya H, Kiris M. The detection of Eagle's Syndrome with Three-Dimensional Multidetector Computerized Tomography (CT). Pak J Med Sci 2010;26(3):634-639

Correspondence:

Koksal Yuca, MD,
Associate Professor in Otorhinolaryngology,
Department of Otorhinolaryngology,
Faculty of Medicine,
Yuzuncu Yil University,
65200-Van,
Turkey.
E-mail: koksalyuca@yahoo.com

* Received for Publication: November 11, 2009

* Accepted: April 8, 2010

INTRODUCTION

Eagle's syndrome is characterized by head and neck pain secondary to calcification of the stylohyoid ligament or elongated styloid process. Elongated styloid process gives a complex of symptoms described by Eagle in 1937, hence the condition is also known as Eagle's syndrome. It is a rare entity, which is not commonly suspected in clinical practice.[1-5]

Although approximately 4% of the population is thought to have an elongated styloid process,

only a small percentage (between 4% and 10.3%) of this group is thought to actually be symptomatic.[5,6] Diagnosis is made both radiographically and by physical examination.[6] Conventional X-ray is usually the first step of investigation of bone lesions (Figure 1). But it has some limitations in detection of some complex anatomic areas such as skull base. The combination of spiral computerised tomography(CT) and 3-Dimentional reconstruction with volume rendering(3D VR) allows rapid and detailed examination of the osseous structures. 3D VR images have been proved to be valuable in diagnosis of subtle abnormalities and in planning patient therapy.[5,6]

In this study, 3-Dimensional Multidetector CT was performed in 13 patients with Eagle's syndrome. We aimed to detect the contribution of 3D VR images on diagnosis of elongated styloid process.

METHODOLOGY

Between July 2004 and June 2006, 13 patients (7 females, and 6 males; mean age 36.53±12... years; range 20 to 62 years) with Eagle's syndrome were included in this study. We performed 3D CT in our Department of Otorhinolaryngology to all patients who were suspected to have elongated styloid process.

Symptoms were extremely variable among patients. The patients who presented with complaints of dysphagia and vague throat discomfort were evaluated by both ear nose throat(ENT) examination and imaging studies in order to investigate elongated styloid process.

3D Multidetector computed tomography (3D MDCT) (Siemens, Sensation 4, Erlangen, Germany) was used in radiological examinations. Styloid processes were examined with narrow collimation (0.5 mm), 0.5 mm slice thickness, and reconstruction every 0.5 mm. Creation of a 3D CT image began with the acquisition and reconstruction of axial image data. And then, axial images were sent to the work-station (Siemens, Leonardo, Erlangen, Germany). MIP and VR images were obtained using recontruction procedure on axial image. We obtained 3D images in optimal resolution and spatial resolution like conventional X-ray in all of the patients. Two radiologists independently assessed the axial and reformatted 3D VR images. 3D images were examined in the different point of views to get more detailed information. We investigated the extension of styloid process and its relations with surrounding tissue. Styloid processes $\geq$3cm were accepted to be longer than normal.

We also had a control group of patients which consisted of ten patients who underwent temporal CT examination and who had no complaints of dysphagia, throat pain, or foreign body sensation in the throat.

RESULTS

The most common complaints were dysphagia, foreign body sensation, and pharyngeal pain. On physical examination, pain suggesting elongated styloid process duplicated by palpation of the tonsillar fossa was seen in seven of the 13 patients. The remaining six patients had no abnormalities on physical examination, but these patients were evaluated by 3D VR imaging in order to display possible elongated process on the basis of clinical complaints suggesting Eagle's syndrome. We carried out the MDCT imaging and obtained 3D VR images in all patients. Elongation of the styloid process was revealed by 3D VR imaging in all patients (Fig. 2A, 2B, 3). We found elongated styloid process bilaterally in two patients. Extensions, relationships with the surrounding tissue, and the lengths of styloid process were evaluated clearly in high contrast and spatial resolution under the anatomic orientation like conventional X-ray. The diagnosis of Eagle's syndrome was confirmed surgically in four of 13 patients. The remaining nine patients did not accept a surgical intervention. Complete remission was achieved in patients who underwent surgical operation, whereas we observed partial remission in patients who were managed by medical treatment. The clinical findings, presenting complaints, and 3D VR findings of the patients are summarized in Table-I.

Table-I: Clinical characteristics of the patients.

Patient	*Sex*	*Age (years)*	*Presenting Symptoms*	*Side*	*History*	*Treatment*	*Results*
1	M	24	Dysphagia, foreign body sensation, otalgia	Right	Tonsillectomy 4 years previously	Medical (refused the operation; nonsteroidal anti-inflammatory medications)	Partial remission
2	F	32	Pain and right otalgia	Right		Surgical	Complete remission
3	F	20	Otalgia, pain	Bilateral		Medical	Partial remission
4	F	42	Dysphagia, foreign body sensation, right otalgia	Right	Tonsillectomy 5 years previously	Surgical treatment intraoral route	Complete remission
5	M	33	Left cervical pain with foreign body sensation	Bilateral		Medical	Partial remission
6	F	38	Dysphagia, otalgia	Bilateral		Medical	Partial remission
7	F	59	Foreign body sensation, pain on swallowing	Right		Medical	Partial remission
8	M	23	Dysphagia, foreign body sensation, pain	Left		Medical	Partial remission
9	F	62	Dysphagia, pain	Left		Medical	Partial remission
10	M	28	Pain, otalgia	Right		Surgical	Complete remission
11	F	34	Dysphagia, foreign body sensation, pain	Right		Medical	Partial remission
12	M	36	Foreign body sensation, pain	Left		Surgical treatment intraoral route	Complete remission
13	M	44	Otalgia	Right		Medical	Partial remission

In the control group who had no complaints of dysphagia, throat pain, or foreign body sensation in the throat, the mean length of styloid processes was 2.02cm, and none of them

Figure-1: Lateral skull film showing subtle elongated right styloid process. (Arrow A).

were longer than 3cm. Mean age was 30.8 years(19-55). There were no radiological features linked with symptomatic elongated styloid process. There were no radiological differences between symptomatic or non-symptomatic patients.

DISCUSSION

In adults, the normal length of the styloid process is approximately 2.5 cm, whereas an elongated styloid proceess is generally >3 cm in length.[7] Although Eagle's syndrome is thought to be caused by an elongated styloid process or calcified stylohyoid ligament, the presence of an elongated styloid process is not

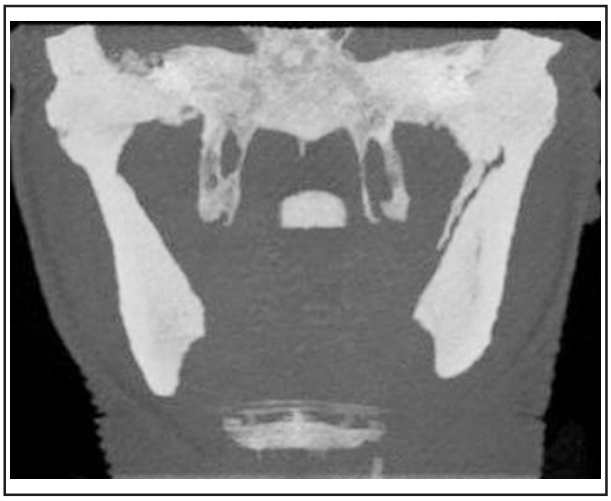

Figure-2B: Antero-posterior volume-rendered spiral CT images clearly showing the elongated left styloid process.

Figure-2A: Antero-posterior volume-rendered spiral CT images clearly showing the elongated right styloid process.

pathognomonic for Eagle's syndrome because many patients with incidental findings of an elongated styloid process are asymptomatic and can be accepted as normal anatomical variants.[2,5,6]

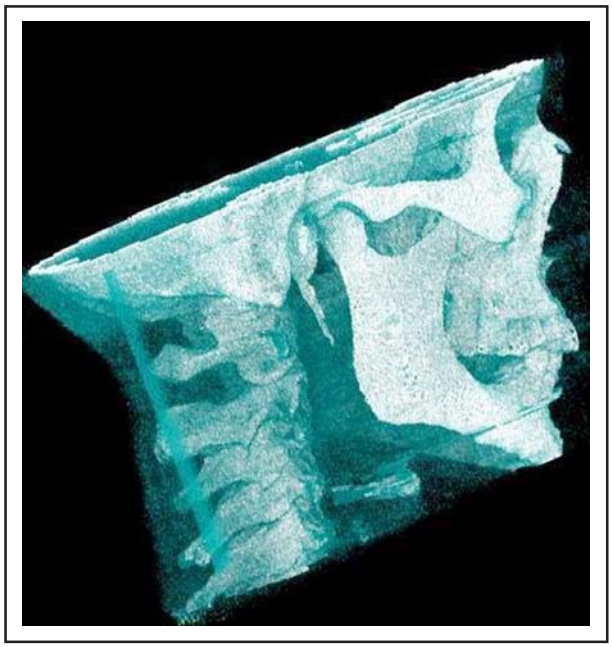

Figure-3: Oblique volume-rendered spiral CT image clearly showing the elongated right styloid process

Volume Rendering: Slice thickness 0.5 mm, Collimation 0.5, Recontruction 0.5, MAs 100, Kv 120, Scan time 98 sn, Rotation time 1 sn, Feed rotation 1mm.

The styloid process is derived from the second branchial bar of cartilage of Reichert. This cartilage consists of four highly variable parts; they are: (1) tympanohyale, (2) stylohyale, (3) ceratohyale, and (4) hypohyale. The actual cause of the elongation is a poorly understood process. Several theories have been proposed: 1) congenital elongation of the styloid process due to persistence of a cartilaginous analog of the stylohyale, 2) calcification of the stylohyoid ligament by an unknown process, and 3) growth of osseous tissue at the insertion of the stylohyoid ligament.[6,8]

The pathophysiological mechanism of symptoms is controvertial as well. Theories include the following: 1) traumatic fracture of the styloid process causing proliferation of granulation tissue, which places pressure on the surrounding structures; 2) compression of adjacent nerves, the glossopharyngeal, lower branch of the trigeminal, or chorda tympani; 3) degenerative and inflammatory changes in the tendonous portion of the stylohyoid insertion; 4) irritation of the pharyngeal mucosa by direct compression or post-tonsillectomy scarring (involves cranial nerves V, VII, IX, and X); and 5) impingement of the carotid vessels, producing irritation of the sympathetic nerves in the arterial sheath.[6,8]

Diagnosis can usually be made on physical examination by digital palpation of the styloid process in the tonsillar fossa, which exacerbates the pain. In addition, relief of symptoms with injection of an anesthetic solution into the tonsillar fossa (lidocaine infiltration test) is highly suggestive of this diagnosis.[2,8-10]

If there is a suspicion for Eagle' syndrome, confirmation can be made by radiographic studies.[6,11] Radiographic workup should include anterior-posterior, lateral skull films[8] and CT. Conventional X-ray should be performed as a first step of radiologic examination. But there are some limitations of this method such as overlapping of other structures and low contrast resolution.[7,12] Volume rendered MDCT can provide additional information and demonstrate styloid process clearly where plain radiograph is often limited in its ability to demonstrate styloid process. In the setting of imaging styloid process, conventional radiographic series are often difficult to show the styloid process because of poor quality[7,12] The combination of spiral CT and 3D reconstruction with VR allows rapid and detailed examination of the osseous structures. Subtle lesions or complex anatomic regions are better demonstrated on volume-rendered images. Disease extent can be thoroughly evaluated with 3D images, and therapeutic planning is aided by the anatomic information available from 3D images. In this syndrome, CT imaging which has some disadvantages such as lack of anatomic orientation has been used as the imaging modalitiy. However, volume-rendered images can resolve those disadvantages mentioned above having high contrast resolutions under the anatomic orientation.[7,12] Styloid process and its extensions were imaged clearly in all patients in our study.

Treatment of Eagle's syndrome is both surgical and nonsurgical.[3,6] Yetiser et al. did not recommend any surgical intervention in patients with only minor symptoms.[2] In surgical treatment intraoral and transcervical approaches have been used successfully. In patients who are not surgical candidates; include reassurance, nonsteroidal anti-inflammatory medications, and steroid injections (cortisone injection in the lower pole of the tonsillar fossa) may relieve the symptoms.[3,6,8] In our four cases surgical treatment was recommended but refused by patients.

Three-Dimensional MDCT with VR images is useful in visualizing the elongated styloid process itself as well as the relationship between the styloid process and neighboring tissue. We think that, 3D VR imaging is a valuable imaging method and should be carried out as a radiological examination.

REFERENCES

1. Piagkou M, Anagnostopoulou S, Kouladouros K, Piagkos G.Eagle's syndrome: A review of the literature. Clin Anat 2009;22(5):545-58.
2. Yetiser S, Gerek M, Ozkaptan Y. Elongated styloid process: diagnostic problems related to symptomatology Cranio 1997;15:236-241.

3. Baugh RF, Stocks RM. Eagle's syndrome: A re appraisal. Ear Nose Throat J 1993; 72:341-344.
4. Fini G, Gasparini G, Filippini F, Becelli R, Marcotullio D. The long styloid process syndrome or Eagle's syndrome. J Craniomaxillofac Surg 2000;28:123-127.
5. Takada Y, Ishikura R, Ando K, Morikawa T, Nakao N. Imaging findings of elongated styloid process syndrome (Eagle's syndrome): report of two cases Nippon Igaku Hoshasen Gakkai Zasshi 2003;63:56-58.
6. Murtagh RD, Caracciolo JT, Fernandez G. CT findings associated with Eagle syndrome. Am J Neuroradiol 2001;22:1401-1402.
7. Kuszyk BS, Ney DR, Fishman EK. The current state of the art in three-dimensional oncologic imaging: An overview. Int J Radiat Oncol Biol Phys 1995;33:1029-1039.
8. Balbuena L Jr, Hayes D, Ramirez SG, Johnson R. Eagle's syndrome. South Med J 1997;90:331-334.
9. Prasad KC, Kamath MP, Reddy KJ, Raju K, Agarwal S. Elongated styloid process (Eagle's syndrome): a clinical study. J Oral Maxillofac Surg 2002; 60:171-175.
10. Philipp K, Barnes EL, Carrau RL. Eagle syndrome produced by a granular cell tumor. Arch Otolaryngol Head Neck Surg 2001;127:1499-1501.
11. Rechtweg JS, Wax MK. Eagle's syndrome: a review. Am J Otolaryngol 1998;19:316-321.
12. Pretorius ES, Fishman EK. Helical (spiral) CT of the musculoskeletal system. Radiol Clin North Am 1995;33:949-979.

Authors:

1. Koksal Yuca, MD,
   Associate Professor in Otorhinolaryngology,
2. Serhat Avcu, MD,
   Assistant Professor in Radiology,
3. A Faruk Kiroglu, MD,
   Associate Professor in Otorhinolaryngology,
4. Omer Etlik, MD,
   Associate Professor in Radiology,
5. Hakan Cankaya, MD,
   Associate Professor in Otorhinolaryngology,
6. Muzaffer Kiris, MD,
   Professor in Otorhinolaryngology,

1-6. Department of Otorhinolaryngology,
Yuzuncu Yil University,
Faculty of Medicine,
Van, Turkey.