Case Report

SUBDURAL HEMATOMA – A COMPLICATION OF ELECTRO CONVULSIVE THERAPY

Neeraj Awasthy[1] & Karam Chand[2]

ABSTRACT:
Electro Convulsive Therapy (ECT) is commonly used in the management of the Bipolar disorder. Rare complication of this procedure, the intracranial bleed has scantily been reported in the English literature. We report a case of such a complication in a 63 years old man who was a known case of bipolar disorder for last 30 years and required ECT application for one month. Presenting symptoms consisted of increased agitation, headache vomiting and sudden deterioration of sensorium, with CT suggestive of left-sided frontoparietal chronic subdural hematoma. Drainage of the hematoma resulted in complete resolution of raised intracranial pressure symptoms.

KEYWORDS: Electro Convulsive Therapy, intracranial bleed, chronic subdural haematoma

Pak J Med Sci October-December 2005 Vol. 21 No. 4 491-493

INTRODUCTION

Electro Convulsive Therapy (ECT) is commonly used in the management of the Bipolar disorder [1]. In spite of the frequent usage of ECT only a few complications have been reported in the English literature[2]. This is particularly true of the intracranial bleed, which is scantily described and reported. We report such a case of chronic subdural hematoma in a 63 years old man resulting from ECT for bipolar disorder.

CASE REPORT

A 63 years old man who was a known case of bipolar disorder for last 32 years was observed to be increasingly agitated for last three months. Patient underwent Electro Convulsive Therapy (ECT) for the same. He had a total of 10 sessions of ECT with appropriately placed electrodes over a period of one month. Patient began to complain of headache and frequent vomiting with increasing frequency for last 2 weeks. The sensorium of the patient deteriorated over a period of three days before presentation. On examination patient was conscious but drowsy and would respond to verbal commands in incomprehensible manner. Glasgow coma scale of the patient was E3 V3 M6. Bilateral pupils were of normal size and reactive. Patient had normal power on both sides. There was no other neurological deficit. Non Contrast CT scan of the skull revealed large intracerebral hematoma in left frontoparietal region with shift of midline structures to right side (Fig1). Overlying bone window was normal. Patient underwent Burr hole operation in the left parietal region with evacuation of the hematoma. Following surgery condition of the patient showed significant improvement with complete resolution of the symptoms.

1. Dr. Neeraj Awasthy
2. Dr. Karam Chand

1-2: Department of Neurosurgery,
Vardhman Mahavir Medical College &
Safdar Jung Hospital,
Delhi-110029,
INDIA

Correspondence:
Dr. Karam Chand,
123, Anand Kunj, Vikas Puri,
New Delhi-110018, INDIA
Email: n_awasthy@yahoo.com

* Received for publication April 7, 2005
Accepted June 28, 2005

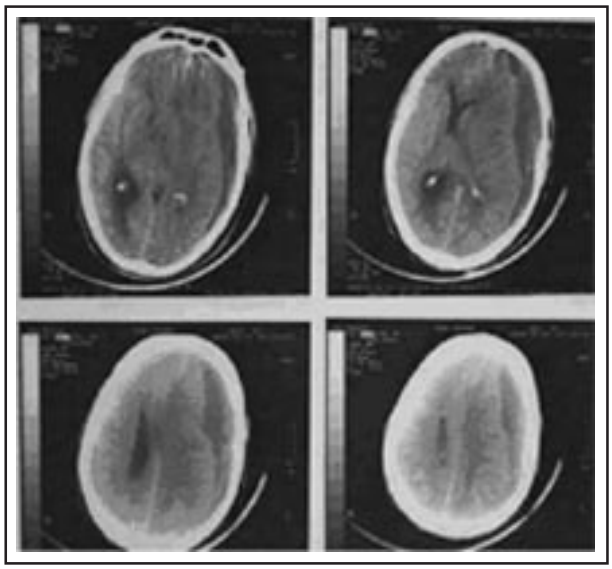

Figure-I: NCCT head showing large Intracerebral hematoma in left parietal region with midline shift

DISCUSSION

Electro Convulsive Therapy (ECT) is an accepted treatment modality for severe mental illness in which a brief application of electric stimulus is used to produce a generalized seizure. It is the most useful method for the agitated patient of bipolar disorder on chronic medication as was the case in our patient. A treatment regimen in which ECT is used for the acute episode, followed by lithium maintenance, does not appear to be associated with an increased risk of early relapse compared with lithium treatment alone[3-5]. Risks and adverse effects of ECT can be divided into two categories. Firstly, those medical complications that can be substantially reduced by the use of appropriately trained staff, best equipment and best methods of administration. Secondly those side effects, such as spotty but persistent memory loss and transient post treatment confusion that can be expected even when an optimal treatment approach is used. In the recent series reported, there were 2.9 deaths per 10,000 patients, another series reported, 4.5 deaths per 100,000 treatments.[1] Overall, the risk is not different from that associated with the use of short-acting barbiturate anesthetics. In one recent study of almost 25,000 treatments, a complication rate of 1 per 1,300 to 1,400 treatments was found.[1] These included laryngospasm, circulatory insufficiency, tooth damage, vertebral compression fractures, status epilepticus, peripheral nerve palsy, skin burns and prolonged apnea. There are two categories of central nervous system effects: The immediate consequences of the ECT seizure and the more enduring effects, both of which are affected by the treatment course. Immediately after awakening from the treatment, the patient experiences confusion, transient memory loss, and headache. The time it takes to recover clear consciousness may vary from minutes to several hours, depending on individual differences in response, the type of ECT administered, the spacing and number of treatments given as well as the age of the patient. Advanced medical technology has substantially reduced the complications associated with ECT. These include bradycardia, tachycardia, memory loss, and confusion. Persons at high risk for ECT include those with recent heart attack, uncontrolled blood pressure, brain tumors and previous spinal injuries[1,2]. A late complication is memory loss.

Intracranial parenchymal bleeds forms an important subgroup of extremely serious although rare complications that have been reported scantily following ECT. Nevertheless the true incidences of intracranial bleeds after ECT seems to be underestimated. Cases of neurological insults such as subdural bleed were not found to increase or deteriorate during an ECT, thus such procedure has been observed to be extremely safe in these patients [6,7]. It is particularity difficult to establish the iatrogenic cause of intracranial bleed. In patients with neurological abnormality after ECT, it may be more difficult than usual to diagnose an intracranial insult such as intracranial bleed. However any change in the mental state which is persistent, additional focal neurological signs or epileptic convulsions in patient with ECT should be treated with highest degree of suspicion and should be investigated with CT scan to rule out intracranial complication. CT scans are valuable in diagnosing and localizing insult as in our case. To minimize the frequency

of intracranial bleed, when using ECT it is essential that the physician should be aware of the potential risk. These complications should be actively looked for in the follow up of a case having undergone ECT therapy.

CONCLUSION

Application of ECT, although a safe procedure should not be considered trivial and detailed attention should be paid to its application. Any change in the mental state or additional focal neurological signs in patient with ECT should be investigated with CT scan or MRI brain to rule out complications like subdural hematoma.

REFERENCES

1. Electroconvulsive Therapy. NIH Consens Statement Online 1985 Jun 10-12 ; 5(11):1-23.
2. Nuttall GA, Bowersox MR, Douglass SB, McDonald J, Rasmussen LJ, Decker PA, et al. Morbidity and Mortality in the Use of Electro Convulsive Therapy. J ECT 2004; 20(4):237-41.
3. Royal Australian and New Zealand College of Psychiatrists Clinical Practice Guidelines Team for Bipolar Disorder. Australian and New Zealand clinical practice guidelines for the treatment of bipolar disorder. Aust NZ J Psychiatry 2004; 38(5):280-305.
4. Weller EB, Danielyan AK, Weller RA Somatic treatment of bipolar disorder in children and adolescents. Psychiatr Clin North Am 2004;27(1):155-78.
5. van der Wurff FB, Stek ML, Hoogendijk WJ, Beekman AT. The efficacy and safety of ECT in depressed older adults: a literature review. Int J Geriatr Psychiatry 2003; 18(10):894-904.
6. Malek-Ahmadi P, Beceiro JR, McNeil BW, Weddige RL. Electro Convulsive Therapy and Chronic Subdural Hematoma. Convuls Ther 1990; 6(1):38-41.
7. Wijeratne C, Shome S. Electroconvulsive therapy and subdural hemorrhage. J ECT 1999; 15(4):275-9.

Online edition of

Pakistan Journal of Medical Sciences

pjms.com.pk

is sponsered by

M/s PharmEvo (Pvt.) Ltd

Online edition include free access to all published manuscripts
(Abstract, full text and pdf format)