

HUGE UTERINE FIBROID COMPLICATING EARLY PREGNANCY: MYOMECTOMY AND LIVE BIRTH AT TERM

Aziken ME¹, Osemwenkha AP², Orhue AAE³,
Afinotan LU⁴, Osughe OM⁵, Irihogbe I⁶

ABSTRACT

Uterine fibroids are the commonest tumours of the female genital tract with a prevalence varying from 20-50% in women of reproductive age. Surgical management by myomectomy is limited to the non pregnant uterus. Fibroid coexisting with pregnancy may be associated with complication in 10-30% of cases which are preferably often managed conservatively.

We present a case of huge uterine fibroid in early pregnancy with significant complication that necessitated myomectomy at 10 weeks gestation in a 37 year old nullipara in which pregnancy continued till successful delivery at 38 weeks gestation.

KEY WORDS: Fibroids, Pregnancy, Myomectomy, Live birth.

Pak J Med Sci October - December 2008 (Part-I) Vol. 24 No. 5 753-756

How to cite this article:

Aziken ME, Osemwenkha AP, Orhue AAE, Afinotan LU, Osughe OM, Irihogbe I. Huge Uterine Fibroid Complicating Early Pregnancy: Myomectomy and Live Birth at Term. Pak J Med Sci 2008;24(5):753-56.

INTRODUCTION

Uterine fibroids are the commonest tumours of the female genital tract, with a reported prevalence during pregnancy of about 2%.¹⁻⁴ Surgical management of uterine fibroid by myomectomy is often limited to the non pregnant uterus because of the risk of severe

haemorrhage and miscarriage if performed on a pregnant uterus. However, in the last three decades, there have been increasing reports of successful myomectomy during caesarean section.⁵⁻⁷ While this controversy is yet to be resolved, several reports of successful emergency and elective myomectomy during pregnancy have emerged.⁸⁻¹⁰

A search through the literature revealed two cases of successful emergency myomectomy during pregnancy reported from eastern Nigeria.^{9,10} We are not aware of any reported case of elective myomectomy from Nigeria hence this case report.

CASE PRESENTATION

History, Physical examination and Management: Mrs. OG was a booked 37 year old gravida two Para 0⁺¹ civil servant with tertiary level of education whose last menstrual period was on February 24th 2007 and her estimated date of delivery was December 3, 2007. She was first

1. Aziken ME,
 2. Osemwenkha AP,
 3. Orhue AAE,
 4. Afinotan LU,
 5. Osughe OM,
 6. Irihogbe I,
- 1-6: Department of Obstetrics and Gynaecology,
University of Benin Teaching Hospital,
Benin City,
Nigeria.

Correspondence

Aziken ME,
E-mail: michaelaziken@yahoo.com
michaelaziken@hotmail.com

* Received for Publication: May 8, 2008

* Accepted: July 23, 2008

seen on April 25th, 2007 at the Gynaecology Clinic at eight weeks gestation with complaints of progressive abdominal swelling for six years and epigastric pain for one month prior to presentation. The abdominal swelling was noticed six years earlier and it had increased progressively in size. There was associated urinary frequency but no dysuria. There was no history of menorrhagia, weight loss, change in the menstrual pattern or change in bowel habit. Her pregnancy was confirmed by an earlier ultrasound scan that also noted the presence of multiple uterine fibroids. With onset of pregnancy she developed dull epigastric pain a month prior to presentation. The pain was distressing, worse on lying down and radiated to the back with associated lower back pain. The pain also disturbed her sleep.

She was seen four years earlier by a gynaecologist at central Hospital Benin City where an abdominopelvic ultrasound scan done then confirmed uterine fibroids. She was counseled on possible surgical intervention should it become indicated. With worsening of symptoms in pregnancy she presented at the University of Benin Teaching Hospital for care. At presentation she was not pale and her cardiovascular and respiratory systems were essentially normal. She had a firm abdominopelvic mass of about 36 weeks gestation.

An impression of intrauterine gestation coexisting with a huge uterine fibroid was

made. Abdominopelvic ultrasound scan, showed a bulky uterus with an intrauterine gestational sac containing a viable foetal node at seven weeks gestation with a coexisting huge uterine fibroid mass with multiple areas of cystic and calcific degeneration.

She was admitted into the ward and managed conservatively with analgesic for one week with no improvement in her symptoms. She was then counseled for myomectomy on account of the distressing abdominal and back pain associated with the huge uterine fibroids. The risk of possible spontaneous abortion following the procedure was explained to her. She consented and was worked up for surgery. Preoperative packed cell volume was 31%. Electrolyte and Urea was normal and two units of blood was group and cross matched for her.

She had myomectomy on the May 2nd 2007 under general anaesthesia. The findings at surgery were: a huge intramural and subserous fundal fibroid weighing 3.4kg (see Fig 1 & 2) and a smaller one 2×4cm in the anterior uterine wall. The right ovary was normal while the left ovary was enlarged with an intact corpus luteum. The fibroids were enucleated via a midline fundal incision with an anterior and posterior extension. Following enucleation, the resulting cavity was obliterated by carefully approximating the myometrium (using vicryl two on round bodied curve needles), in three layers over the wall of the gestational sac. The uterine serosa was repaired by imbrication with vicryl 1 on a round body needle. The blood loss was 500mls.

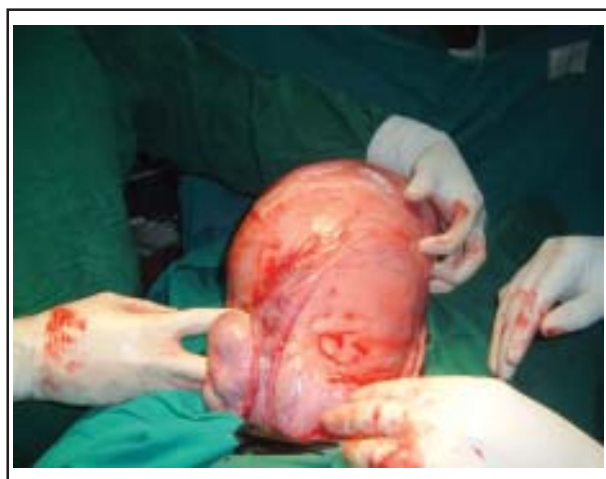

Figure-1: Huge fibroid removed at surgery 3.4kg

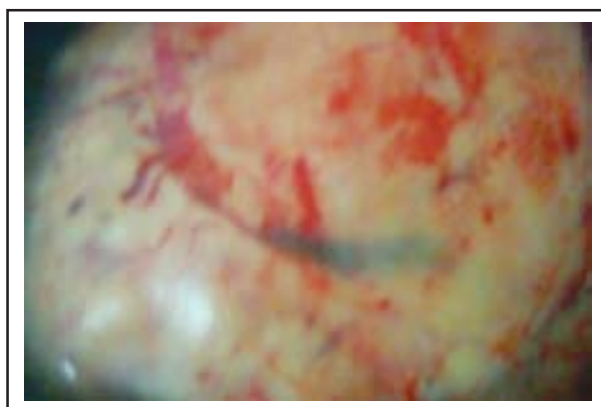


Figure-2: Exteriorised fibroid uterus

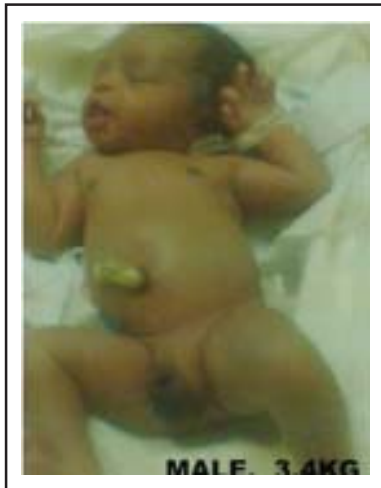

Figure-3: Male infant birth wt=3.4kg

Postoperatively she had intravenous Co-amoxiclav 1.2gm eight hourly for 24 hour and was thereafter continued tablet for five days. She also had pentazocine for pain relief and intravenous salbutamol infusion; 500mcg in 500mls of Normal saline given over six hours for 48 hours post operatively to relax the uterus. In addition, she was given intramuscular Hydroxyprogesterone Caproate (Proluton Depot[®]; Schering Health) 500mg stat and 250mg twice weekly for four weeks post operatively. She had an uneventful post operative period and was discharged home on the 14th post operative day after she was registered for antenatal care. Her antenatal period was largely uneventful with a total of thirteen visits. Obstetric ultrasound scan was done twice subsequently at 20weeks and 36 weeks and both were normal.

She was counseled for elective caesarean section at term which was done at 38 weeks gestation. She delivered a live male 3.4kg neonate with good Apgar scores (see Fig-3). Her post operative condition was satisfactory. Mother and baby were discharged on the fifth postoperative day to the postnatal clinic six weeks later.

DISCUSSION

In majority of pregnancies with coexisting fibroids, there may be no complications. However in about 10-30% of cases complications

involving the pregnancy alone or the fibroid or both as well as adjacent organs have been reported.^{3,4,8,11-14} These complications include spontaneous abortions, premature rupture of membranes, preterm labour/birth, oligohydramnios, fetal postural deformities, dysfunctional labour, primary postpartum haemorrhage, and retained placenta, red degeneration of myomas, ruptured degenerated myomas, torsioned pedunculated myomas and pressure effect on adjacent organs.^{3,4,8,11-14}

The management of uterine fibroid during pregnancy is medical, but in rare circumstances surgical intervention and myomectomy may be required.⁸

Mrs. OG was ten weeks pregnant and the fibroids had enlarged the uterine size to 36 weeks associated with significant symptoms from the pressure effect and pain from possible degenerative changes. This size of fibroid was considered massive for pregnancy at this gestational age and subsequent course of the pregnancy was cause for concern. The ultrasound finding of multiple intramural and sessile fibroids completely sparing the uterine endometrium increased the likelihood that myomectomy could be safely performed during pregnancy as a viable treatment option. Some workers have reported similar findings of myomas sparing the endometrium on ultrasound scan among other criteria for selecting patients for myomectomy during pregnancy and had over 92% success.⁸

The two major complications of myomectomy in pregnancy are abortion and severe bleeding and these have direct fetomaternal consequences. The role of counseling and informed consent before myomectomy in pregnancy therefore cannot be overemphasized. Myomectomy on a non-pregnant uterus involves the use of tourniquet, clamps or oxytocic to reduce blood supply to uterus and thus reduce blood loss during surgery. None of these could be done in this case because of the developing fetus in-utero. Appropriate surgical skills and speed were thus major consideration to limit blood loss as massive blood

loss has been reported as inevitable complications of myomectomy in pregnancy.^{5,11,16,17} Mrs. OG had a successful myomectomy and the blood loss was less than 500mls. The early gestational age of this pregnancy and therefore less uterine vascularisation at this stage and the hypercoagulability in pregnancy may have contributed to the haemostasis achieved in this case.

The uterus was handled minimally during surgery and post operatively she was given intravenous tocolytic to forestall premature contraction and prevent miscarriage. The uterus remained quiescent throughout the post operative period. She had an uneventful antenatal period and was delivered by elective caesarean section at 38 weeks gestation. She was delivered by lower segment caesarean section to prevent uterine rupture in labour as the endometrium though not breached at the myomectomy but the incision was at the fundal aspect of the upper segment of the uterus in an on-going pregnancy. This case demonstrates the growing trend of successful elective myomectomy in pregnancy in well selected cases.

REFERENCES

1. Muram D, Gillieson M, Walters JH. Myomas of the uterus in pregnancy: ultrasonographic follow-up. *Am J Obstet Gynecol* 1980;138:16-9.
2. Vergani P, Chidrini A, Strobelt N, Roncaglia N, Locatelli A, Lapinski RH, et al. Do uterine leiomyomas influence pregnancy outcome? *Am J Perinatol* 1994;11:356-8.
3. Ice JP, Kay HH, Mahony BS. The clinical significance of uterine leiomyomas in pregnancy. *Am J Obstet Gynecol* 1989;160:1212-6.
4. Katz VL, Dotters DJ, Droegemueller W. Complications of uterine leiomyomas in pregnancy. *Obstet Gynecol* 1989;73:593-6.
5. Ehigiegba AE, Evbuomwan CE. Inevitable caesarean myomectomy. *Trop J Obstet Gynecol* 1998;15:62.
6. Ehigiegba AE, Ande AB, Ojobo SI. Myomectomy during cesarean section. *Int J Gynecol Obstet* 2001;75:21-5.
7. Kwawukume EY. Myomectomy during cesarean section. *Int J Gynecol Obstet* 2002;76:183-4.
8. Lolis DF, Kalantaridou SN, Makrydias G, Sotiriadis A, Navrozoglu I, Zikopoulos K, et al. Successful myomectomy during pregnancy. *Human Reproduction* 2003;18:1699-1702.
9. Nwagha UI, Agu KA, Nwankwo TO, Egbuji CC. Emergency myomectomy during pregnancy: a case report. *Trop J Obstet Gynecol* 2005;22(1):79-80.
10. Umezurike C, Feyi-Waboso. Successful myomectomy during pregnancy: A case report. *Reproductive Health* 2005;2:6.
11. Brown D, Fletcher HM, Myrie MO, Reid M. Cesarean myomectomy- a safe procedure. A retrospective case controlled study. *Obstet Gynecol* 1999;19:139-41.
12. Ikedife D. Surgical challenge of myomectomy at cesarean section. *Niger J Surg Sci* 1993;3:15-7.
13. Coronado GD, Marshall LM, Schwartz SM. Complications Pregnancy, Labour and Delivery with Uterine Leiomyomas: A population-Based Study. *Obstet Gynecol* 2000;5:764-9.
14. Exacoustos C, Rosati P. Ultrasound diagnosis of uterine myomas and complications in pregnancy. *Obstet Gynecol* 1993;82:97-101.
15. Ezechi OC, Kalu BKE, Okeke PE, Nwokoro CO. Inevitable cesarean myomectomy: A case report. *Trop J Obstet Gynecol* 2003;20:159-60.
16. Depp R. Cesarean delivery. In: *Obstetrics: normal and problem pregnancies 4th edition*. Edited by: Gabbe SG, Niebyl JR, Simpson JL. New York: Churchill Livingstone; 2002;599.
17. Cunningham FG, Gant FN, Levenok KJ, Gilstrap LC, Hauth JC, Wenstrom, KD. editors. Chapter 35: Abnormalities of the reproductive tract; *Williams Obstetrics*. 21st edition. New York: McGraw Hill; 2000;930.