

An experience with Retrosternal Goiter: Analysis of 89 cases

Ishtiaq Ahmed¹, Umar Farooq², Zia Ud Din Afridi³, Abida Maryum⁴

ABSTRACT

Objective: To determine the frequency of retrosternal goiter, clinical presentation and post operative complications among the patients presenting with goiter.

Methodology: It is a prospective, crosssectional study conducted at Department of Surgery, Fauji Foundation Hospital, Rawalpindi from January 1997 to December 2008. All patients with goiter were evaluated for retrosternal extension of thyroid, clinical presentation, and post operative complications.

Results: Among 978 patients, 89 (9.10%) patients had retrosternal extension of thyroid. Majority of the patients were female (94.51%) and euthyroid (91.02%). Among all the patients, (39.33%) were in the 5th decade. Retrosternal extension of both lobes was found in 83.15% and one lobe in 16.15% patients. Dyspnea was the commonest complaint by all patients, followed by headache (30.33%) and dysphagia (25.84%). Recurrent laryngeal nerve palsy was seen in 4.49% patients and 3.37% patients developed hypocalcaemia and wound infection after surgery.

Conclusion: Retrosternal extension of thyroid is not uncommon. Surgery can be easily done through cervical approach.

KEY WORDS: Goiter, Retrosternal extension, Clinical presentation, Complications.

Pak J Med Sci October - December 2010 Vol. 26 No. 4 897-900

How to cite this article:

Ahmed I, Farooq U, Afridi Z, Maryum A. An experience with Retrosternal Goiter: Analysis of 89 cases. Pak J Med Sci 2010;26(4):897-900

INTRODUCTION

Ectopic thyroid tissue can be found in unusual circumstances contained in central compartment of neck, posterior part of tongue, under lower pole of normal thyroid and occasionally in anterior mediastinum.¹ Retrosternal goiter is an unusual presen-

tation of an intrathoracic extension of an enlarged thyroid, usually as a result of multinodular goiter. Literature review shows that the definition of retrosternal goiter varies. Goldenburg² in 1957 defined a retrosternal goiter when it reaches the level of 4th thoracic vertebra, Singh (1994)³ defined it when more than 50% of thyroid tissue below the thoracic inlet and White (2008)⁴ labelled when it requires mediastinal dissection. But the generally accepted criteria is by Candela⁵ which defined that when thyroid extend more than 2 cm below the thoracic inlet. Both cervical and retrosternal portions generally maintain their blood supply directly from thyroid arteries. Pure intrathoracic goiters do occur without extension from cervical thyroid. Ectopic thyroid gland in the mediastinum may also be associated with normal sized cervical gland in less than 1% of cases. In 75-90% of cases gland is located in the anterosuperior compartment and in 25% cases found in the middle (visceral) compartment. Gland in visceral compartment often displaces the carotid

1. Dr. Ishtiaq Ahmed, FCPS,
2. Dr. Umar Farooq, FCPS,
3. Dr. Zia Ud Din Afridi, FCPS,
4. Dr. Abida Maryum, MBBS,
- 1-2: Department of Surgery, Islamabad Medical & Dental College Punjab Employees Social Security Hospital, Islamabad.
- 3-4: Department of Surgery, Foundation University Medical College, Rawalpindi.

Correspondence:

Dr. Umar Farooq,
Consultant Surgeon,
House No. 576 Street 40, Phase II,
Bahria Town, Rawalpindi - Pakistan.
E-mail: umaribd@yahoo.com

- * Received for Publication: May 15, 2010
- * Revision Received: July 8, 2010
- * Second Revision Received: July 22, 2010
- * Final Revision Accepted: July 23, 2010

vessels and recurrent laryngeal nerve. Ectopic thyroid tissue always had anomalous blood supply from loco-regional blood vessels.⁶

Clinical presentation varies from asymptomatic to pressure symptoms or toxic symptoms. Surgical removal of thyroid is the treatment of choice and majority of patients have symptomatic improvement following the operation. Retrosternal goiters can be removed through standard cervical incision in majority of cases except in patients who had previous cervical or mediastinal surgery.^{7,8} The purpose of this study was to determine the frequency of retrosternal goiter, clinical presentation and post operative complications among the patients presenting with goiter.

METHODOLOGY

This crosssectional study was carried out in the Surgical Department of Fauji Foundation Hospital Rawalpindi from January 1997 to December 2008. Fauji Foundation Hospital, Rawalpindi is a 660 bed, tertiary care hospital, which provides free health care to the ex-servicemen, their families and private patients. All patients reporting for treatment are registered through central computerized registry and allotted a computer ID. Complete computerized record of all patients is maintained and available on line. Most of the patient belongs to the areas of Rawalpindi Division, Hazara Division, Central Punjab, Azad Kashmir and Khyberpukhtoonkha. Approval for the study was taken from the Institutional review board. Informed consent was taken from every patient included in the study.

All patients of goiter were evaluated and patients having retrosternal extension of thyroid were included in the study. To assess retrosternal extension, we followed the criteria used by Candela.⁵ According to this criteria, any thyroid enlargement of more than 2 cm identified below the thoracic inlet during operation, when the patient neck is held in extension is termed as retrosternal goiter were included in the study. Those patients who had retrosternal extension (less than 2 cm) of thyroid tissue below thoracic inlet confirmed during surgery or having no retrosternal extension were excluded. Patients

Table- I: Age and Sex distribution of Retrosternal Goiter in different age groups.

	Females	Males	Total	Percentage among group
21 – 30 YRS	7	—	7	07.86%
31 – 40 YRS	18	3	21	23.59%
41 – 50 YRS	32	3	35	39.33%
51 – 60 YRS	20	—	20	22.48%
61 – 70 YRS	6	—	6	06.74%
> 70 YRS	—	—	—	—
Total	83	6	89	
% among total	8.49%	0.61%	9.10%	
% among group	94.59%	5.41%		

Total patients operated = 978

Patients with Retrosternal goiter extension = 89

Statistical Analysis: 95% CI for Female = 85.3% to 97.2%

were admitted and thorough clinical, biochemical and histopathological evaluation done. Extent of thyroid extension was evaluated in suspected cases by investigations i.e. X-ray chest, X-ray thoracic inlet or CT scan and then confirmed during surgery. Patients were prepared for operation and all necessary routine investigations for thyroidectomy were carried out. Thyroidectomy was done through cervical approach in all patients. The results were evaluated and statistical analysis was done by using EPI 6 software.

RESULTS

A total number of 978 patients reported with multinodular goiter in surgical out patient department during study period from January 1997 to December 2008. Among the 978 patients, 89 (9.10%) patient were diagnosed as having retrosternal extension of goiter (Fig-1). None of the patient was having mediastinal thyroid or ectopic thyroid in retrosternal position. Majority of patients among them were females and from 4th and 5th decade of life (Table-I) i.e. 23.59% and 39.33% respectively.

Majority (91.02%) among them were euthyroid and 6.74% were found to be hyperthyroid (Table-II) This table also shows the extent of extension or involvement of lobe in retrosternal extension of thyroid. 83.15% of patients had retrosternal extension of both

Table-II: Hormone Status of Retrosternal Goiter N= 89

Type of Goiter	No of patients	Hormone Status		
		Euthyroid	Hyperthyroid	Hypothyroid
Retrosternal extension one lobe	15(16.85%)	15	—	—
Retrosternal extension both lobe	74(83.15%)	66	6	2
Total	89	81 (91.02%)	6(6.74%)	2(2.24%)
95% Confidence limits		82.5 to 95.7	2.77 to 14.6	0.4 to 8.6

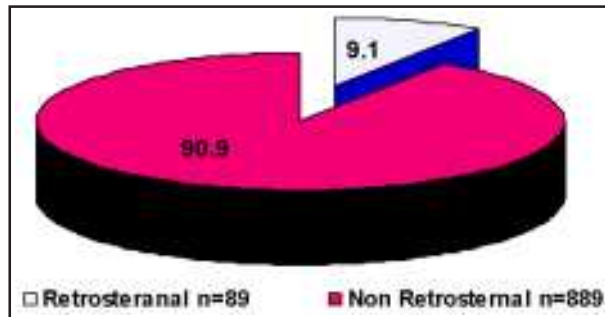


Figure-1: Proportionate morbidity of Retrosternal goiter.
 Statistical Analysis: 95% Confidence limits
 for Retrosternal Goiter = 10.11% to 15.0%.

lobes and 66 out of 74 patients were euthyroid. Only 16.85% were having retrosternal extension of one lobe and all of them were euthyroid. Dyspnoea was complained by all patients having retrosternal extension of goiter. The other commonest complaints observed were head ache (30.33%), dysphagia (25.84%) and voice changes in 22.47% patients (Table-III). Post-operatively recurrent laryngeal nerve palsy was the main complication observed in 4.49% of patients, hypocalcaemia and wound infection each was observed in 3.37% of patients (Table-IV). All surgeries were successfully done through cervical approach, none of the patient required median sternotomy in our patients. No operative or post operative mortality were recorded in our patients.

DISCUSSION

Retrosternal goiter is defined as any thyroid enlargement identified 2cm below the thoracic inlet at operation, when the patient neck is held in extension.⁵ It is an unusual presentation as an intrathoracic extension of an enlarged multinodular goiter. Most intrathoracic or retrosternal goiters or extensions of multinodular goiters, based on inferior thyroid vasculature. They expand downwards to anterior mediastinum. Less than 1% of retrosternal goiter which arises as aberrant thyroid tissue within the mediastinum and is based on intrathoracic vascula-

Table-III: Clinical Presentation of Retrosternal Goiter N=89

Clinical presentations	No of patients	Percentage
Dyspnoea	89	100%
Headache	27	30.33%
Dysphagia	23	25.84%
Hoarseness	20	22.47%
Cough	19	21.34%
Superior vena cava obst	18	20.22%
Palpitation	18	20.22%
Toxic symptoms	5	5.61%

Note: denominator for all symptoms is 89 for each row.

ture and not supplied by the inferior thyroid artery.⁶ Retrosternal goiter is a frequently symptomatic condition, with a low but definite risk of malignancy. Choking and dyspnoea are most common presenting symptoms of retrosternal goiter.⁹⁻¹¹ In our study almost all patients complained of dyspnoea or choking sensations. Headache, dysphagia and hoarseness of voice were reported by one third of the patients. Same observations were made in different studies^{8,9,12} from different parts of world but incidence is less as compared to our study. This is probably due to the fact that almost all patients in our study had large sized goiter.

Diagnosis can be confirmed by radiological examination of chest, CT scan of neck-chest, MRI of mediastinum, Thyroid ecotomography and by thyroid scintigraphy. Among them CT scan and MRI are important components of the preoperative evaluation and operative planning especially when retrosternal goiter is suspected.^{12,13} Thyroid scan may be done to exclude other diagnosis such as lymphoma which shows functioning thyroid.^{14,15} In retrosternal goiter it is necessary to define its exact relationship to neck and mediastinal structures in order to establish the most appropriate surgical approach. Retrosternal goiters are more likely to be left sided.¹⁰ Majority of our (83.15%) patients were having bilateral retrosternal goiter and euthyroid (91.02%).

Due to progressive enlargement of retrosternal goiter leading to increased morbidity, removal of thyroid tissue is always indicated and should be performed as soon as possible unless there are contraindications for surgery. In endemic goiter areas, incidence of retrosternal extension of goiter varies from 3 to 20% with respect to thyroidectomy patients. Most of the patients with retrosternal goiter were over the age of 50 years and women were affected approximately three times more often than men.^{6,9,16} Hedayati reported quite high incidence (30%) of retrosternal goiter.¹⁷ We observed 9.10% of our patients with retrosternal extension of goiter. In our study male to females ratio was quite high (1:17) and patients were relatively in younger age group (30-50 years of age).

Table-IV: Complications After Surgery N=89

Complications	No of patients	Percentage
RLN Injury	4	4.49%
Hypocalcemia	3	3.37%
Wound Infection	3	3.37%
Haematoma	2	2.24%
Post Operative Bleeding	1	1.12%

Thyroidectomy should be recommended as the treatment of choice. Surgery is usually possible through a cervical incision and with an acceptable risk of morbidity.^{17,18} In majority of cases their blood supply is usually based on inferior thyroid artery, allowing even larger retrosternal masses to be mobilized gently into the neck. When dissection of the retrosternal goiter is difficult and recurrent laryngeal nerve is not clearly identified, partial sternotomy may be required to enable a better control of nerve and vessel. Median sternotomy or thoracotomy is rarely required in retrosternal goiter extension surgery.^{6,16} In our study none of the patient required median sternotomy or thoracotomy and all thyroidectomies were done through cervical incision successfully, whereas Calo from Italy¹⁶ reported 3.28% sternotomy and 0.93% thoracotomy in his study. Similarly Ben¹² from Israel reported 9% rate of sternotomy, 8.3% by Chow¹⁹ from Hong Kong, and 4% by Arici²⁰ from Turkey.

Complications of surgery include intrathoracic bleeding, recurrence in unresected tissues, and recurrent laryngeal nerve damage. Complication rate reported in international literature is less than 5% in experienced hands.^{11,13,19,20} Calo¹⁶ and Chow¹⁹ reported incidence of recurrent laryngeal nerve injury in 2.2% and 2.7%, hypocalcaemia in 4% and 13.3%, haematoma formation in 1.8% and 2.7% of patients respectively. Almost same incidences of complications were also reported in other studies.^{12,21} We observed recurrent laryngeal nerve injury (4.49%), hypocalcaemia (3.37%), wound infection (3.37%) and haematoma formation (2.24%) among our patients, which is almost same as reported in international literature.

CONCLUSION

Retrosternal goiter is not an uncommon condition especially in areas where goiter is prevalent. It can be easily done through cervical approach but as retrosternal thyroidectomy may be technically difficult from cervical thyroidectomy so a surgical team familiar with its unique pitfalls should perform this procedure to get a better outcome of surgery.

REFERENCES

1. Olk J. Applied anatomy of the chest wall and mediastinum. In Baker RJ, Fischer JE (Editors) *Mastery of surgery* 4th edition Lippincott Williams and Wilkins, Philadelphia. 2001;633-634.
2. Goldenberg IS, Lindskog GE. Differential diagnosis, pathology, and treatment of substernal goiter. *JAMA* 1957;163:527-529.
3. Singh B, Lucente FE, Shaha AR. Substernal goiter: A clinical review. *Am J Otolaryngol* 1994;15(6):409-416.

4. White ML, Doherty GM, Gauger PG. Evidence-Based Surgical Management of Substernal Goiter. *World J Surg* 2008;32:1285-1300.
5. Candela G, Varriale S, Di Libero L, Manetta F, Giordano M, Maschio A, et al. Surgical therapy of goiter plunged in the mediastinum. Considerations regarding our experience with 165 patients. *Chir Ital* 2007;59(6):843-51.
6. Batori M, Chatelou E, Straniero A. Endocrinology Eur Rev Med Pharmacol Sci 2007;11(4):265-268.
7. Ríos A, Rodríguez JM, Balsalobre MD, Tebar FJ, Parrilla P. The value of various definitions of intrathoracic goiter for predicting intra-operative and postoperative complications. *Surgery* 2010;147(2):233-238.
8. Erbil Y, Bozboru A, Barbaros U, Ozarmagan S, Azezli A, Molvalilar S. Surgical management of Substernal goiter: Clinical experience of 170 patients. *Surg Today* 2004;34(9):732-736.
9. Moron JC, Singer JA, Sardi A. Retrosternal goiter: A six year institutional review. *Am Surg* 1998;64(9):889-893.
10. Chauhan A, Serpell JW. Thyroidectomy is safe and effective for Retrosternal goiter. *ANZ J Surg* 2006;76(4):238-242.
11. Hanks JB. Thyroid. Townsend CM, Beauchamp RD, Evers BM, Mattox KL (Editors) In *Sabiston Text Book of Surgery* 17th edition, Saunders, Philadelphia 2004;961-962.
12. Ben Nun A, Soudack M, Best LA. Retrosternal thyroid goiter: 15 year experience. *Isr Med Assoc J* 2006;8(2):106-109.
13. Makeieff M, Marlier F, Khudjadze M, Garrel R, Crampette L, Guerrier B. Substernal goiter: Report of 212 cases. *Ann Chir* 2000;125(1):18-25.
14. Mc Dougall R. In vivo radionuclide tests and imaging. In Breverman LE, Utiger RD (editors) *The thyroid, A fundamental and clinical text* 9th edition. Lippincott Williams & Wilkins, London. 2004:318.
15. Gerard SK, Cavalieri RR. I¹²⁵ diagnostic thyroid tumor whole body scanning with imaging at 6, 24 and 48 hours. *Clin Nucl Med* 2002;27:1-8.
16. Calo PG, Tatti A, Farris S, Piga G, Mallocci A, Nicolosi A. Substernal goiter: Personal experience. *Ann Ital Chir* 2005;76(4):331-335.
17. Hedayati N, McHenry CR. The clinical presentation and operative management of nodular and diffuse Substernal thyroid disease. *Am Surg* 2002;68(3):245-251.
18. Rodriguez JM, Hernandez Q, Pinero A, Oritz S, Soria T, Ramirez P, et al. Substernal goiter: Clinical experience of 72 cases. *Ann Otol Rhinol Laryngol* 1999;108(5):501-504.
19. Chow TL, Chan TT, Suen DT, Chu DW, Lam SH. Surgical management of Substernal goiter: Local experience. *Hong Kong Med J* 2005;11(5):360-365.
20. Arici C, Dertsiz L, Altunbas H, Demircan A, Emek K. Operative management of Substernal goiter: Analysis of 52 patients. *Int Surg* 2001;86(4):220-224.
21. Chaudhary IA, Samiullah, Masood R, Mallhi AA. Complications of thyroid surgery: A five year experience at Fauji Foundation Hospital, Rawalpindi. *Pak J Surg* 2006;22(3):134-137.

Authors Contribution:

Ishtiaq Ahmed conceived, designed and gave final approval of manuscript.
Umar Farooq did statistical analysis, review and editing of manuscript.
Zia Ud Din Afridi, Abida Maryum did data collection and manuscript writing.